

Peritonitis and intra-abdominal infection

Catedra de Chirurgie nr.1 „Nicolae Anestiadi”

Peritonitis is defined as inflammation of the serosal membrane that lines the abdominal cavity and the organs contained therein.

Peritonitis and intra-abdominal infection (IAI) are not synonymous. The former can mean sterile inflammation of the peritoneum, as the chemical peritonitis seen following an early perforation of a peptic ulcer or acute pancreatitis.

The latter (IAI) implies inflammation of the peritoneum caused by microorganisms. Bacteria, however, cause the vast majority of clinically significant peritonitis.

Both terms are used interchangeably.

The inflammatory process may be localized (abscess) or diffuse in nature.

Peritonitis is most often caused by introduction of an infection into the otherwise sterile peritoneal environment through organ perforation, but it may also result from other irritants, such as foreign bodies, bile from a perforated gall bladder or a lacerated liver, or gastric acid from a perforated ulcer.

Women can also experience localized peritonitis from an infected fallopian tube or a ruptured ovarian cyst.

Patients may present with an acute or insidious onset of symptoms, limited and mild disease, or systemic and severe disease with septic shock.

Anatomy and physiology

The peritoneum is the largest and most complex serous membrane in the body.

The peritoneum consists of an anterior and posterior peritoneal layers, described collectively as the **parietal** peritoneum.

The **visceral** peritoneum represents the mesothelial lining cells that are reflected onto the surface of the viscera.

The visceral peritoneal lining of the liver and spleen is thicker and can be detached from the underlying organ parenchyma, whereas the visceral lining of the bowel is thin and intimately attached to the tunica muscularis.

TOTAL SURFACE - 1,7-2 M²

Anatomy and physiology

Region 1 - Right Hypochondriac

Region 2 – Epigastric

Region 3 - Left Hypochondriac

Region 4 - Right Lumbar

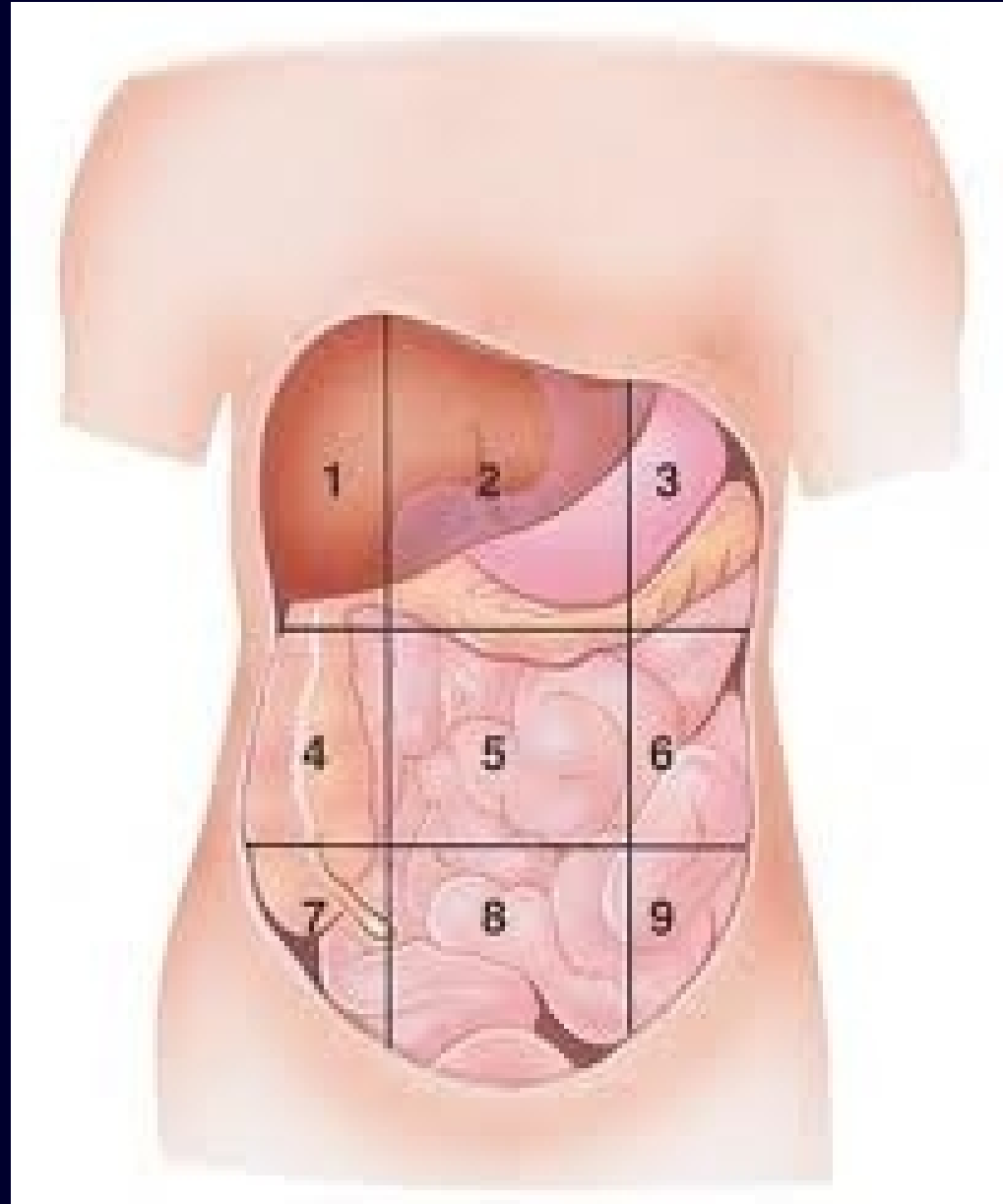
Region 5 – Umbilical

Region 6 - Left Lumbar

Region 7 - Right Iliac (Inguinal)

Region 8 - Hypogastric (Pubic)

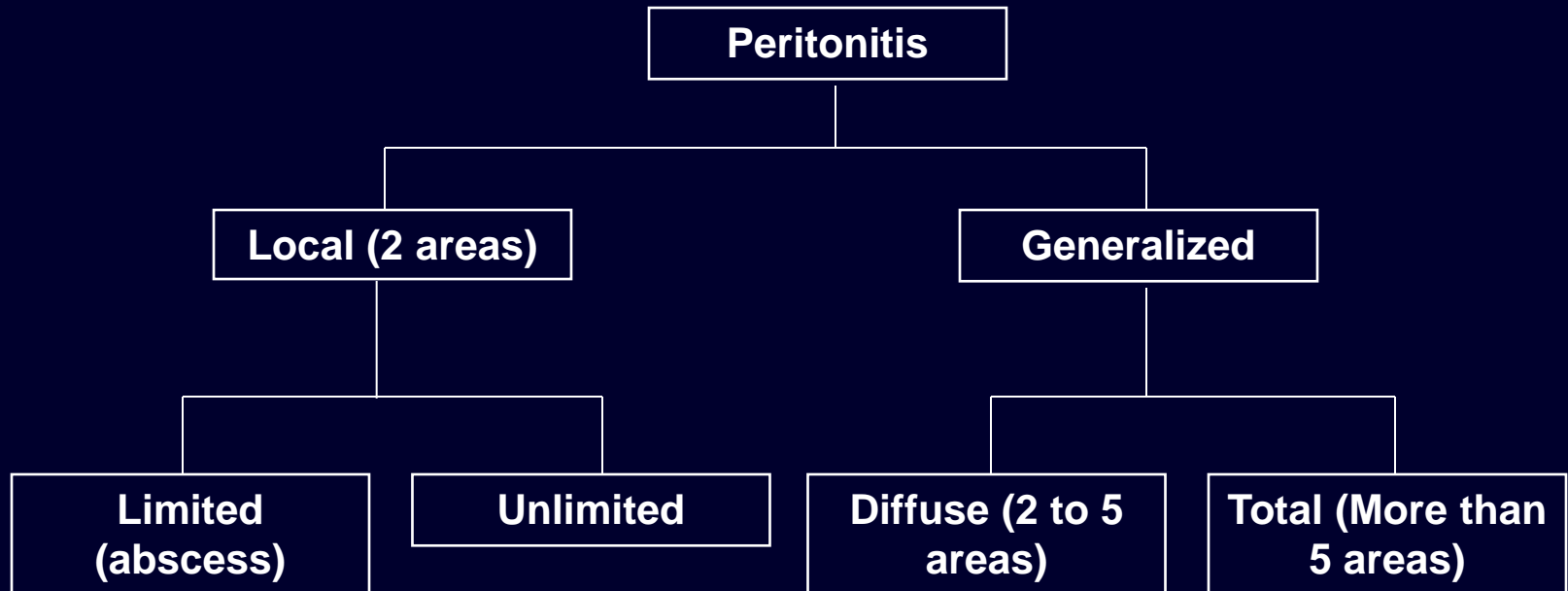
Region 9 - Left Iliac (Inguinal)



Classification

- Acute peritonitis
- Chronic peritonitis

- Primary,
- Secondary,
- Tertiary peritonitis



Classification

According to the intraperitoneal content:

Serous

Serous-fibrinous

Fibrinous-purulent

Purulent

Biliary

Urinary

Fermentative

Fecaloid

Classification

Hamburg classification (1987):

I. Primary peritonitis (ie, from hematogenous dissemination, usually in the setting of immunocompromise)

- A. Spontaneous peritonitis of childhood**
- B. Spontaneous peritonitis of adult**
- C. Peritonitis in patients with continuous ambulatory peritoneal dialysis**
- D. Tuberculous peritonitis**

II. Secondary peritonitis (ie, related to a pathologic process in a visceral organ, such as perforation or trauma, including iatrogenic trauma)

- A. Perforation peritonitis**
 - 1. Gastrointestinal tract perforation**
 - 2. Bowel wall necrosis**
 - 3. Pelvioperitonitis**

Classification

Hamburg classification (1987):

B. Postoperative peritonitis

- 1. Leak of an anastomosis**
- 2. Leak of suture line**
- 3. Stump insufficiency**

C. Posttraumatic peritonitis

- 1. Peritonitis after blunt trauma**
- 2. Peritonitis after penetrating trauma**

III. Tertiary peritonitis: (ie, persistent or recurrent infection after adequate initial therapy)

A. Fungal peritonitis

B. Without or with low grade of bacterial contamination

IV. Intraperitoneal abscesses, associated with:

A. Primary peritonitis

B. Secondary peritonitis

C. Tertiary peritonitis

Etiology and pathogenesis

Ways of infection penetrating peritoneal cavity:

- 1. Perforating way**
- 2. Hematogen way**
- 3. Lymphatic way**

Etiology and pathogenesis

Causes of perforation:

- **External source**
- **Pathological perforation of the gastrointestinal organs**
- **Perforation due to inflammatory processes out of the gastrointestinal system**
- **Postoperative peritonitis due to anastomotic leakage**

Etiology and pathogenesis

Common causes of peritonitis:

Acute appendicitis (30-50%)

Perforated gastroduodenal ulcer (10-27%)

Gangrenous cholecystitis (10-11%)

Multiple injuries of hollow organs (1-11%)

Postoperative complications (5%)

Acute necrotizing pancreatitis (4%)

Intestinal obstruction (3%)

Acute salpingitis

Large bowel perforation

Etiology and pathogenesis

The predominant pathogens

Aerobic

Staphylococci	8%
Streptococci	28%
Escherichia coli	61%
Enterobacter/klebsiella group	26%
Proteus	23%
Pseudomonas	8%

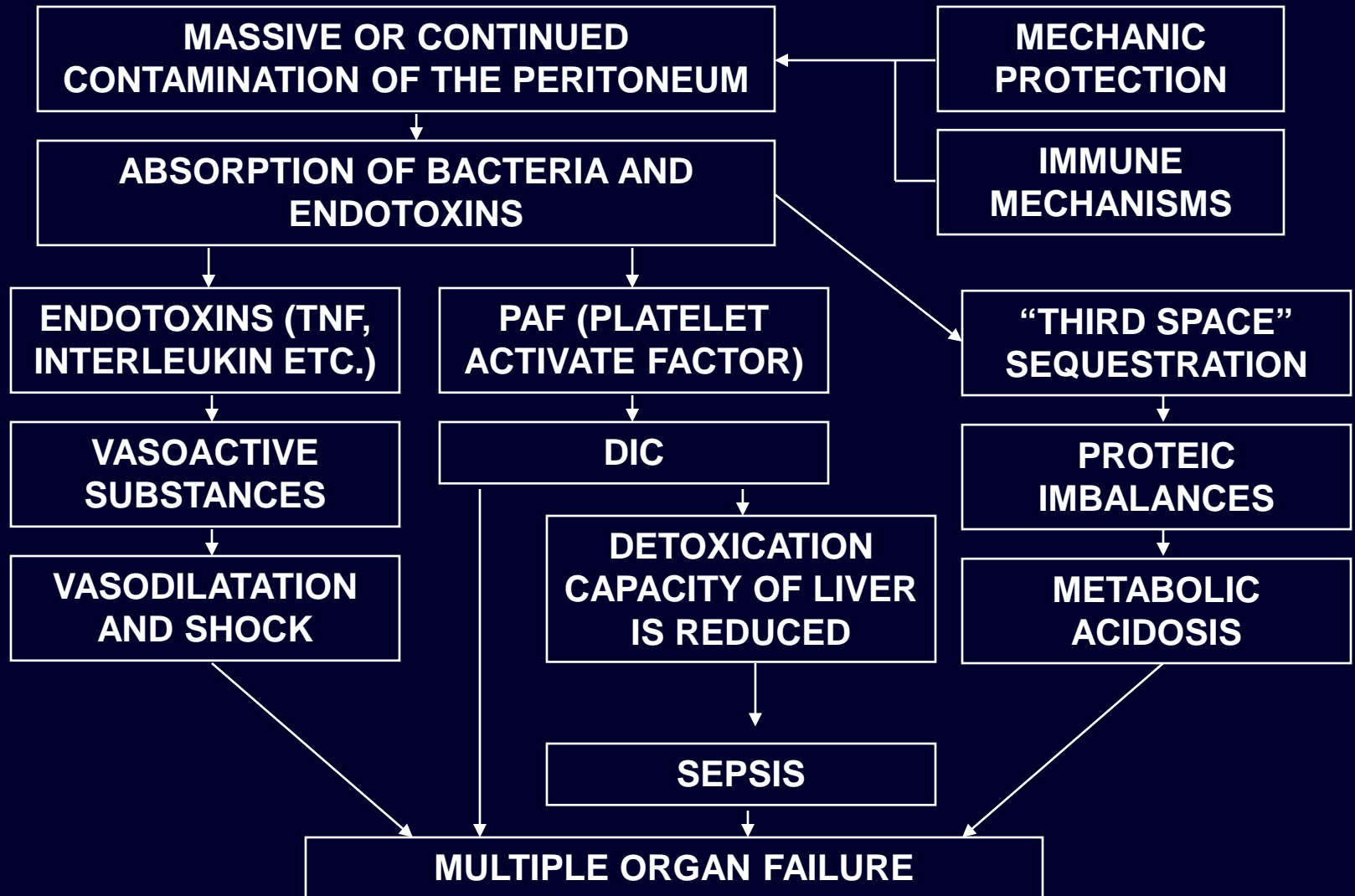
Anaerobic

Bacteroides fragilis	75%
Anaerobic cocci	25%
Clostridia	18%
Fusobacteria	9%
Eubacteria	25%

Fungi

Candida	2%
---------	----

Pathophysiology



The diagnosis of peritonitis is usually clinical. Diagnostic peritoneal lavage (DPL) may be helpful in patients who do not have conclusive signs on physical examination or who cannot provide an adequate history; in addition, paracentesis should be performed in all patients who do not have an indwelling peritoneal catheter and are suspected of having spontaneous bacterial peritonitis (SBP), because results of aerobic and anaerobic bacterial cultures, used in conjunction with the cell count, are useful in guiding therapy.

Presentation

STAGES OF THE CLINICAL EVOLUTION

EARLY - REACTIVE STAGE (FIRST 24 HOURS)

INTERMEDIATE – TOXIC STAGE (24 TO 72 HOURS)

LATE – TERMINAL STAGE (AFTER 72 HOURS)

A. HISTORY

History should include recent abdominal surgery, previous episodes of peritonitis, travel history, use of immunosuppressive agents, and the presence of diseases (eg, inflammatory bowel disease, diverticulitis, peptic ulcer disease) that may predispose to intra-abdominal infections.

Presentation

Abdominal pain, which may be acute or insidious, is the usual chief complaint of patients with peritonitis. Initially, the pain may be dull and poorly localized (visceral peritoneum); often, it progresses to steady, severe, and more localized pain (parietal peritoneum). Abdominal pain may be exacerbated by any movement (eg, coughing, flexing the hips) and local pressure. If the underlying process is not contained, the pain becomes diffuse. In certain disease entities (eg, gastric perforation, severe acute pancreatitis, intestinal ischemia), the abdominal pain may be generalized from the beginning.

Presentation

B. Abdominal (reflex) symptoms

Tenderness

Absence of abdominal movement on respiration

sign of cough

Blumberg's sign

Mandel-Razdolski sign

cutaneous hyperesthesia

Mondor's sign

Kullencampf-Grassmann's sign or "douglas' cry"

C. Toxic symptoms

Differential diagnosis

A. Extraabdominal diseases

Myocardial infarction (abdominal form)

Pleuropneumonia

Henoch's purpura

B. Abdominal non-surgical diseases

Biliary colic

Renal colic

Lead colic

Ruptured graafian follicle

C. Abdominal surgical diseases

Treatment

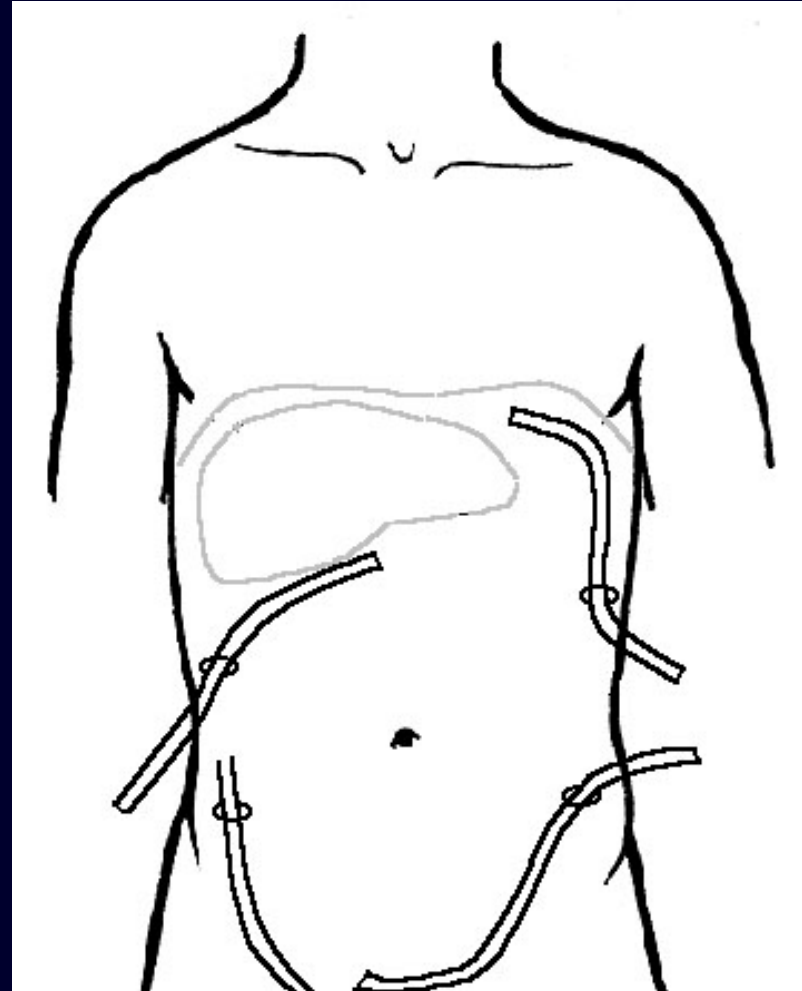
Surgical intervention

1. Removing of contaminated material (fluid, necrotic mass, fibrin)
2. Treatment of primary disease
3. Peritoneal lavage
4. Peritoneal drainage

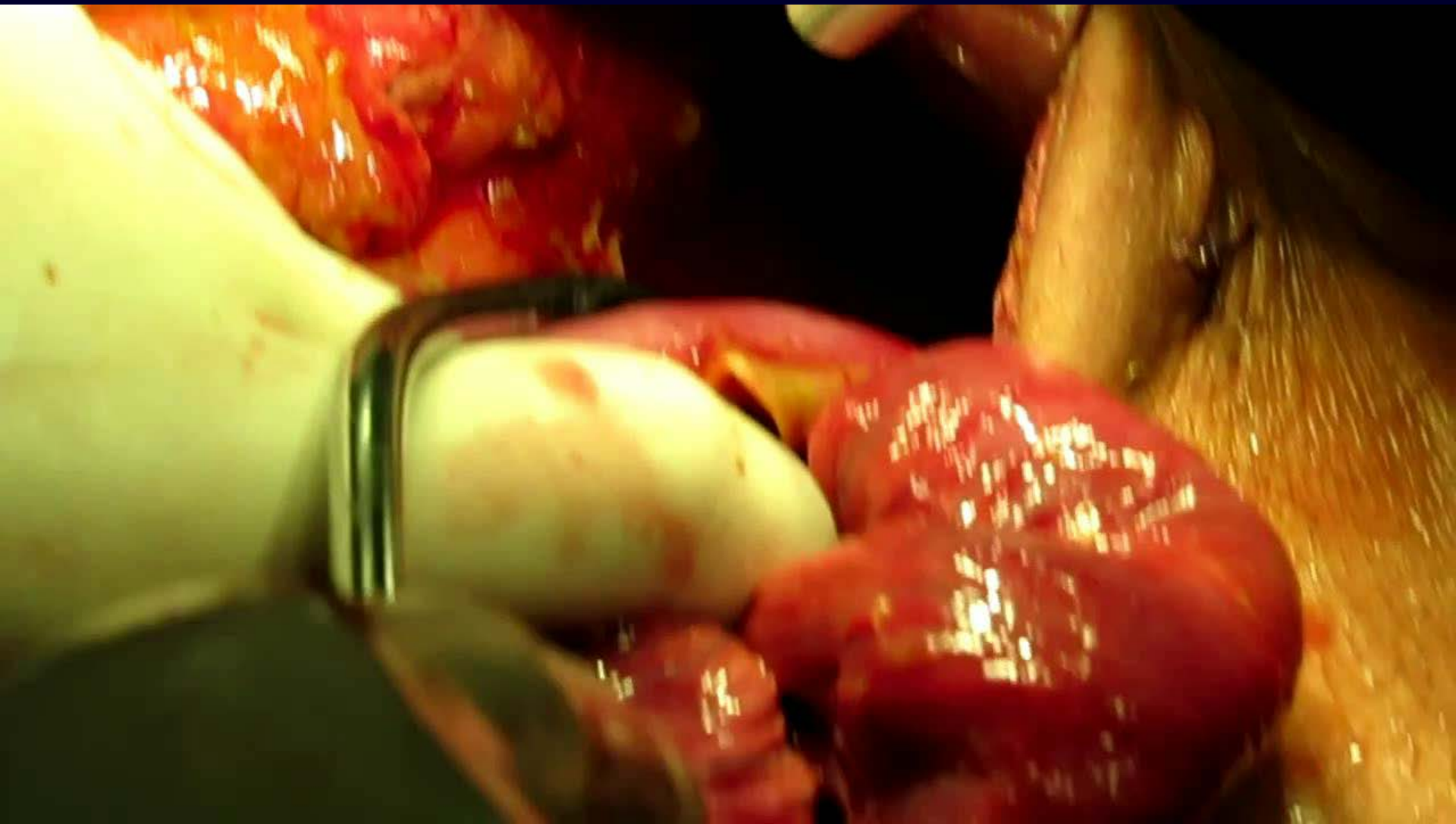
Antibiotics

Fluid and electrolyte replacement

Recovery of intestinal activity



Laparotomy for secondary peritonitis GJS leak



Laparoscopic treatment for appendicular diffuse peritonitis

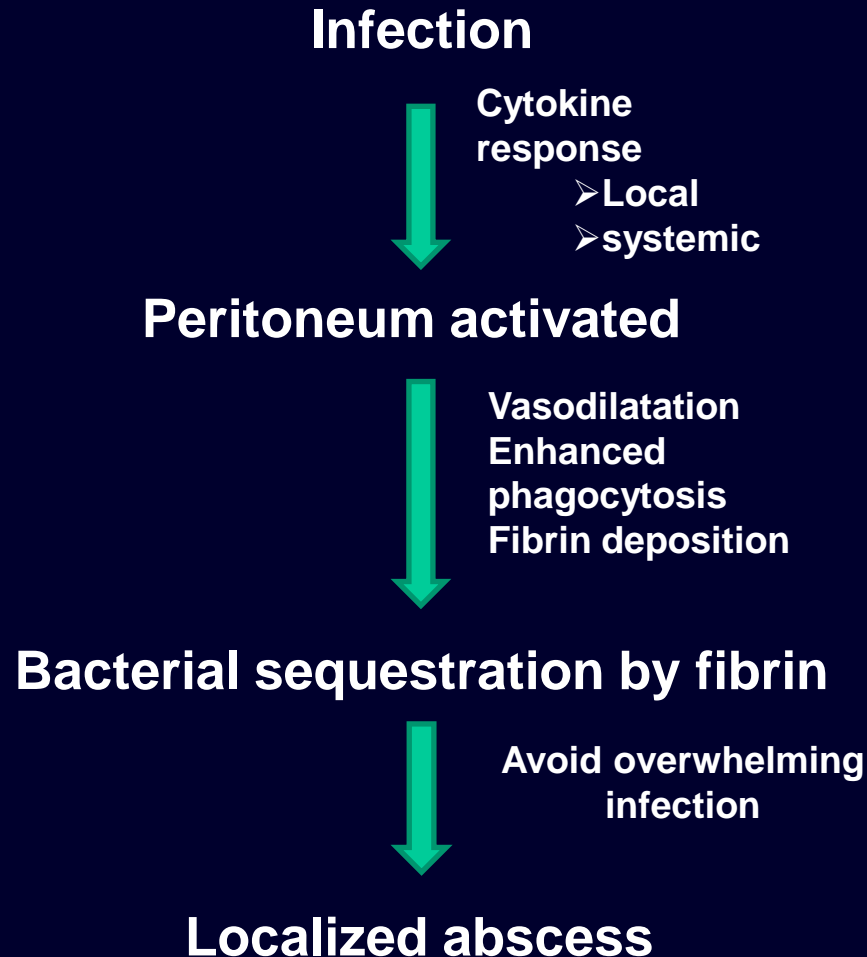


Intraperitoneal abscesses

Peritoneal abscess describes the formation of an infected fluid collection encapsulated by fibrinous exudate, omentum, and/or adjacent visceral organs. The overwhelming majority of abscesses occurs subsequent to secondary peritonitis. Abscess formation may be a complication of surgery. The incidence of abscess formation after abdominal surgery is less than 1-2%, even when the operation is performed for an acute inflammatory process. The risk of abscess increases to 10-30% in cases of preoperative perforation of the hollow viscus, significant fecal contamination of the peritoneal cavity, bowel ischemia, delayed diagnosis and therapy of the initial peritonitis, and the need for reoperation, as well as in the setting of immunosuppression. Abscess formation is the leading cause of persistent infection and development of tertiary peritonitis.

Pathophysiology

Omentum – the “policeman” of the peritoneal cavity



Peritoneal abscess

Perforated appendix – 10%

Destructive cholecystitis – 9%

Pancreatic necrosis – 5%

Perforated diverticulitis – 4%

Subdiaphragmatic abscesses

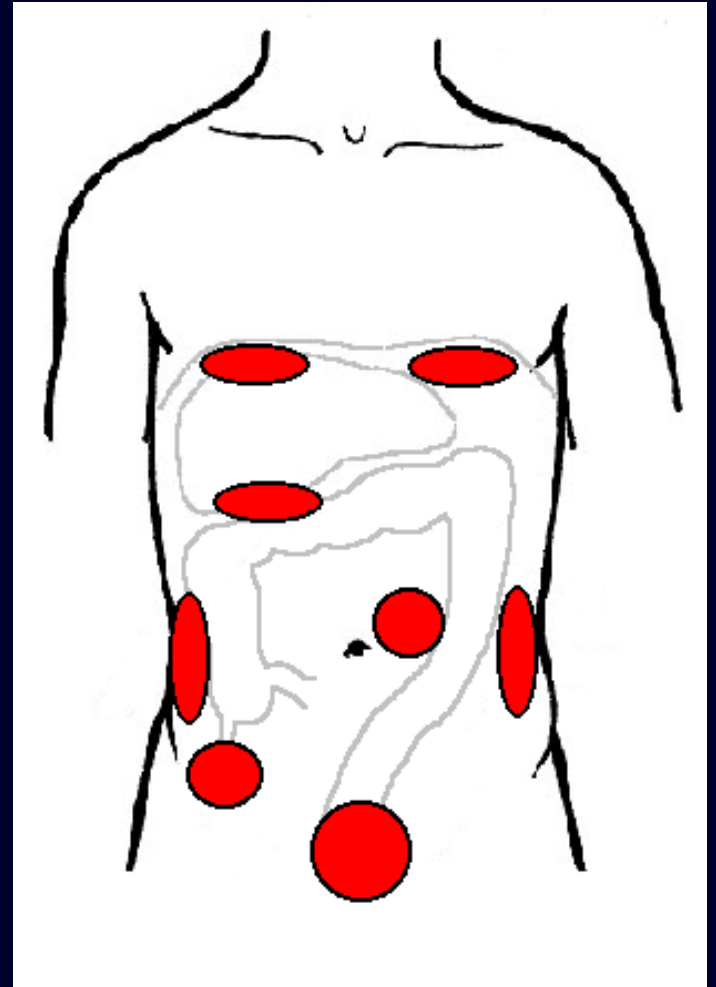
Subhepatic abscess

Inter-intestinal abscess

Paracolic abscesses

Periappendiceal abscess

Pelvic (Douglas's) abscess



Clinical signs

- **Extra-visceral abscesses**
 - **Following failed anastomoses**
 - **Infection of intra-peritoneal fluid collections**
 - **Following abdominal surgery**
 - **Contained leakage from spontaneous visceral perforation**
 - **Residual loculations following diffuse peritonitis**
 - **High spiking fevers, chills**
- **Abdominal pain**
- **Anorexia**
- **Delay of return of bowel function**
- **Septicemia**

Clinical signs

- **Subphrenic abscesses**
 - Vague upper quadrant pain
 - Referred shoulder pain
 - Hiccoughs
- **Paracolic, interloop abscesses**
 - Palpable abdominal mass
 - Localized tenderness
- **Pelvic abscess**
 - Irritation of bladder & rectum
 - Frequency of urine
 - Diarrhea, tenesmus

Investigations

- **Complete blood cell count (CBC)**
- **Specific**
 - **LFT**
 - **RFT**
 - **Amylase, lipase**
 - **Coagulation profile**
 - **Cultures – blood, urine**
 - **ABG (arterial blood gases)**

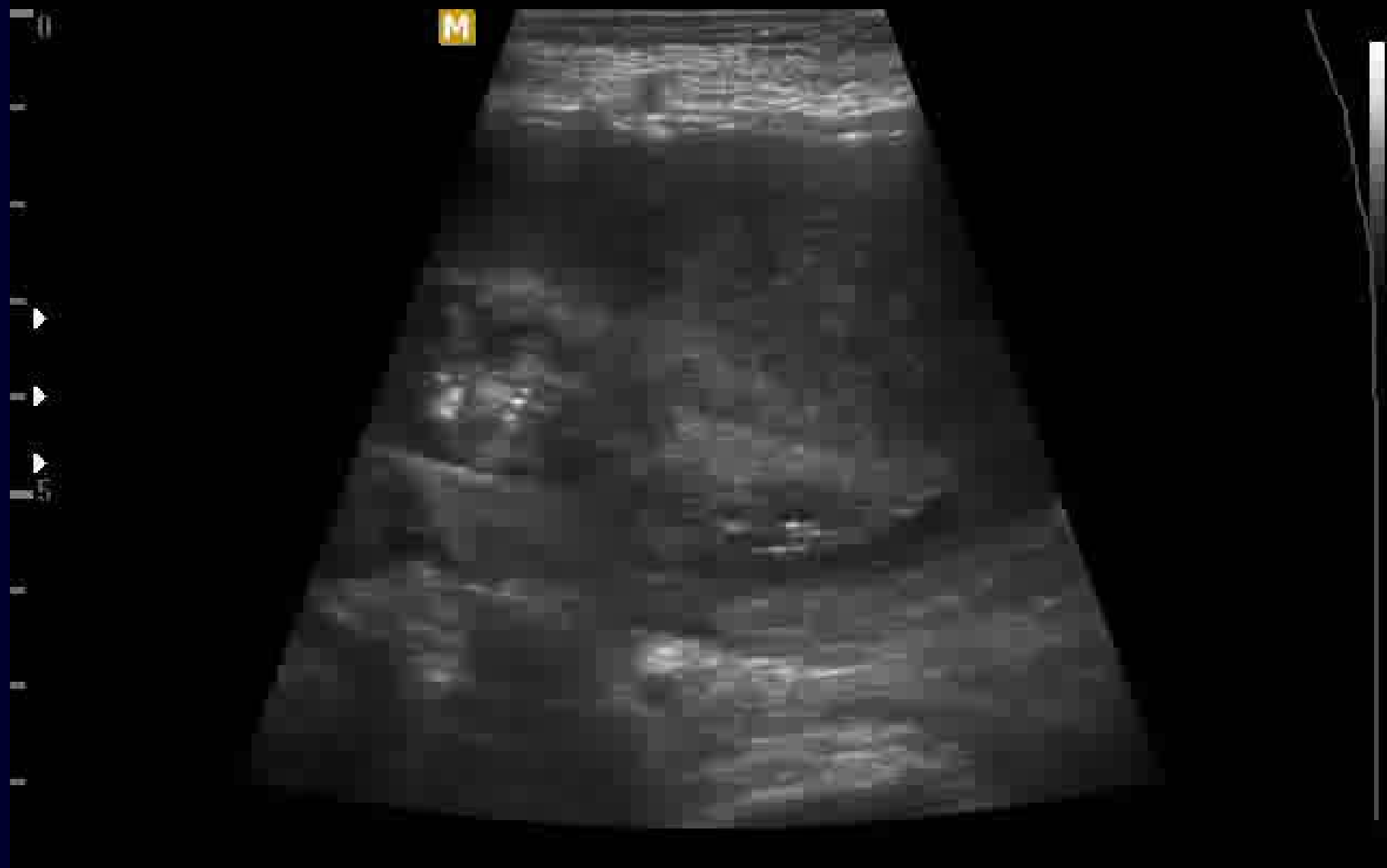Investigations

- **Plain X-ray abdomen**
 - **Air fluid levels – extraluminal**
 - **Mass effect**
 - **Differentiate**
 - **Pulmonic, sub diaphragmatic fluid**
- **USG**
 - **Fluid collections**
 - **Accuracy for finding abscess in abdomen – 97%**
 - **Sensitivity – 93 %**
 - **Specificity – 99%**

L5-12EC/SmallParts/FPS9D/8.5cm/Pen./MI0.72/TIs0.3/06-05-2012 14:39:40

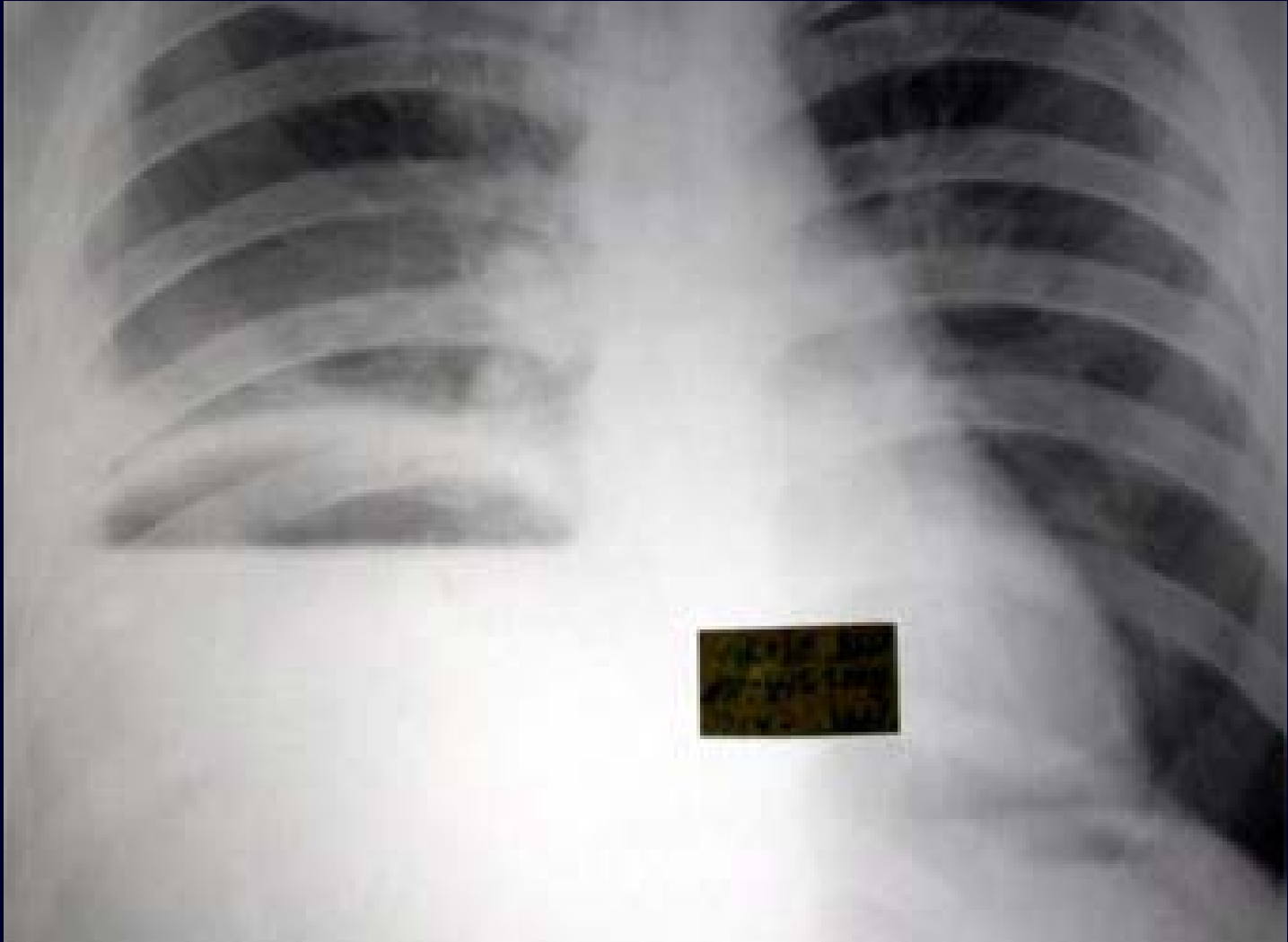
[2D] G73/96dB/FA10/P90/FSI 1

0.3
148



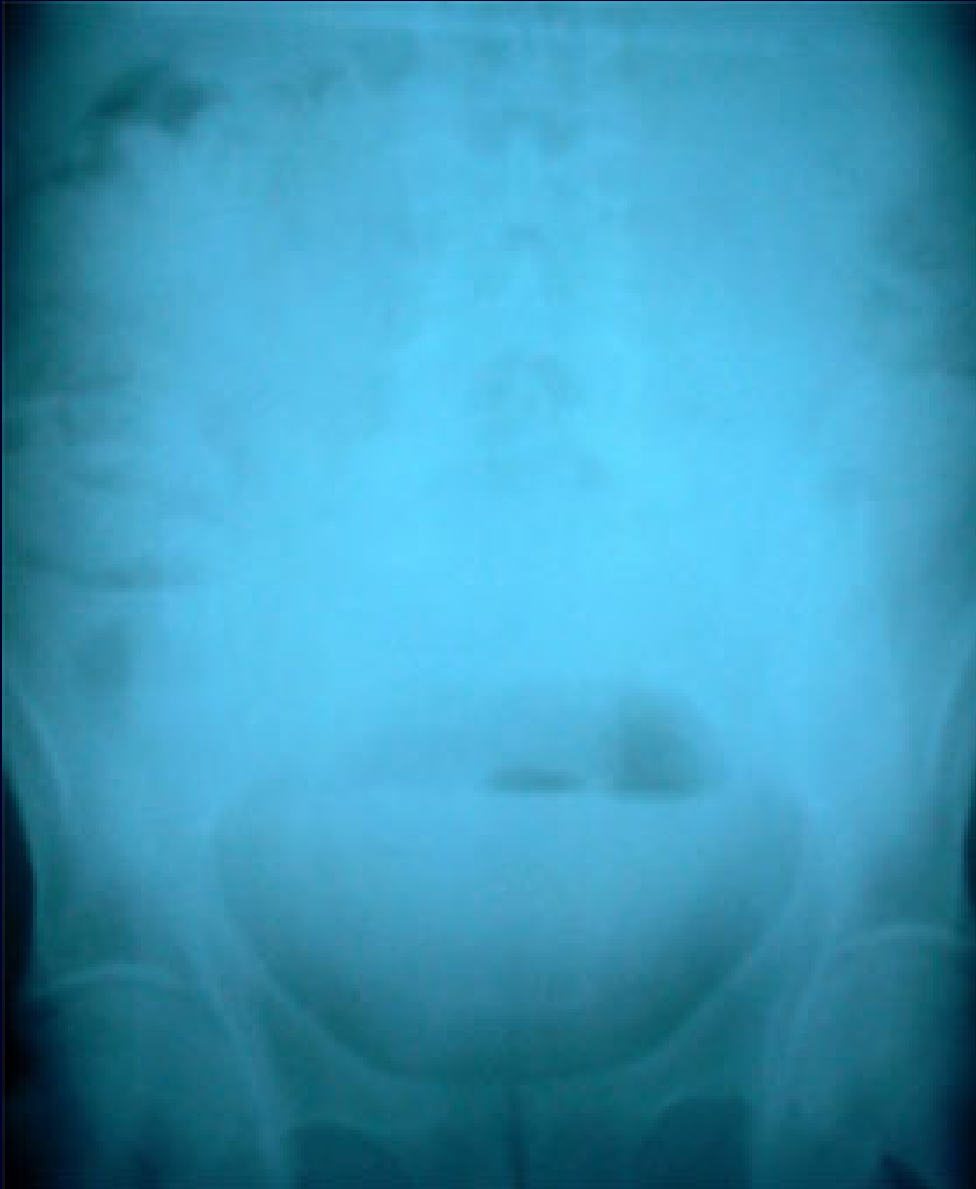Perforated bowel with abscess formation (gas bubbles are observed)

Peritoneal abscess



**Air-fluid level and a raised hemidiaphragm in
subphrenic abscess**

Peritoneal abscess



**Pelvic (douglas's) abscess
on plain x-ray film**

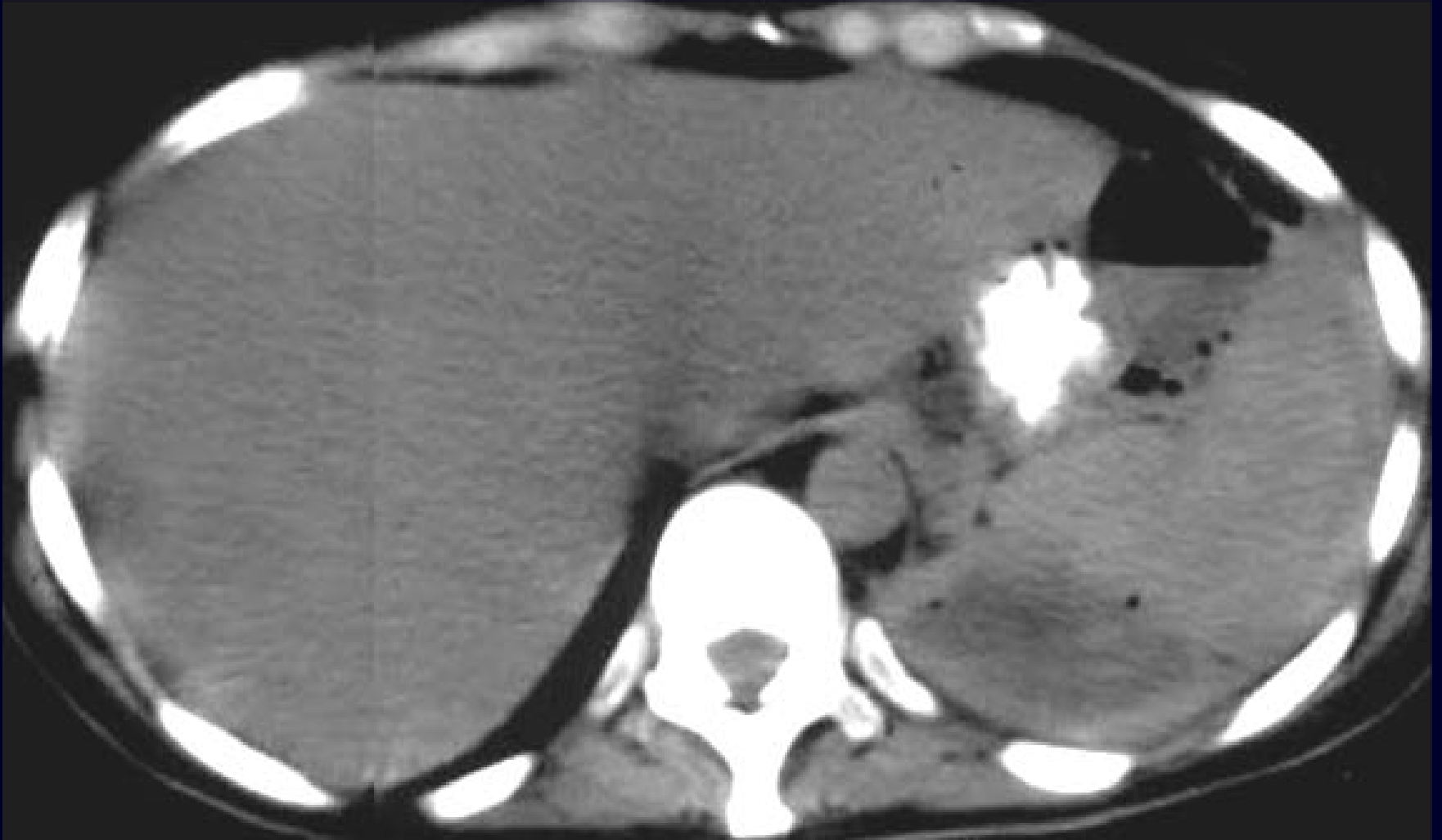Investigations

- **CT scan**
 - **Detection rate – 97%**
 - **Abscess**
 - **Area of low attenuation, non enhancing in extra luminal location or with in solid organ**
 - **Density – between water & solid tissue**
 - **Mass effect**
 - **Gas in collection**

USG vs. CT

	Advantages	Disadvantages
USG	<ul style="list-style-type: none"> ➤ Rapid exam ➤ Lower cost ➤ No need for pt transport ➤ Good for evaluation of <ul style="list-style-type: none"> ✓ Pelvis, ✓ RUQ, ✓ LUQ (if spleen +) ➤ Can demonstrate septations 	<ul style="list-style-type: none"> ➤ Operator dependent ➤ Poor for imaging bowel ➤ Limited by air in bowel (ileus) <ul style="list-style-type: none"> ✓ Staples ✓ Stomas ✓ Dressings ✓ Fat
CT scan	<ul style="list-style-type: none"> ➤ Good for entire abdomen ➤ Especially evaluation for retroperitoneum & pancreas 	<ul style="list-style-type: none"> ➤ Can't distinguish abscesses with high protein content ➤ May be difficult to differentiate subphrenic from pulmonary fluid ➤ May miss septations

Peritoneal abscess



Left subphrenic abscess on ct

Management

- **Localization of the abscess**
 - **Antibiotic coverage**
 - **Enteric**
 - **aerobes**
 - **anaerobes**
 - **Drainage**
 - **Percutaneous**
 - **Surgical**
- } **Similar results**

Management

Percutaneous drainage

- **Safe alternative to surgery**
- **Advantages**
 - **Avoid generalized abdominal complications**
 - **Low cost**
- **Prerequisites**
 - **Anatomically safe route**
 - **Well defined uniloculated cavity**
- **Technical failure**
 - **Senior surgical back-up**

Management

Percutaneous drainage

- **Contraindications**
 - **Absence of appropriate access routes**
 - **Internal septations & loculations**
 - **Coagulopathy**

- **Not contraindications**
 - **Multiple abscesses**
 - **Abscesses with enteric connections**
 - **Need to traverse through solid viscera**

Management

Percutaneous drainage

- **USG/ CT guided**
- **Catheter size**
 - **8F – 12F**
- **Cavity decompress & collapse**
- **Irrigation OD**
- **Repeat scan for residual contents**
- **If drain continued steady/ increase**
 - **Suspect enteric fistula**

Management

Percutaneous drainage

- **Complications**
 - **Bacteremia**
 - **Sepsis**
 - **Vascular injury**
 - **Enteric puncture**
 - **Cutaneous fistula**
 - **Transpleural catheter placement**

Management

Surgical drainage

➤ Indications

- Well defined abscesses
- Fungal abscesses
- Infected hematomas
- Necrotic tumor masses
- Inter-loop abscesses
- Unlike success of percutaneous approach
- Failed attempts

Management

Surgical drainage

- **Transperitoneal approach**
 - **Examination of entire abdominal cavity**
 - **Can drain multiple abscesses**
 - **Protect the wound with antibiotic soaked towels**
 - **Drain cavity quickly**
 - **Minimise spillage**
 - **Cavity widely opened**
 - **Cultures**
 - **Resistent abscess**
 - **Biopsy – abscess wall**
 - **Copious warm antibiotic irrigation**

Management

Surgical drainage

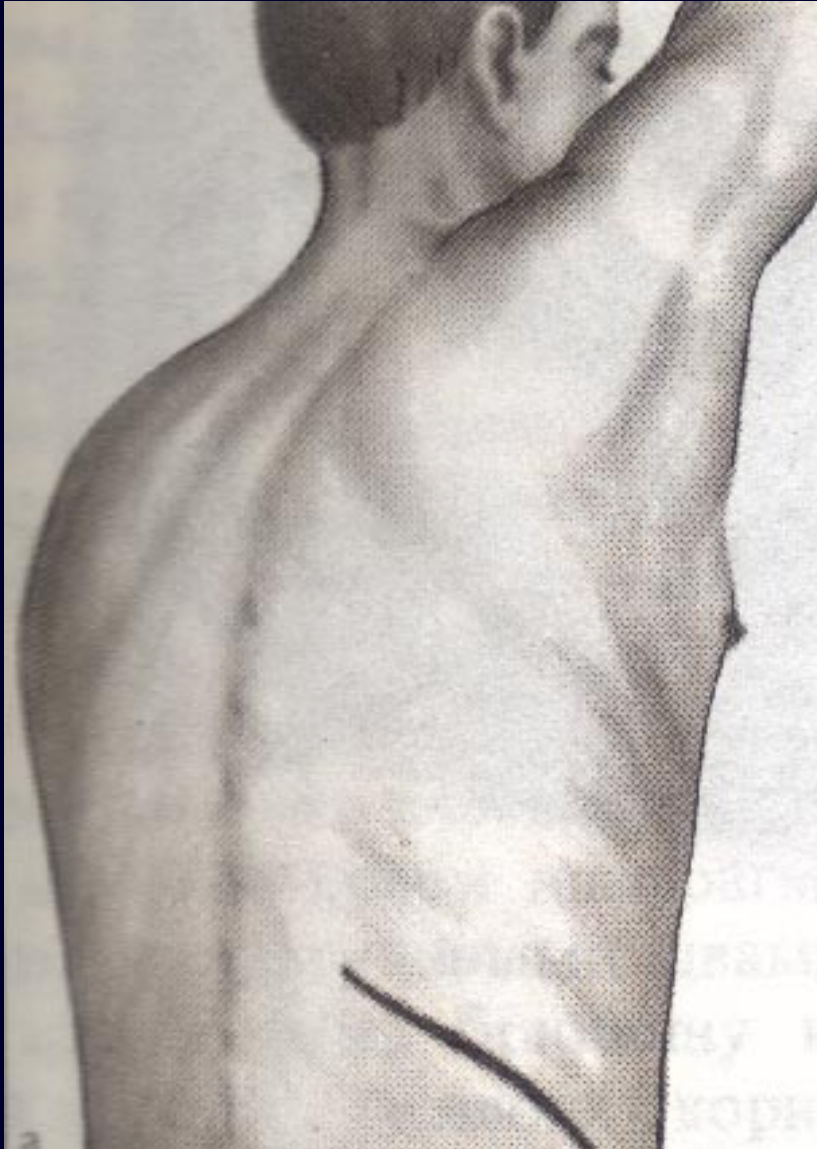
- **Closed suction drains**
 - **Dependent positions**
- **Extremely contaminated cases**
 - **Pack & left open**
 - **Subcuticular closure**
 - **Closed subcuticular suction drain**
- **Drains at least for 10 days**
 - **Suppuration occurs late**

Management

Surgical drainage

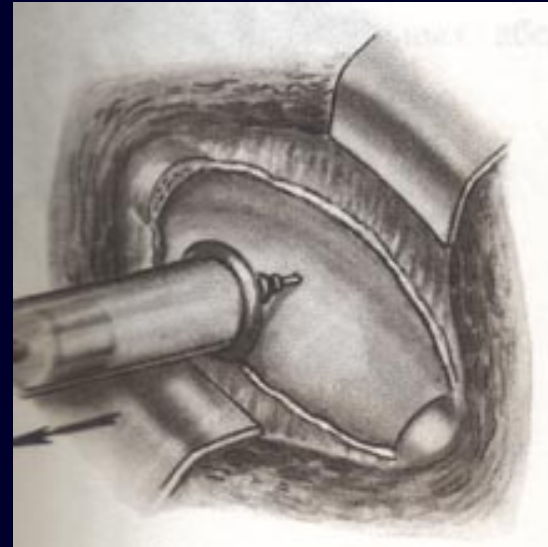
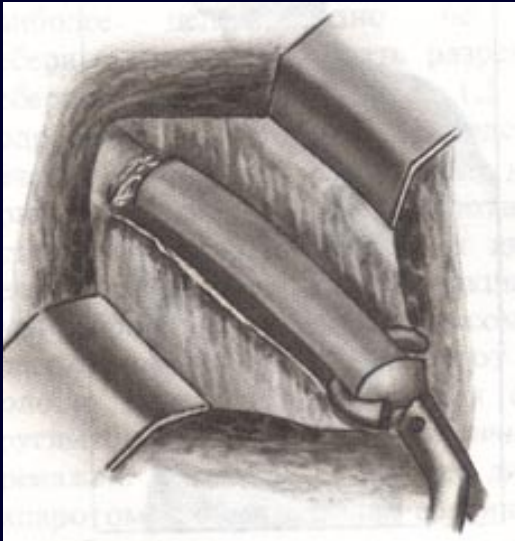
- **Post-operative**
 - **Ileus**
 - **Parenteral nutrition – if required**
 - **Trophic feeds**
 - **To avoid villous atrophy**
 - **Drains**
 - **Prevent obstruction**
 - **Routine flush**
 - **NS/ antibiotic solution**

Peritoneal abscess

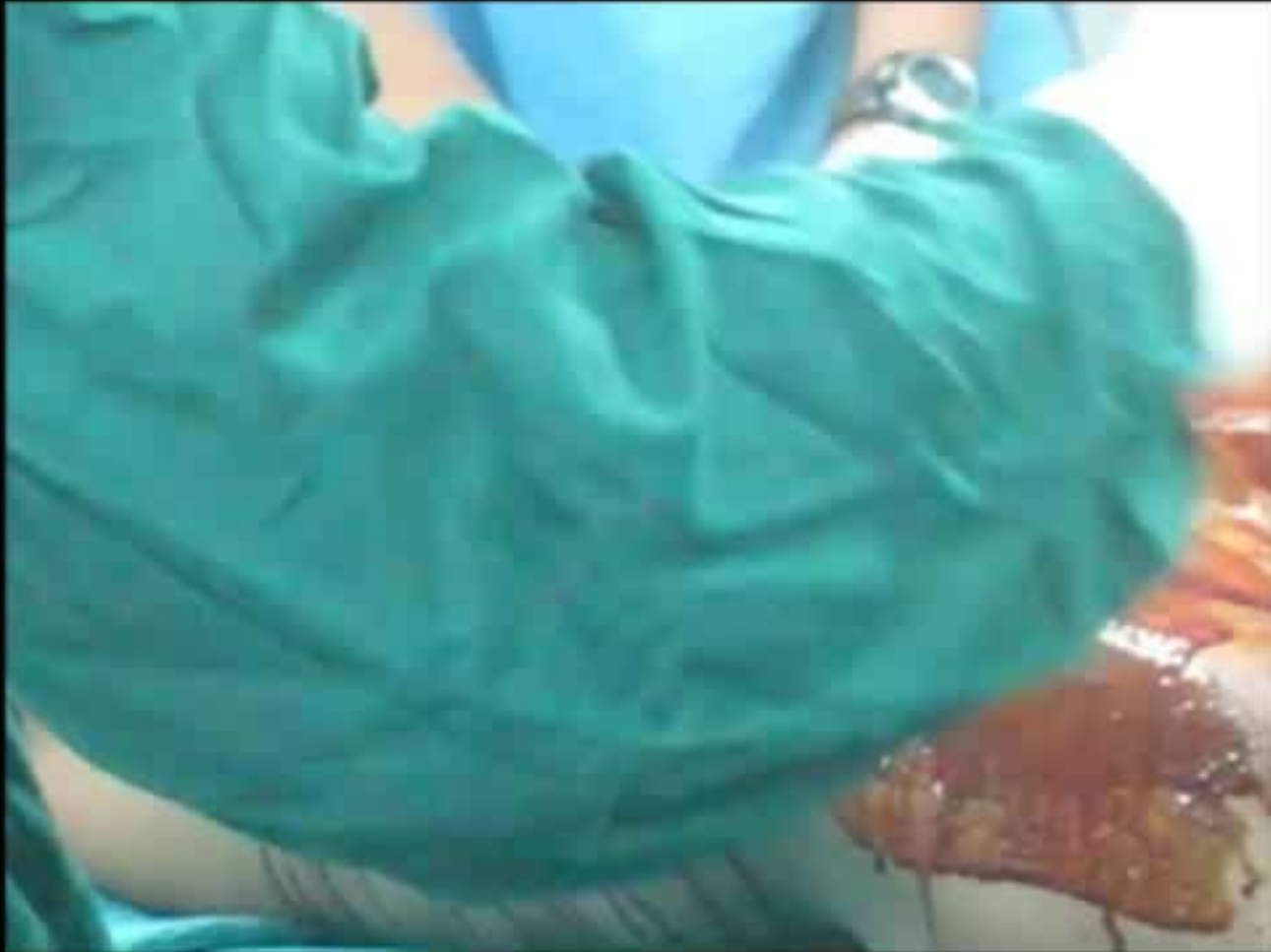

**Nather-ochsner incision for
posterior subphrenic abscesses**

Peritoneal abscess



Exploratory laparotomy for ruptured subdiaphragmatic abscess



Open abdomen

Introduction

The management of complex abdominal problems with the open abdomen and temporary abdominal closure techniques has become a common and valuable tool in surgery.

Damage control for life-threatening intra-abdominal bleeding, early recognition and treatment of intra-abdominal hypertension (IAH) and abdominal compartment syndrome (ACS), and new strategies in the management of severe intra-abdominal sepsis have resulted in a major increase in the number of cases treated with an open abdomen.

Indications

There are 3 major indications for the use of the open-abdomen technique:

- (1) prevention or treatment of the ACS**
- (2) damage control for life-threatening intra-abdominal bleeding**
- (3) management of severe intra-abdominal sepsis**

Although the open abdomen is usually effective in addressing the primary disorder, it is also associated with serious complications, such as:

- severe fluid and protein loss,**
- nutritional problems,**
- enteroatmospheric fistulas,**
- fascial retraction with loss of abdominal domain,**
- development of massive incisional hernias.**

The role of the open abdomen in the management of severe secondary peritonitis has been a controversial issue. In the 1980s and 1990s, from small retrospective studies, there was a significant interest and enthusiasm in the concept of treating severe peritonitis with the open-abdomen technique, using passive dressings for temporary abdominal closure.

Guthy E. Scand J Gastroenterol Suppl 1984;100:49–52.
Hedderich GS et al. 1986;99(4):399–408.

However, subsequent studies failed to show any significant benefit. In a prospective, open, nonrandomized trial, sponsored by the Surgical Infection Society, 239 patients with surgical infection in the abdomen were treated with either the open-abdomen technique or laparotomy on demand. There was no significant difference in mortality between patients treated with a closed-abdomen technique (31% mortality) and those treated with variations of the open-abdomen technique (44% mortality).

Christou NV, et al. Arch Surg 1993;128(2):193–9.

In a 2007 study, Robledo and colleagues, randomized 40 patients with severe secondary peritonitis into an open-abdomen group and a laparotomy-on-demand group. Although the difference in the mortalities between the open technique and laparotomy on demand (55% vs 30%) did not reach statistical significance, the relative risk and odds ratio for death were 1.83 and 2.85 times higher in the open-abdomen group.

The study concluded that closed management of the abdomen may be a more rational approach in the management of severe peritonitis.

In summary, there is reasonable clinical evidence that temporary closure of the open abdomen using traditional abdominal packing is of no benefit and might be associated with increased mortality and a higher incidence of enteroatmospheric fistulas compared with the closed-abdomen and relaparotomy-on-demand technique.

However, recent experimental and clinical work has suggested that the openabdomen technique with temporary abdominal wall closure using negative pressure therapy (NPT) methods is associated with superior outcomes.

Amin and Shaikh, in a prospective analysis of 20 patients requiring NPT following laparotomy for severe peritonitis, reported 100% survival.

Amin AI, Shaikh IA. World J Gastroenterol 2009;15(27):3394–7.

Horwood and colleagues, in a study of 27 patients who were treated with an open abdomen and NPT, reported a significantly improved observed survival compared with P-POSSUM (physiological and operative severity score for the enumeration of mortality and morbidity) expected survival ($P = .004$). The study concluded that laparostomy with immediate NPT is a robust and effective system to manage patients with severe peritonitis.

Horwood J, Akbar F, Maw A. Ann R Coll Surg Engl 2009; 91(8):681–7.

In summary, the open abdomen has a major therapeutic role in damage-control procedures and in the management of IAH.

There is some strong experimental and class III clinical evidence that the open abdomen with temporary closure using negative pressure techniques might be beneficial in the management of severe secondary peritonitis.

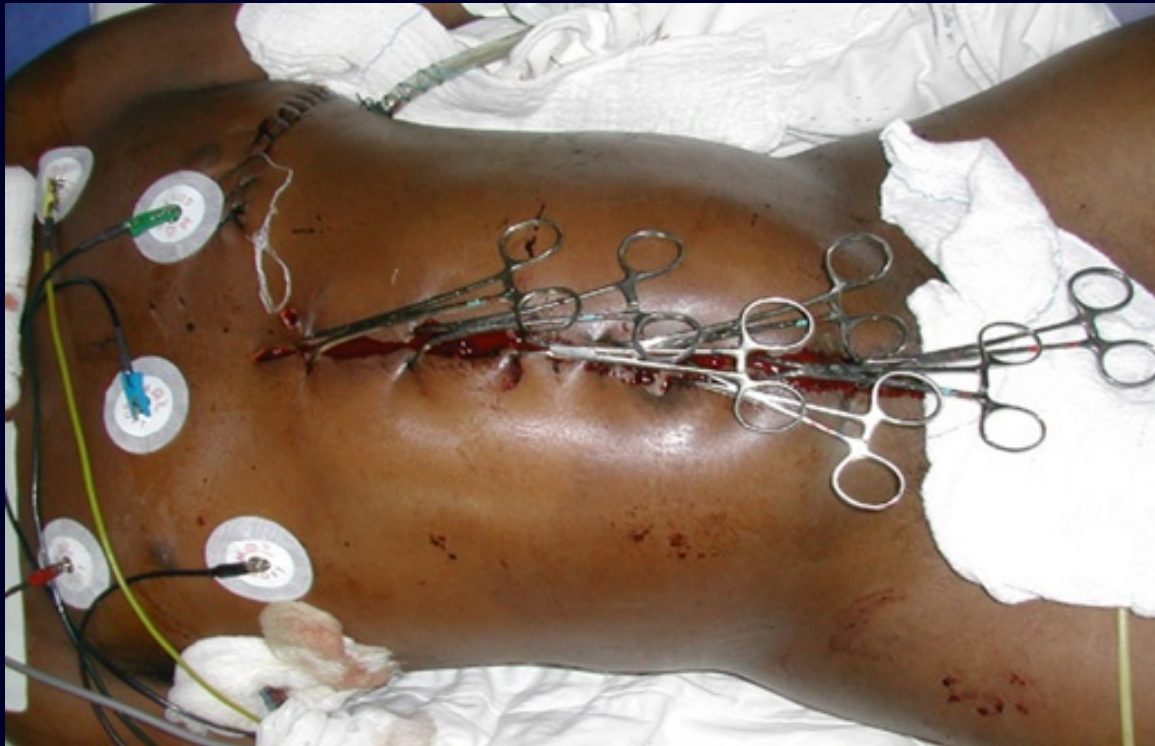Techniques for temporary abdominal wall closure

- 1. Skin approximation with towel clips or running suture**
- 2. Bogota bag**
- 3. Synthetic meshes**
- 4. Velcro or zipper-type synthetic materials (Wittmann patch, Starsurgical)**
- 5. Negative pressure dressing**
 - a. Vacuum pack (Barker technique)**
 - b. Vacuum-assisted closure (V.A.C. Therapy, KCI)**
 - c. ABThera system (KCI)**

Skin approximation with towel clips or running suture has been suggested as a method for quick abdominal closure in damage-control procedures in patients in extremis.

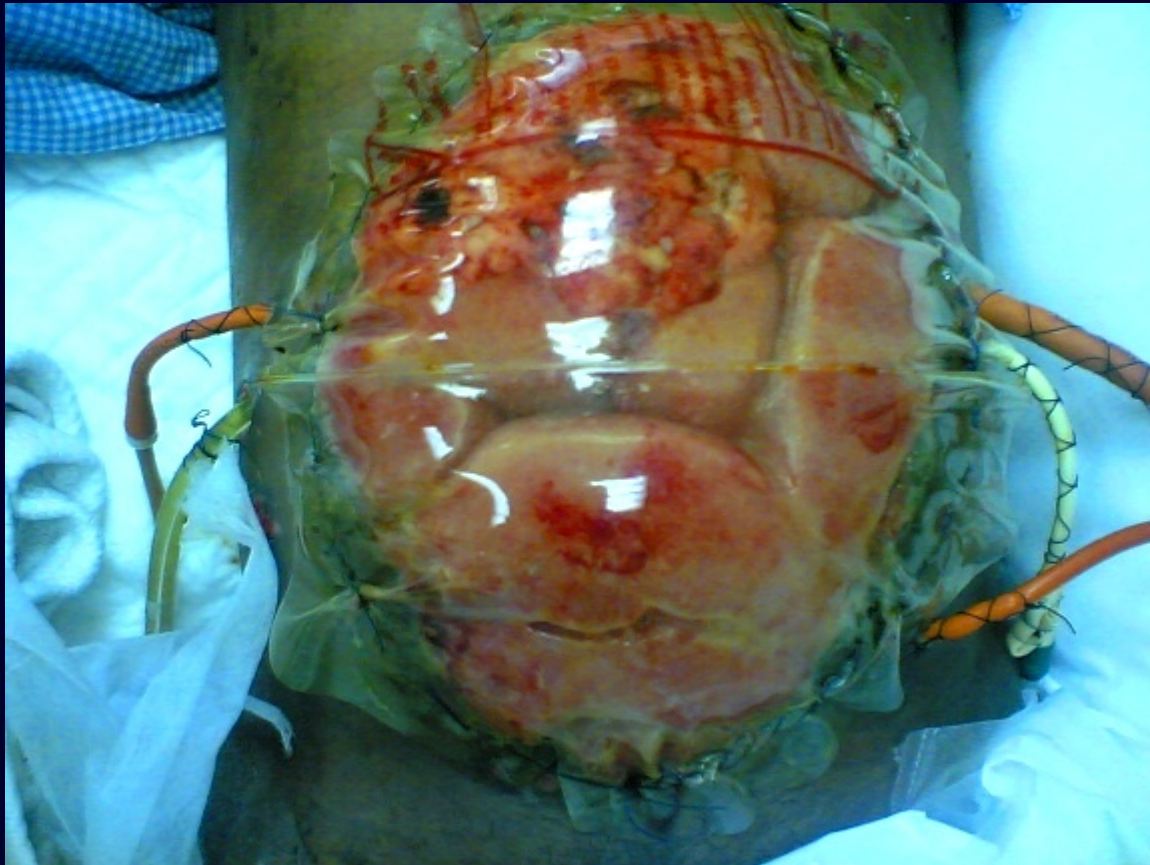This type of closure is associated with an unacceptably high incidence of IAH and ACS and should not be used.

**Offner PJ, et al. Arch Surg 2001;136(6):676–81.
Raeburn CD, et al. Am J Surg 2001;182(6):542–6.**

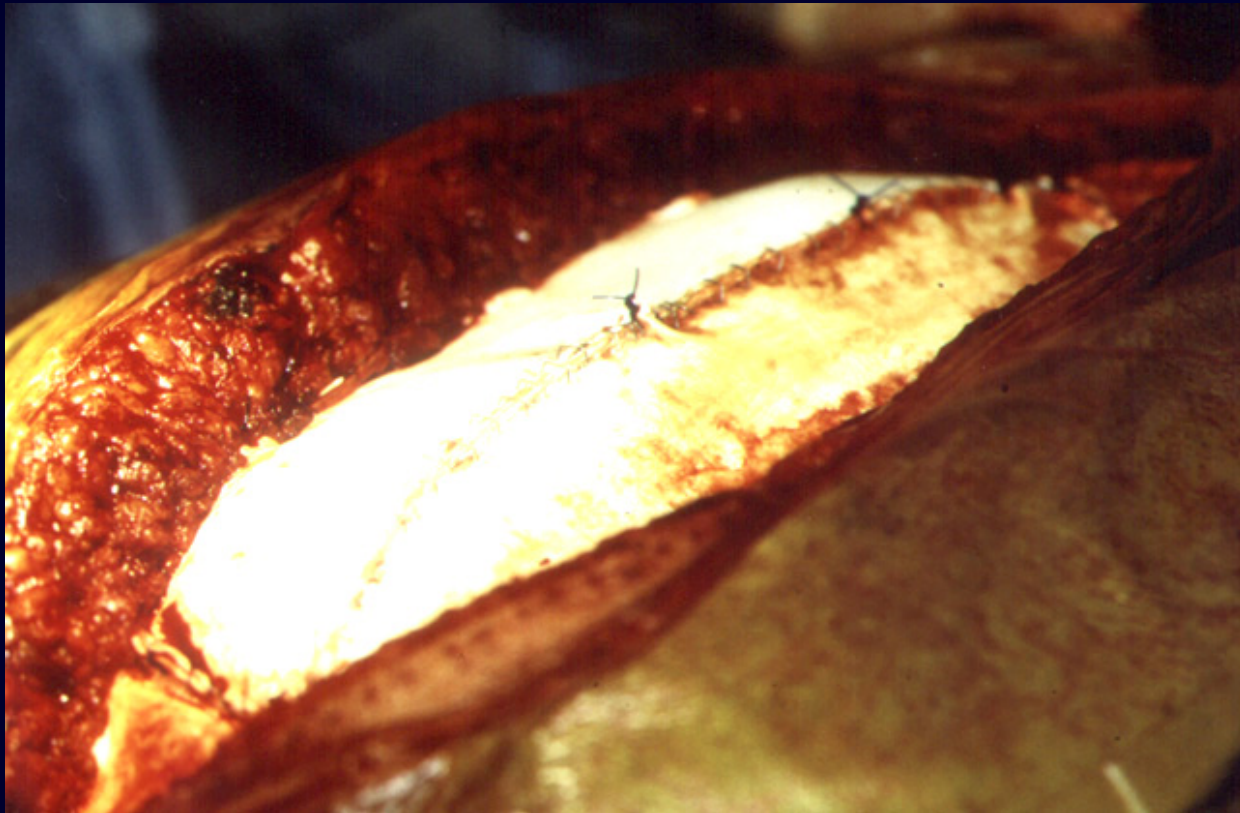


Left lateral thoracotomy with towel clip closure of damage-control celiotomy. Courtesy of Pedro Gustavo R. Teixeira, Trauma Surgeon, Brazil, The Trauma Imagebank.

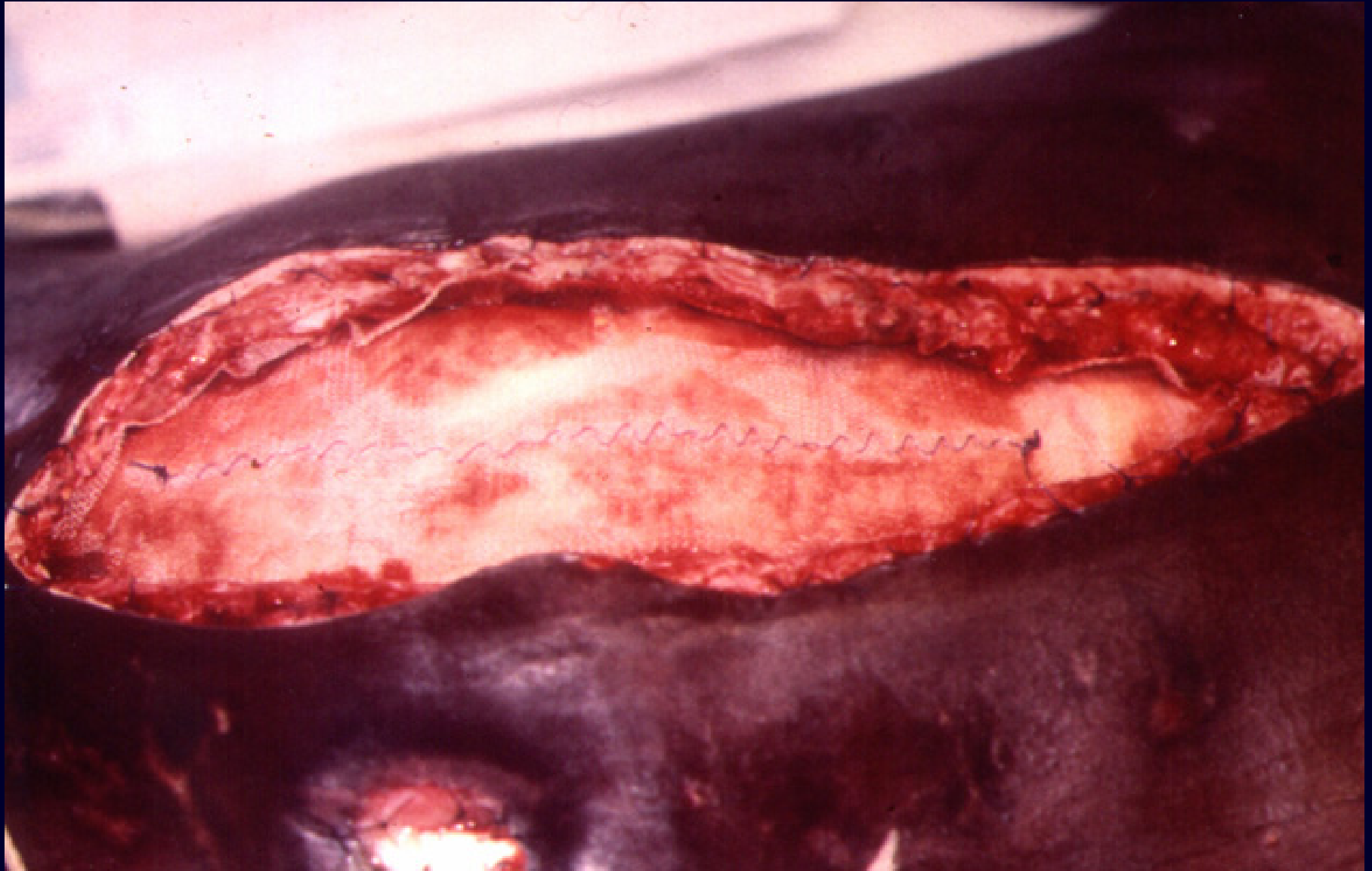
The Bogota bag or silo usually consists of a 3-L sterile irrigation bag or a sterile radiographic cassette cover, stapled or sutured to the fascia or the skin. It prevents evisceration of the abdominal contents while preventing or treating IAH or ACS. It is still used extensively in many countries because it is cheap, immediately available, and easy to apply.



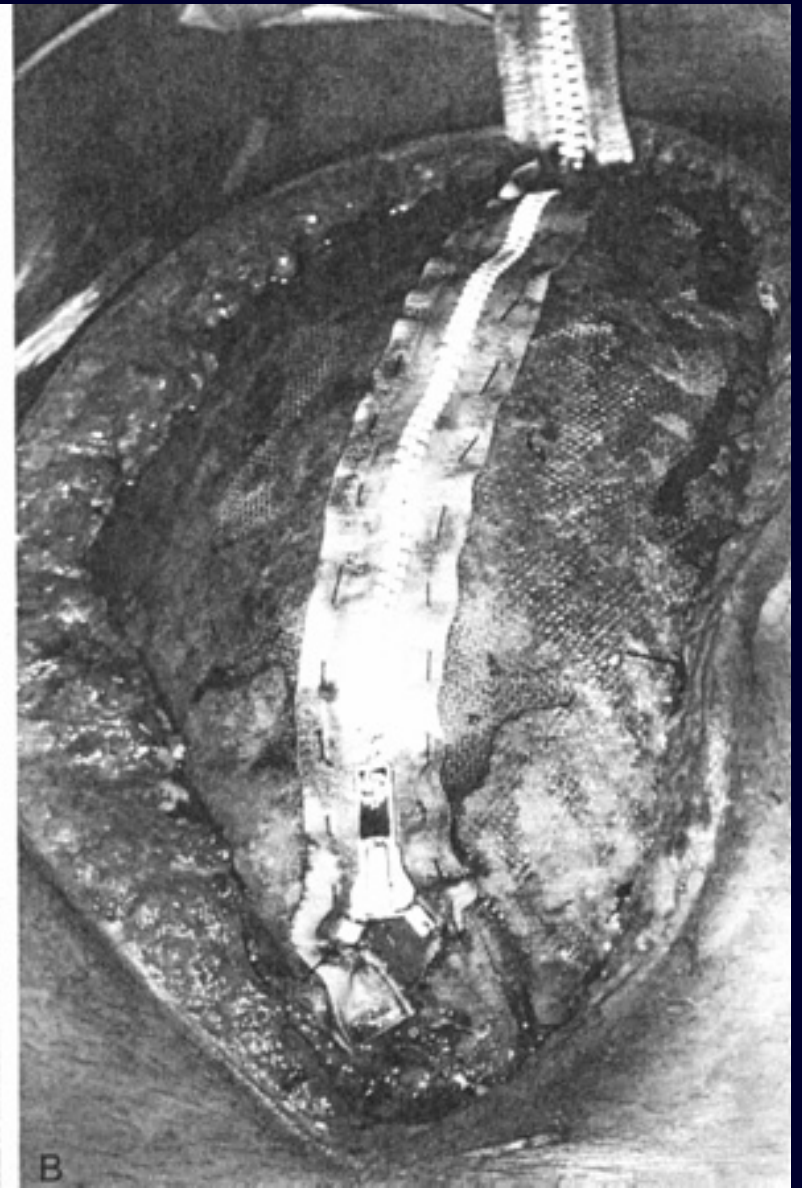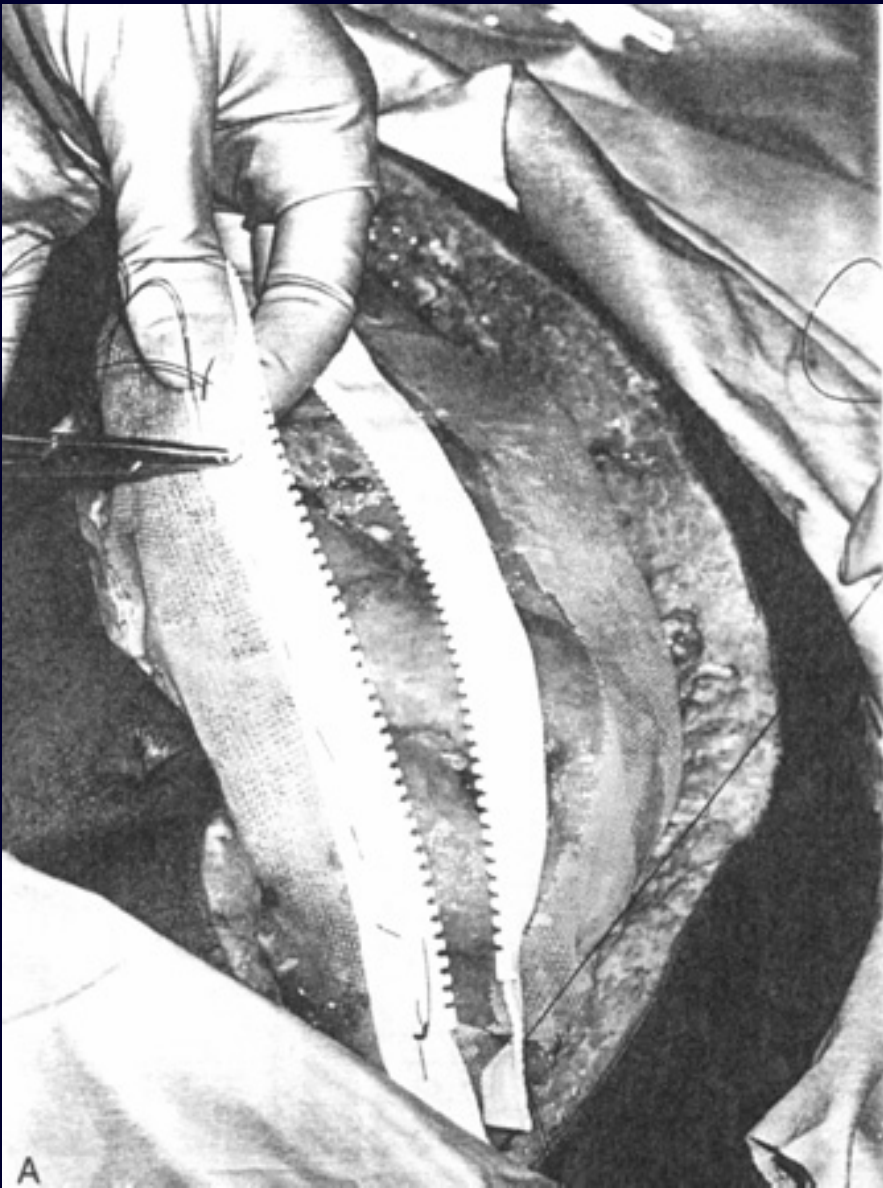
Absorbable or nonabsorbable meshes or sheets have been used for temporary abdominal wall closure. The material is sutured between the fascial edges and, as the bowel edema subsides, the mesh or sheet may be plicated and reduced in size, allowing gradual reapproximation of the fascia.



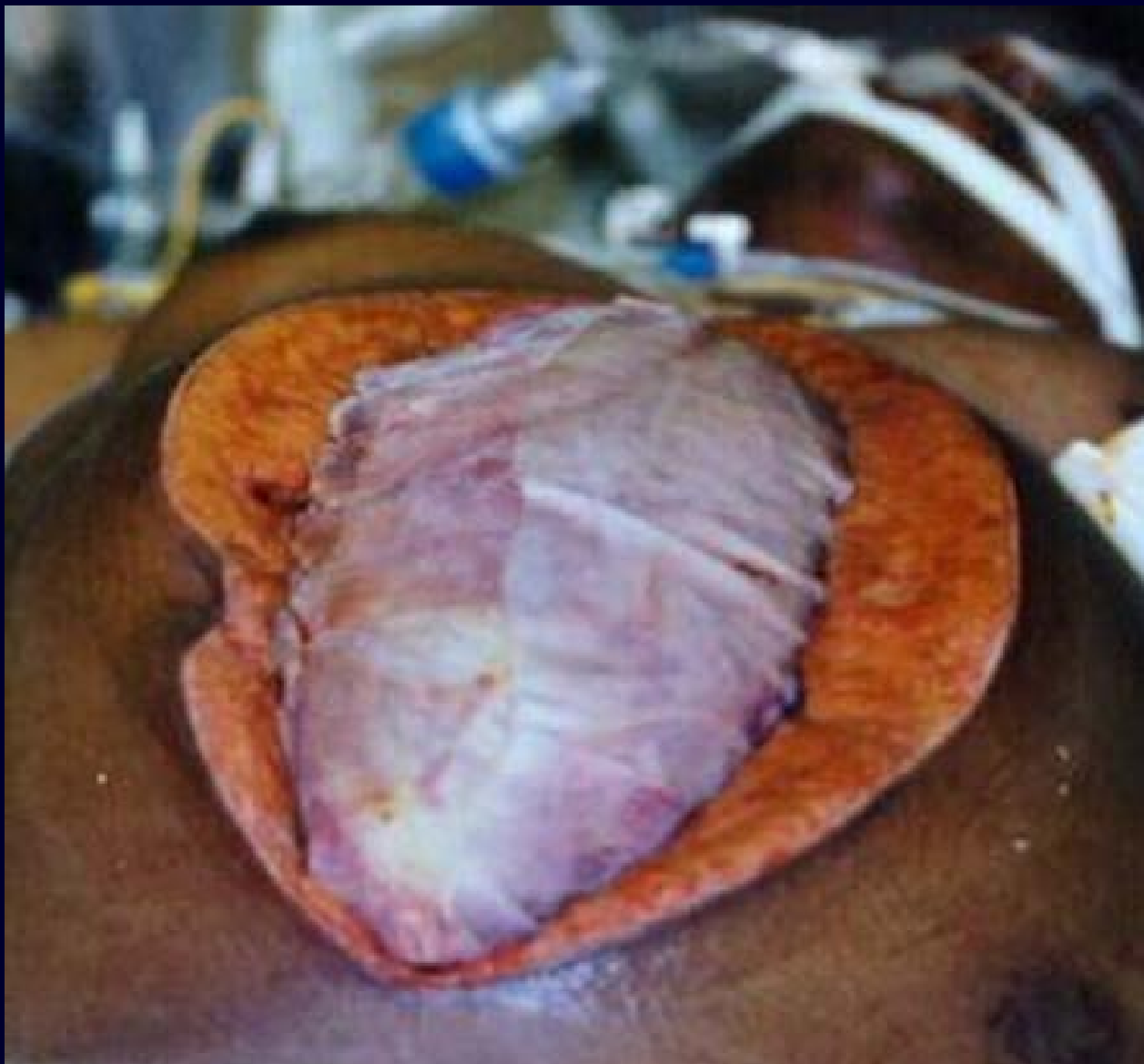
Gore-Tex 2-mm mesh is sewn to itself and to the skin or fascia (as in this case) to achieve temporary closure.



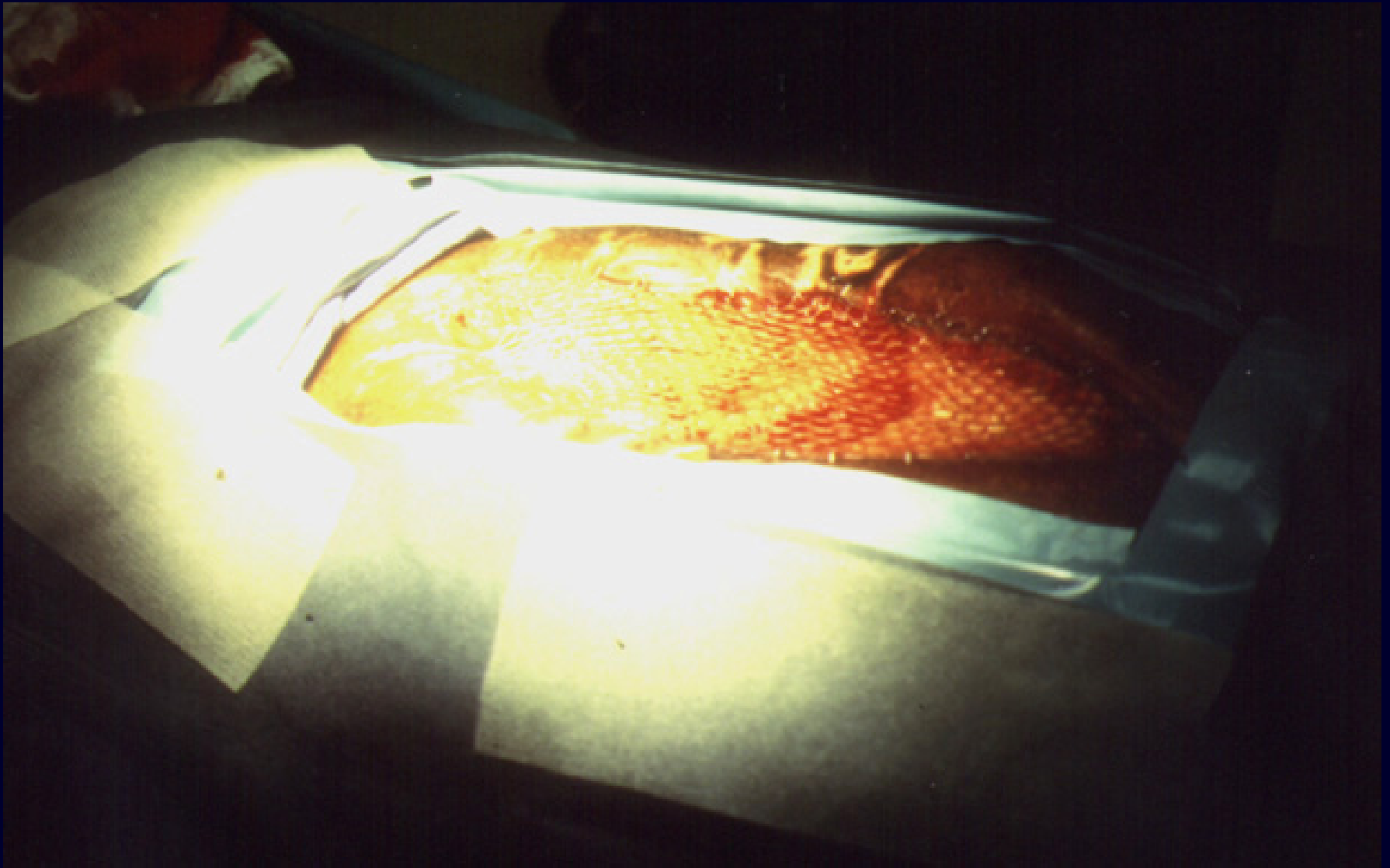
Marlex mesh is sewn to itself and to the fascia.



Either a conventional zipper or a commercial zipper is sewn to the skin or fascia with a continuous suture of 0 or 2-0 nylon or polypropylene. By using the skin, the fascia is spared and the incidence of postoperative fascial dehiscence may be diminished.

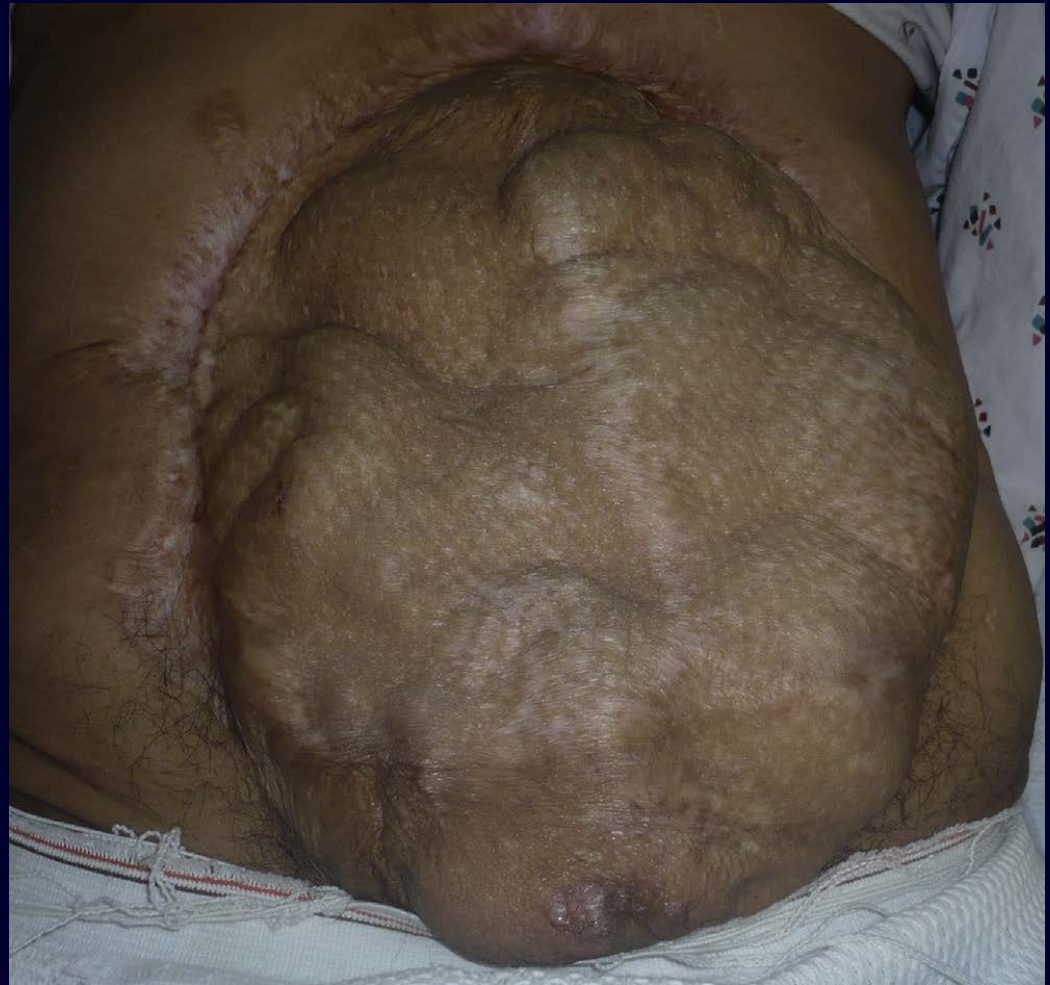

Two sheets of Velcro-like biocompatible material are sewn to the midline fascia. The Velcro-like material can be adjusted to accommodate increased intra-abdominal pressure (IAP), or, as the IAP decreases, it may be trimmed and the incision approximated accordingly Wittmann patch.



Dexon absorbable mesh is sewn to the fascia.

Absorbable meshes may be left in place at the closure of the abdomen, whereas nonabsorbable materials usually need to be removed. If fascia or skin closure is not possible, usually because of persistent sepsis, the wound is allowed to granulate and is skin grafted at a later stage.



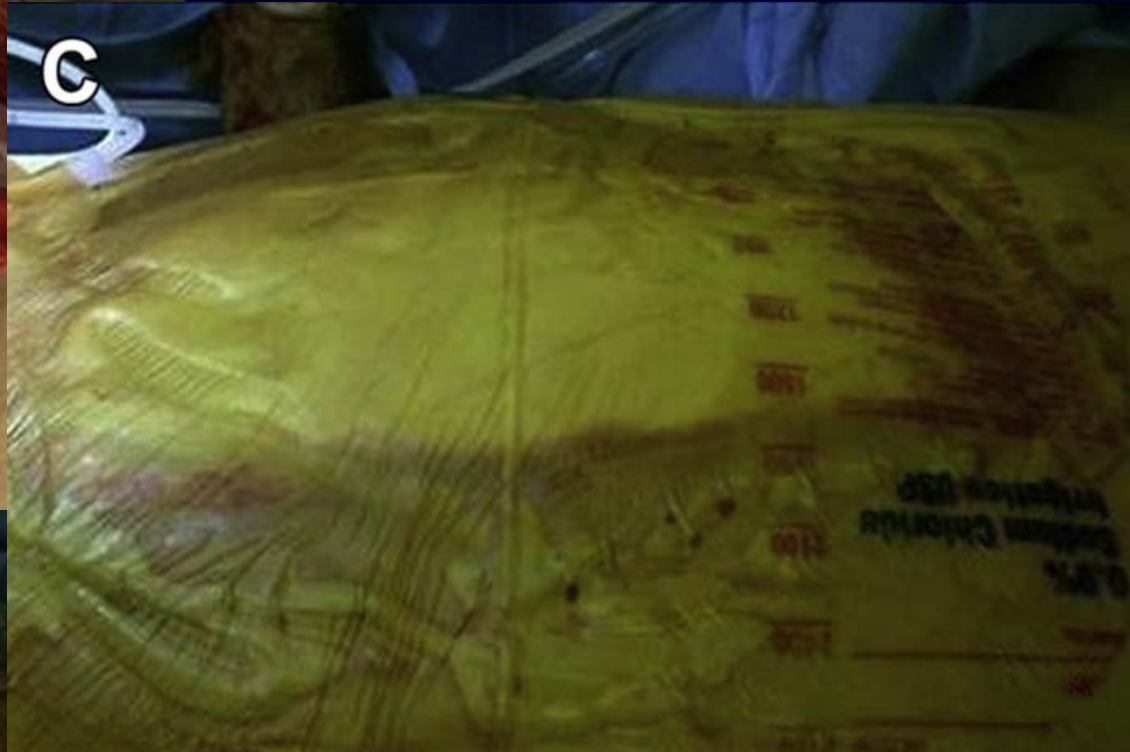
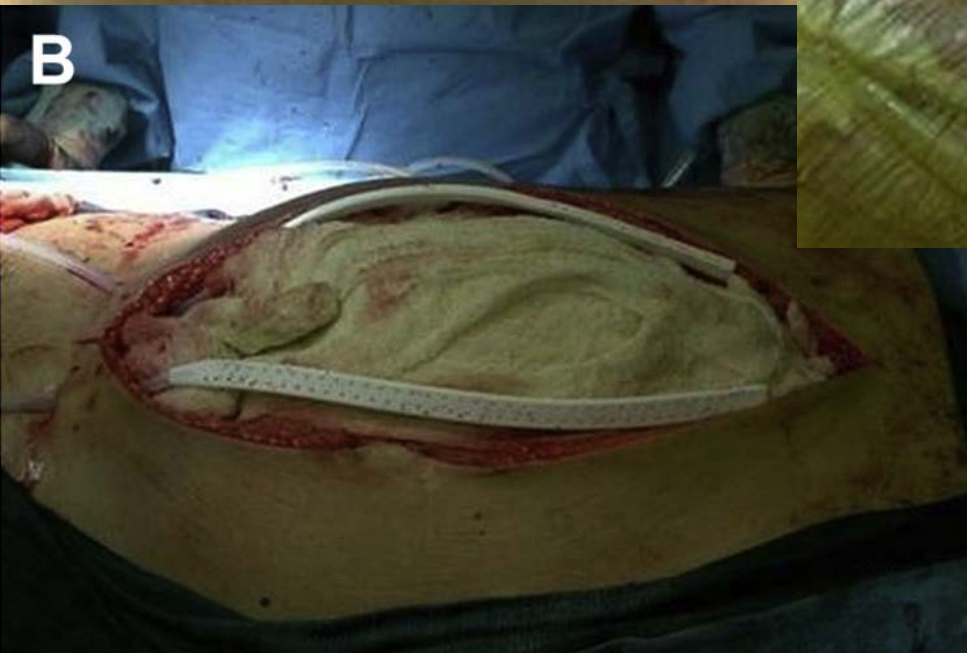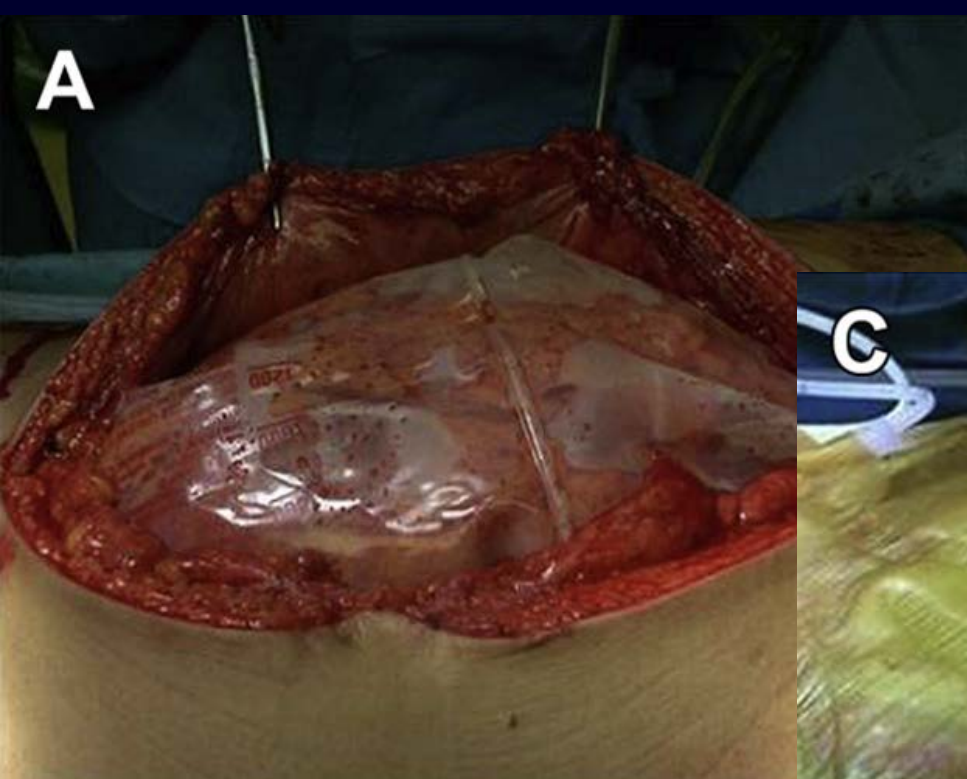Negative pressure techniques

The first negative pressure method for temporary abdominal wall closure was described in South Africa by Schein and colleagues in 1986. The investigators described a sandwich technique composed of Marlex mesh and OpSite closure with suction catheters.

Schein M, et al. Br J Surg 1986;73(5):369–70.

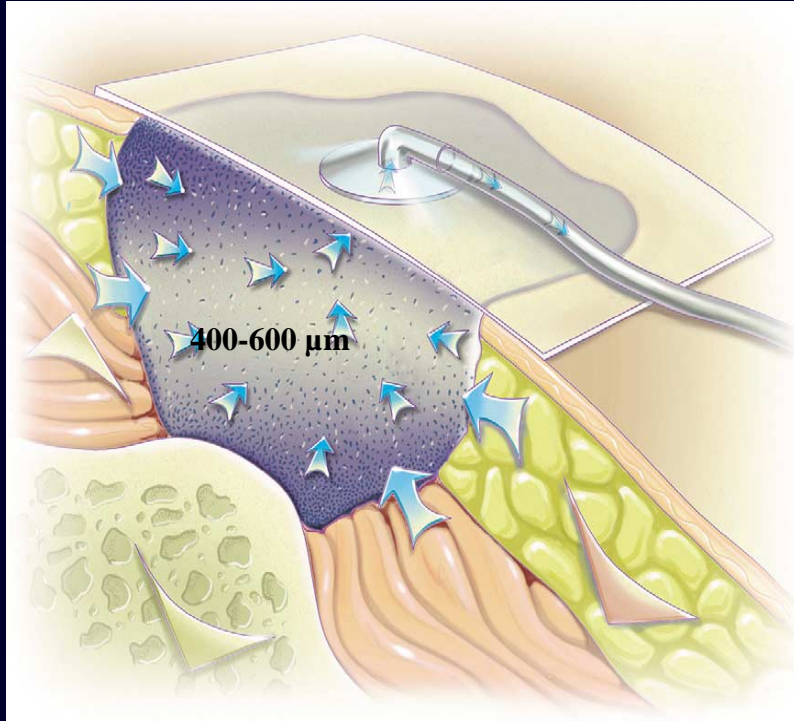
This technique was modified by Barker and colleagues in 1995 and was coined vacuum pack and later the Barker vacuum pack. The technique is simple and easily available. It consists of a fenestrated, nonadherent polyethylene sheet that is placed over the bowel and under the peritoneum, covered by moist surgical towels or gauze, 2 large silicone drains placed over the towels, and a transparent adhesive drape over the wound to maintain a closed seal.

Brock WB, Barker DE, Burns RP. Temporary closure of open abdominal wounds: the vacuum pack. Am Surg 1995;61(1):30–5.



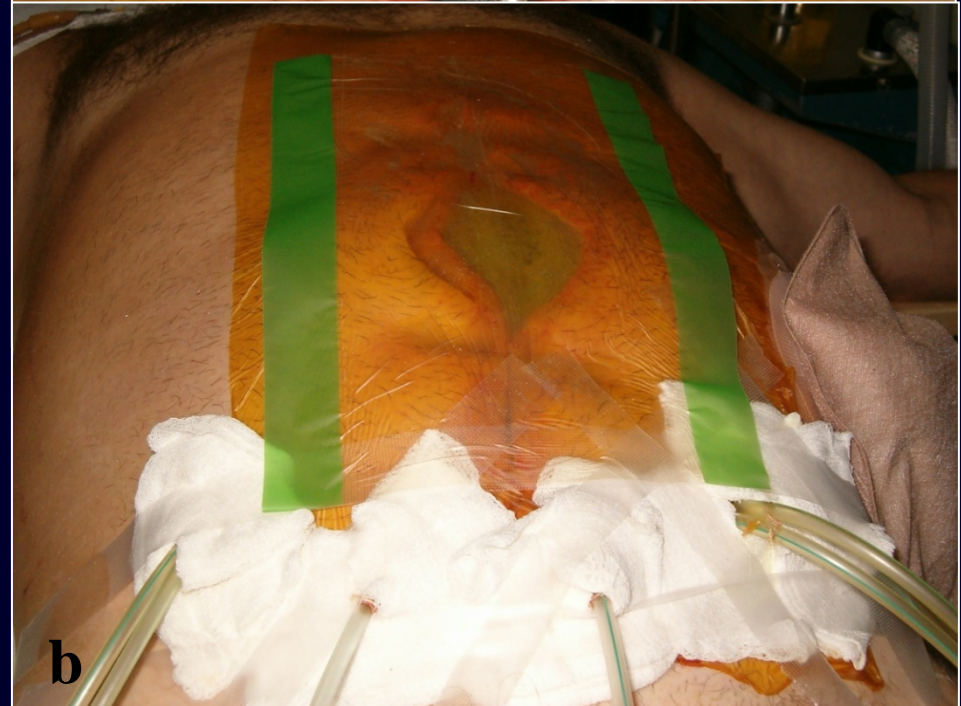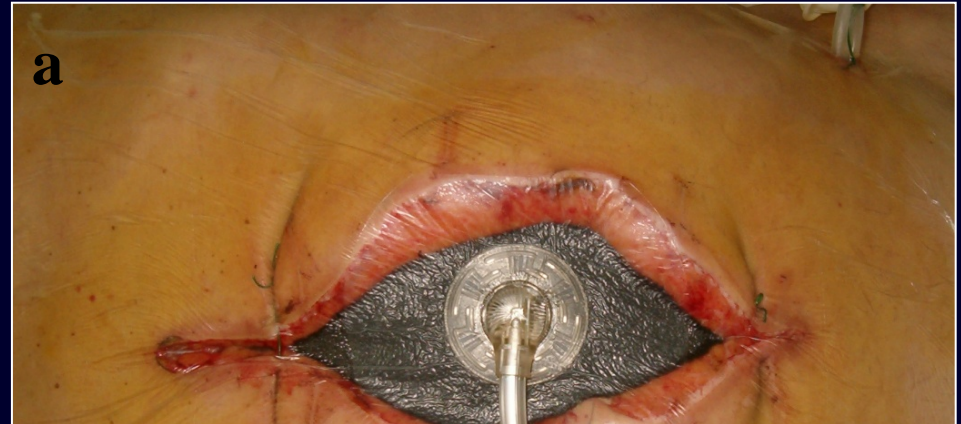Vacuum-pack technique (Barker). A fenestrated, nonadherent sheet is placed over the bowel and underneath the peritoneum (A), followed by moist surgical gauze and 2 drains (B), and then covered with a transparent adhesive dressing (C).

The VAC Abdominal Dressing system (KCI) is a commercially available, sophisticated negative pressure dressing system that includes polyurethane foam covered with a protective, fenestrated, nonadherent layer, tubing, a canister, and a computerized pump



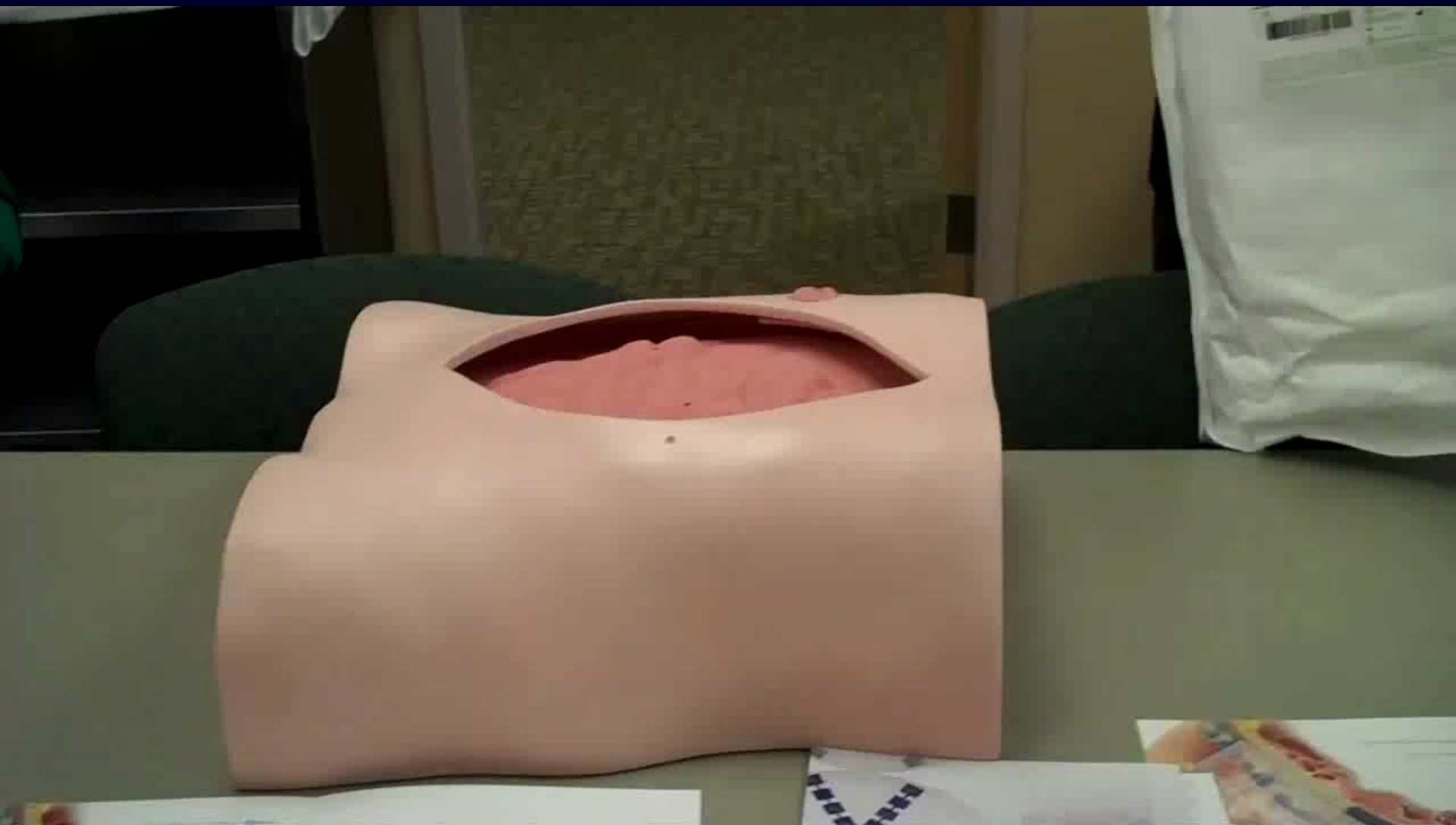
(a) Final view – standard VAC for diffuse secondary peritonitis due to suture leakage.

(b) Final view – home made vacuum closure for diffuse secondary peritonitis due to suture leakage.





V.A.C. KCI system



ABThera KCI system

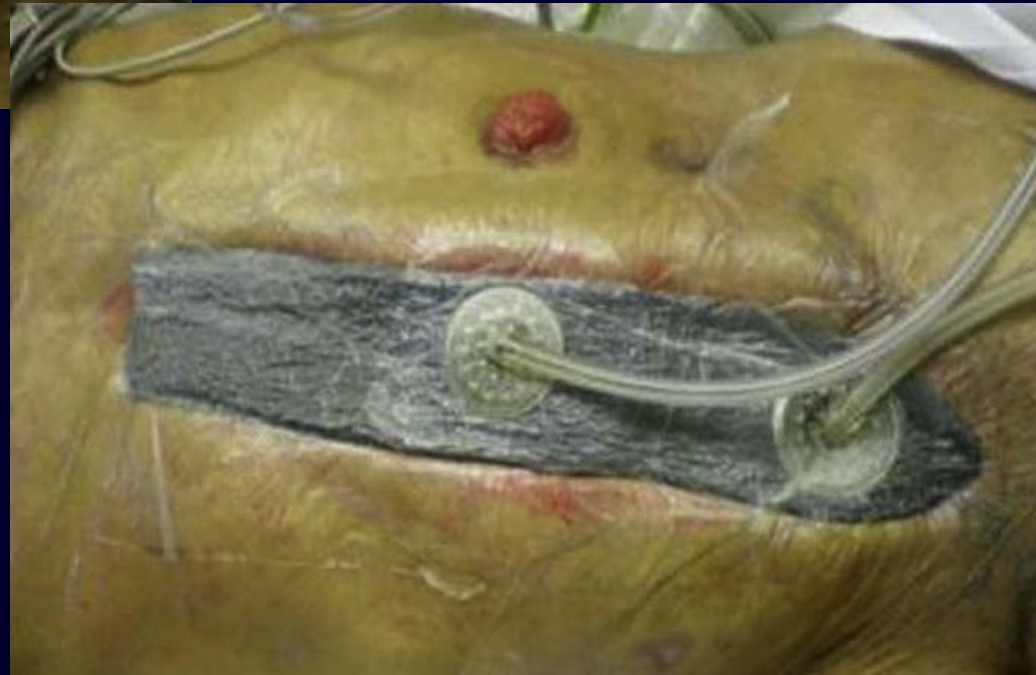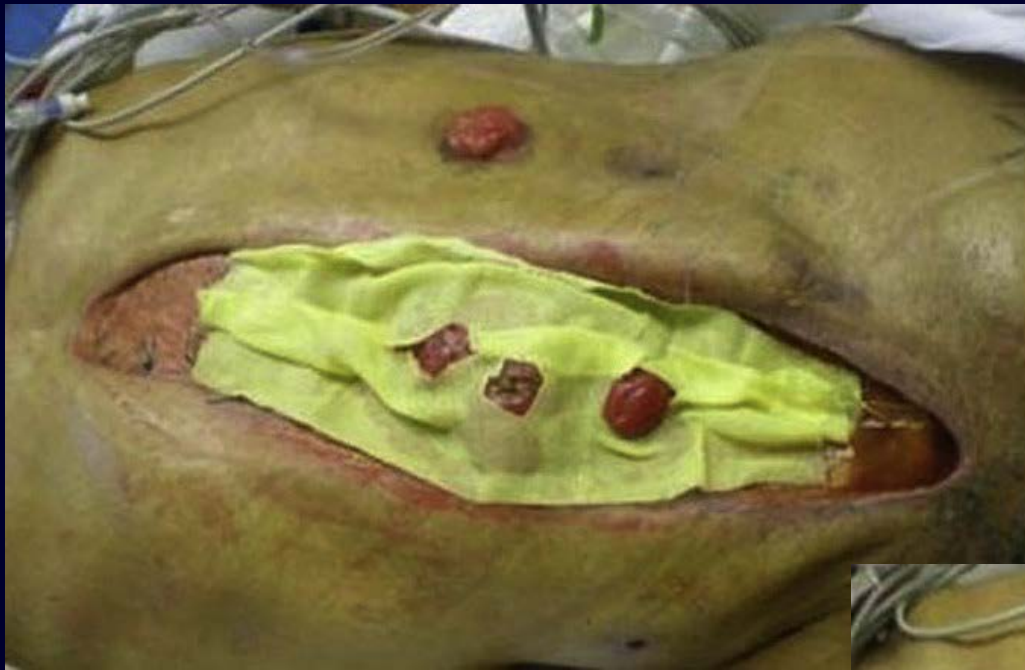ABRA Abdominal wall closure

The development of enteroatmospheric fistulas is the most serious and challenging local complication in an open abdomen. The overall incidence of this complication is about 5%. However, in the chronically open abdomen, the incidence increases to about 15%. The exposed bowel is at risk of fistulization if the abdomen remains open for longer than 5 to 7 days, especially in the presence of synthetic meshes or infection. There is an ongoing debate whether the use of NPT increases the risk of fistulization. Although some small retrospective studies expressed concern about the possibility of increased risk of enteroatmospheric fistulas with NPT, other studies showed no increased risk. The issue is still unresolved and better studies are needed to address this concern.

**Barker DE, et al. J Trauma 2000; 48(2):201–6 [discussion: 206–7].
Smith LA, et al. Am Surg 1997;63(12):1102–7 [discussion: 1107–8].
Teixeira PG, et al. Am Surg 2009;75(1):30–2.**

The most effective way of preventing this catastrophic complication is early closure of the abdominal wall. The management strategy should include temporary local control to prevent spillage of enteric contents on the surrounding tissues, while planning the definitive closure of the fistula.

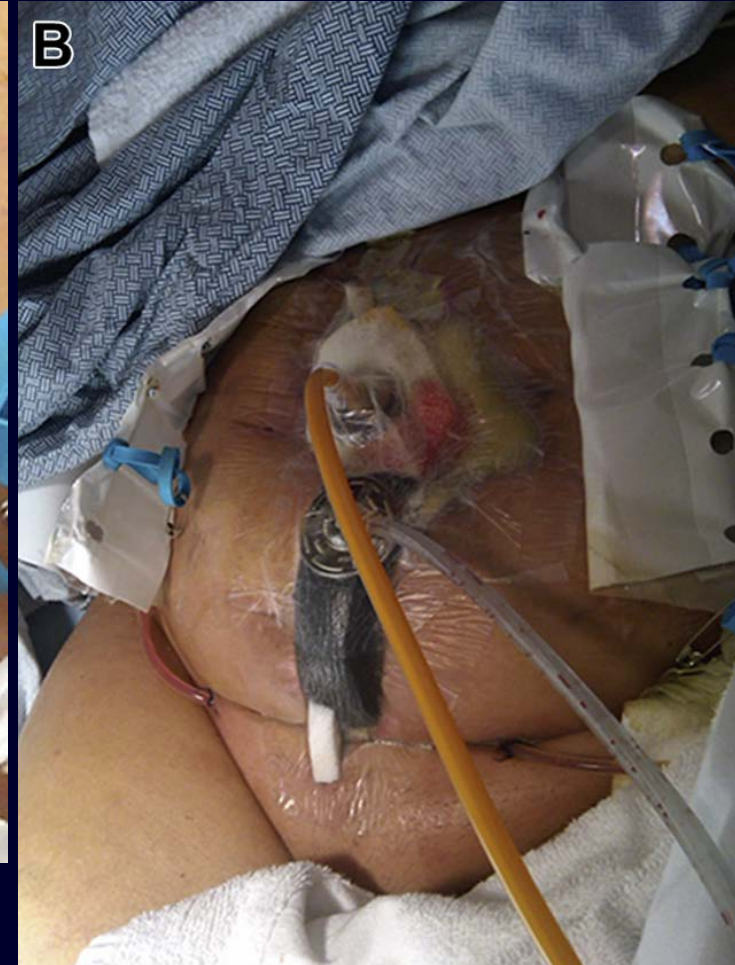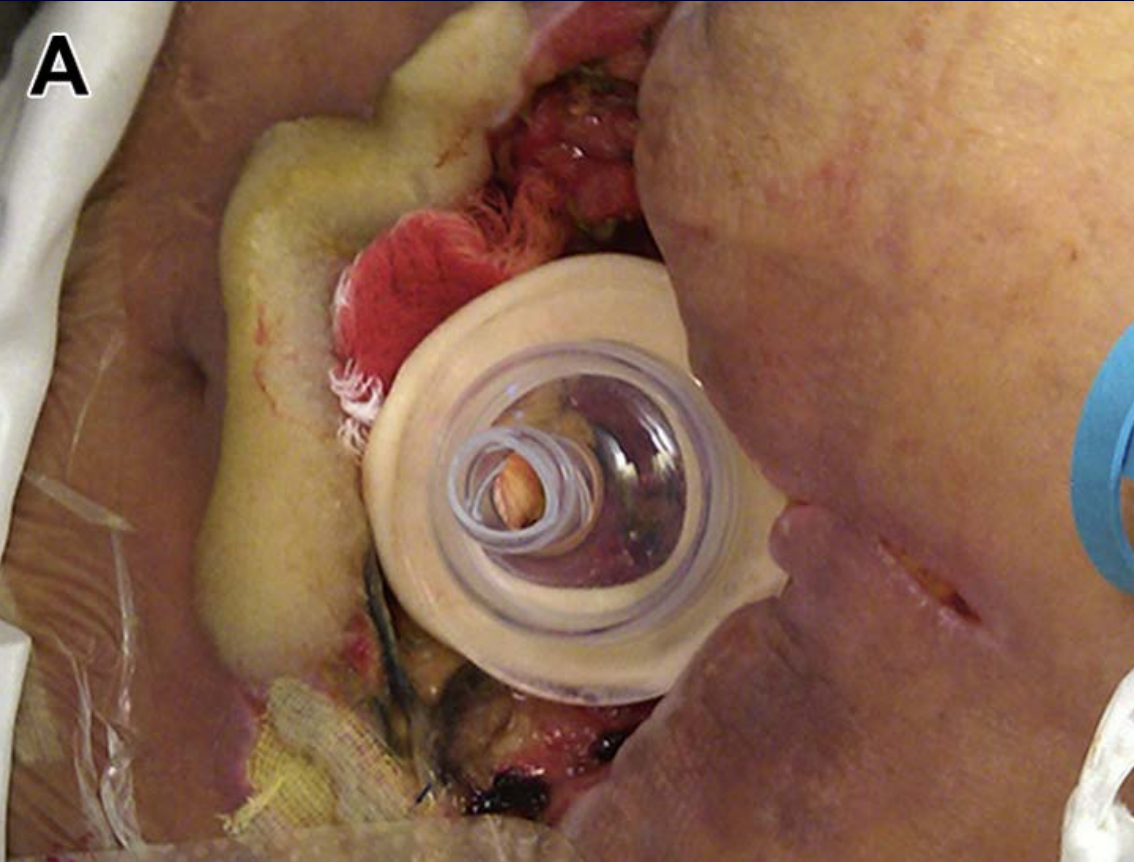
Appropriate use of the VAC system may be helpful in many cases. Sometimes, especially in small fistulas, the negative pressure approximates the edges of the fistula and spontaneous closure may occur, the VAC system may allow a controlled diversion of the fistula contents, protect the surrounding open abdomen and normal skin, and provide comfort to the patient from the chemical dermatitis pain, odor, and soilage.



Local control of enteroatmospheric fistula with liquid contents, using the VAC technique

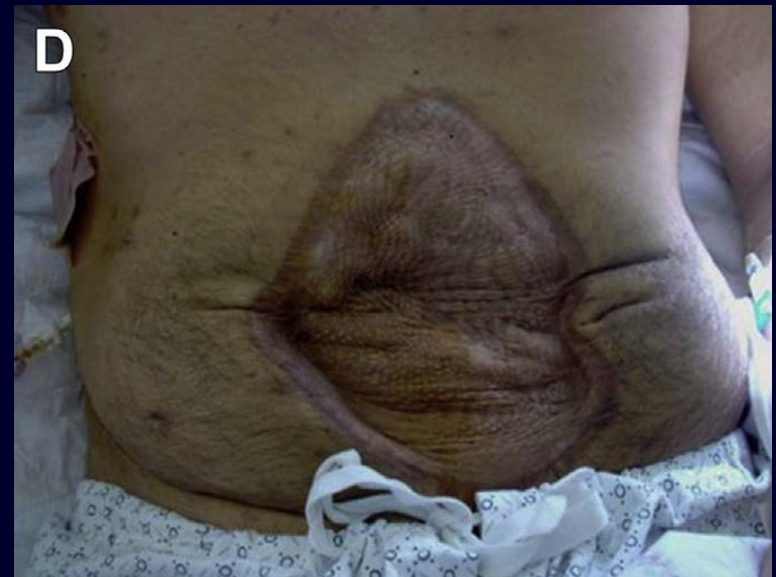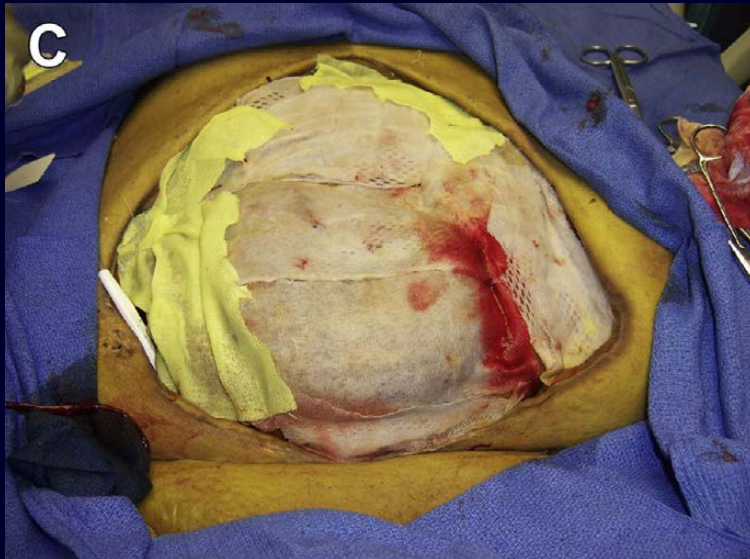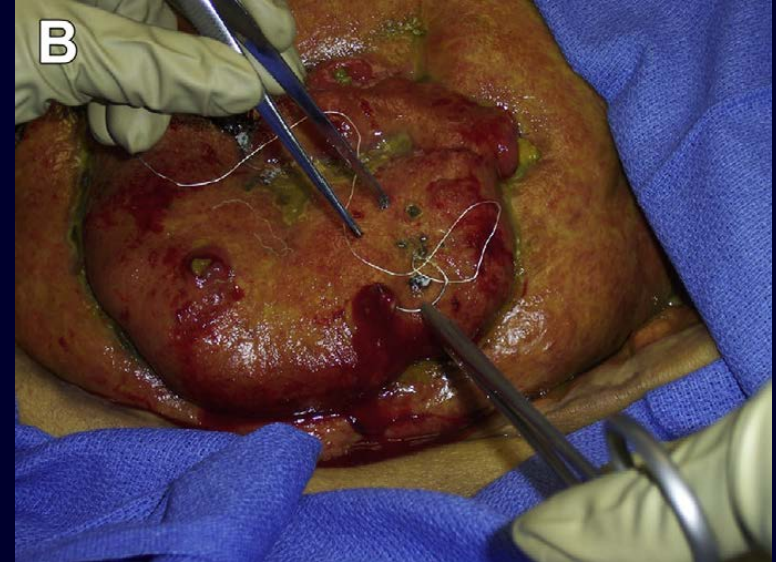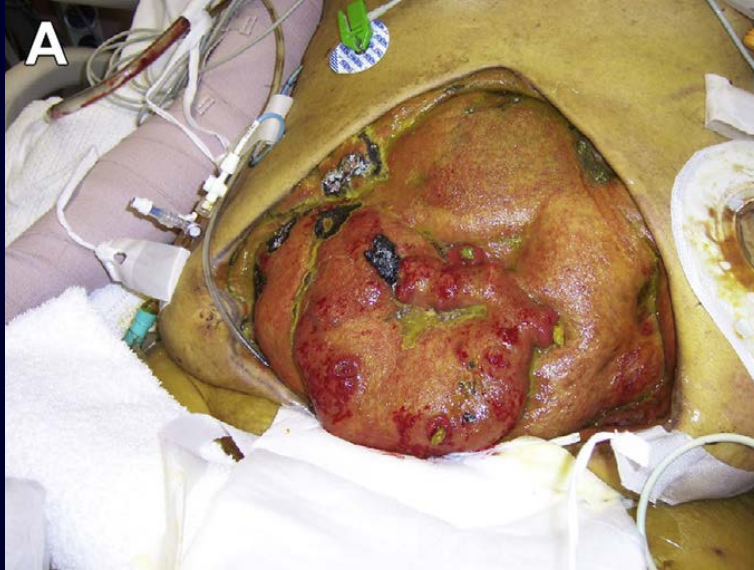Another method described to control fistulas with watery output is the nipple technique. This technique uses a standard baby bottle nipple of latex or silicone over the fistula.

Layton B, et al. Am J Surg 2010;199(4):e48–50.



The nipple technique (A, B) may be useful in selected enteroatmospheric fistulae with liquid contents

The operative management of the enteroatmospheric fistulas is a major technical challenge. The options may range from local closure of the fistula to highly complex and risky abdominal exploration and bowel excision.



QUESTIONS?

