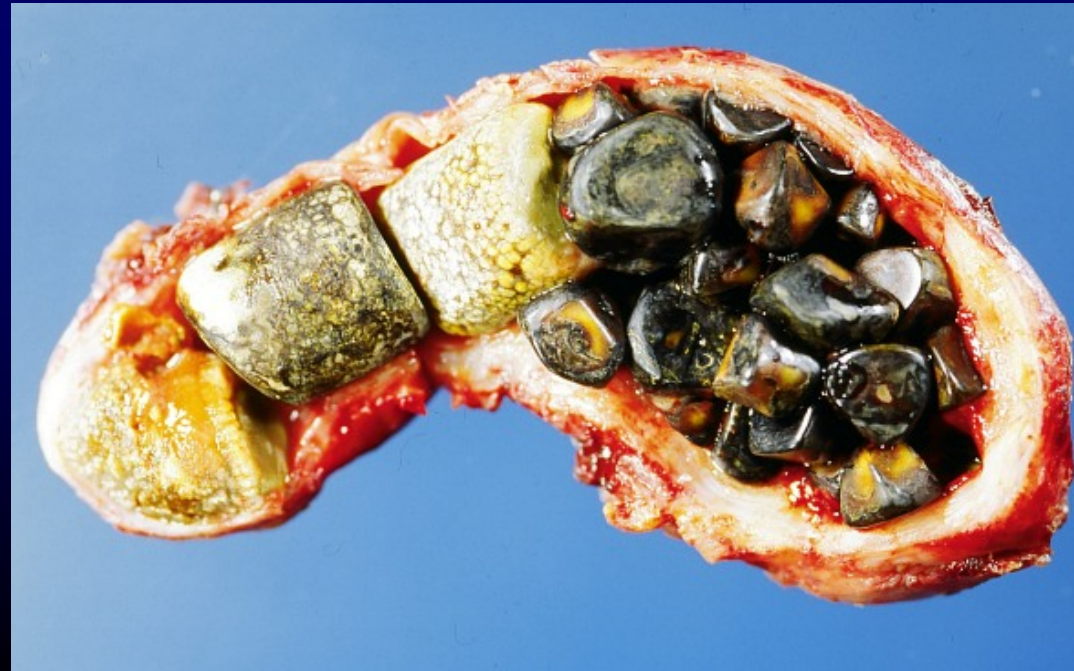

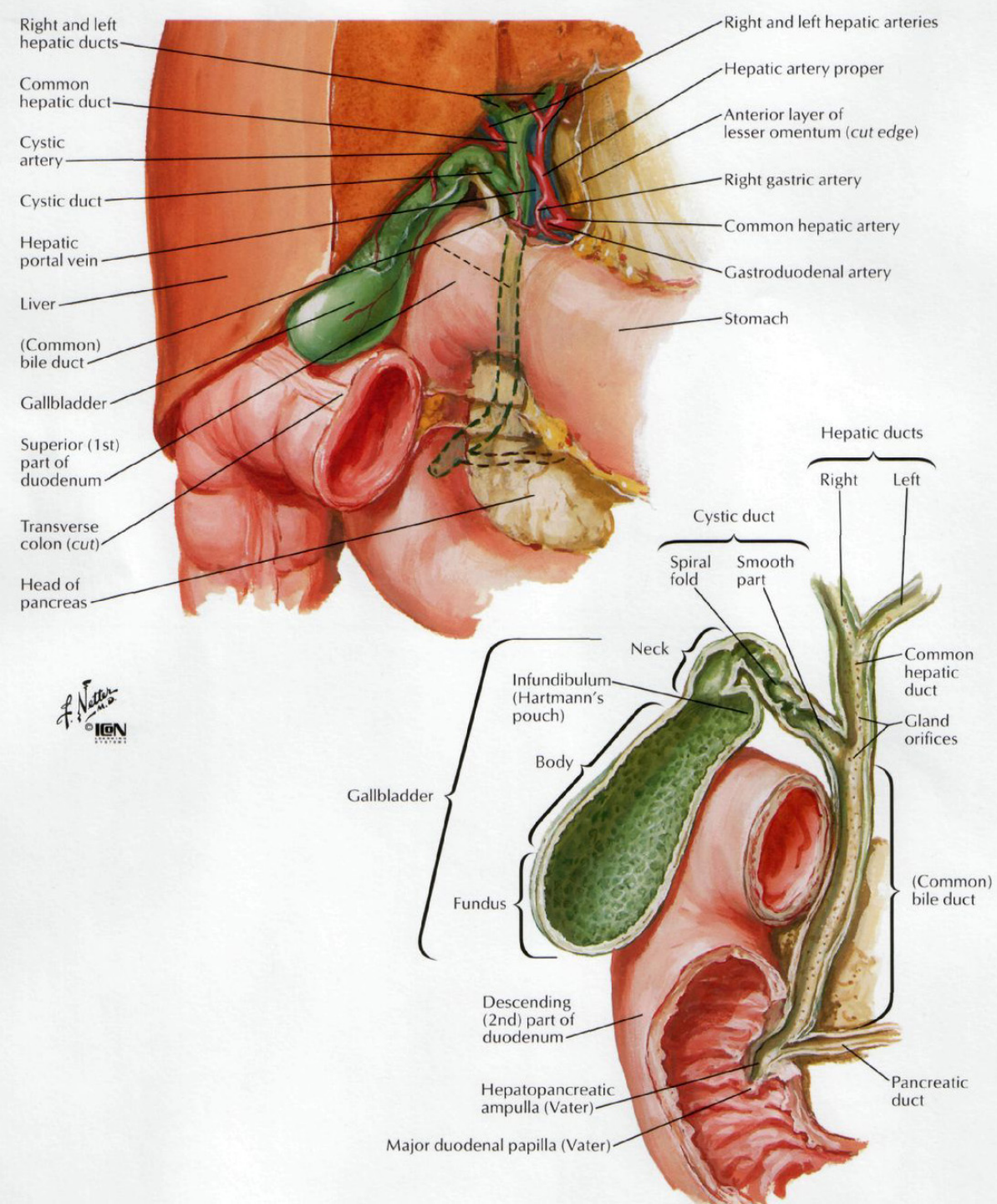
Gallstone Disease

Catedra de Chirurgie nr.1 „Nicolae Anestiadi”

Cholelithiasis (Gallstones)

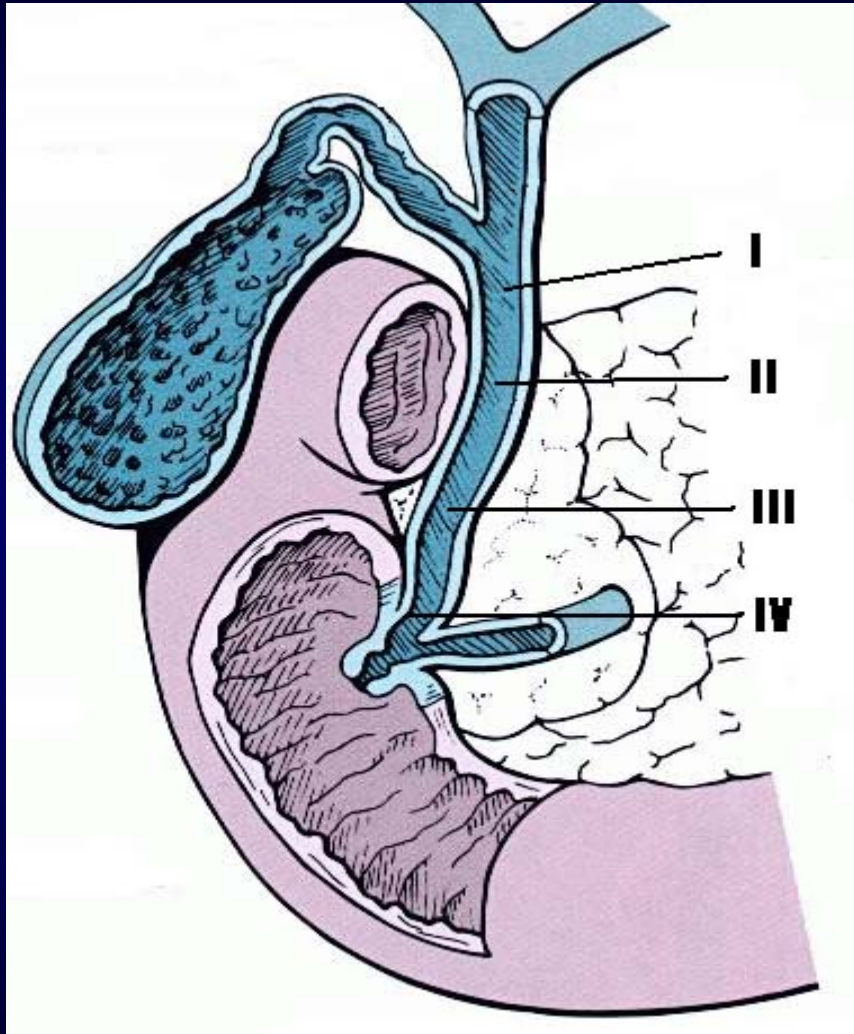
- Gallstone disease, or cholelithiasis, is one of the most common surgical problems worldwide.
- Gallstones are abnormal, inorganic masses formed in the gallbladder and, less commonly, in the common bile or hepatic ducts.
- Women are more likely to develop gallstones than men, with a ratio of 2:1.





ANATOMY AND PHYSIOLOGY

ANATOMY AND PHYSIOLOGY



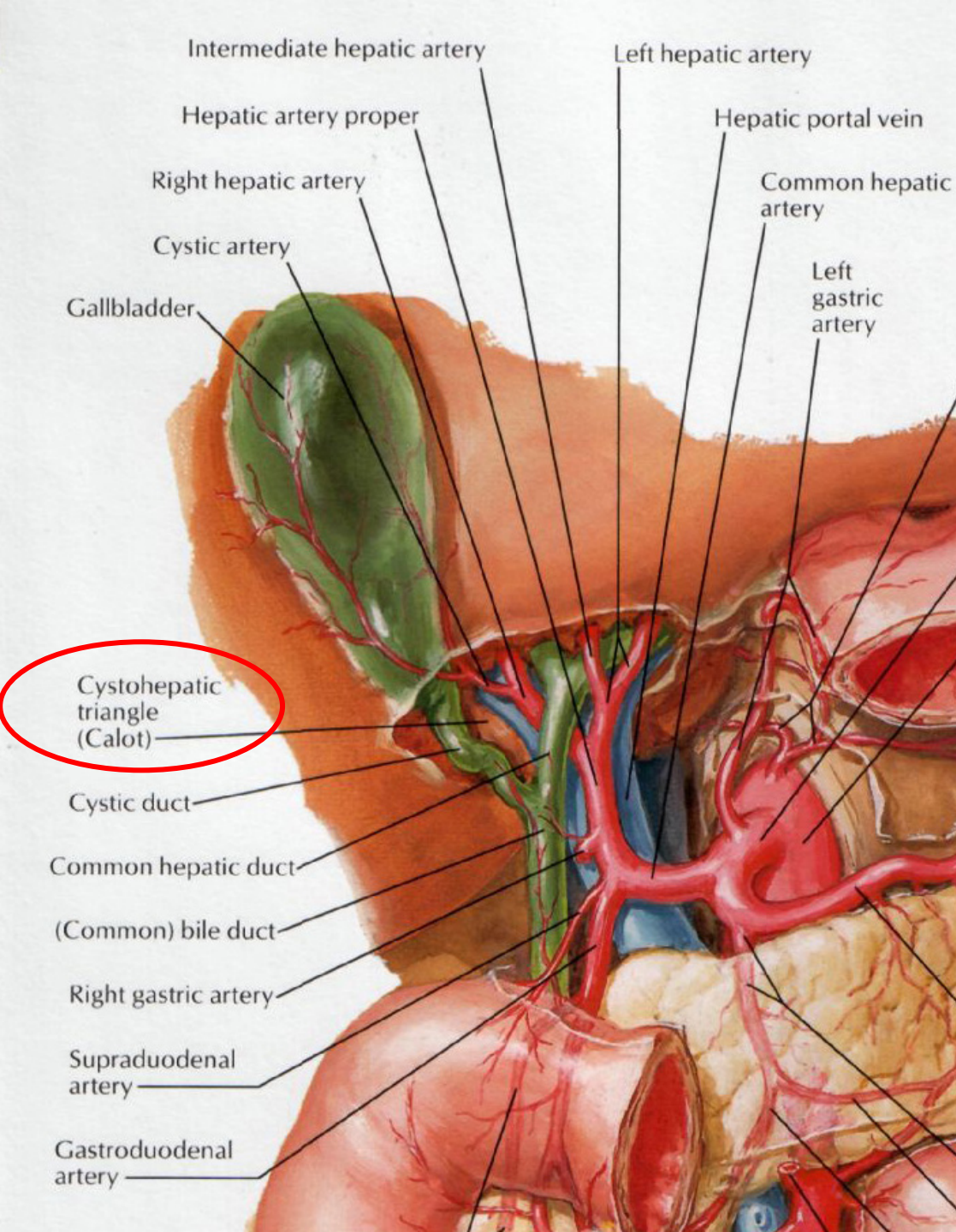
PORTIONS OF THE CBD:

I - SUPRADUODENAL

II - RETRODUODENAL

III – PANCREATIC

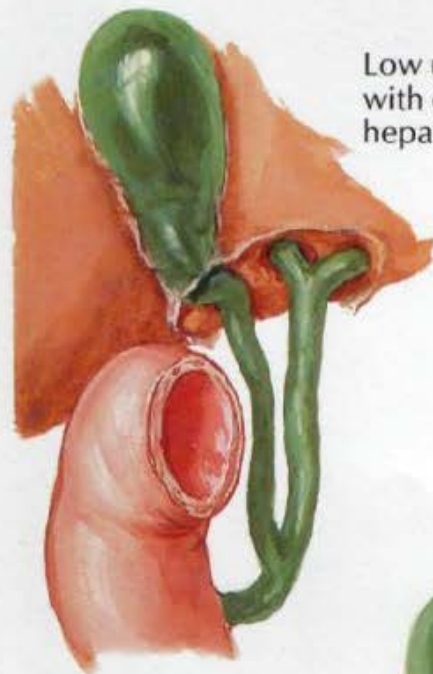IV - INTRAMURAL



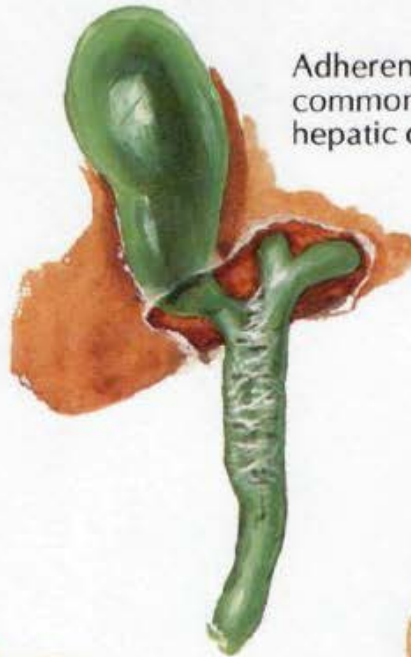ANATOMY AND PHYSIOLOGY

ANATOMY AND PHYSIOLOGY

Variations in cystic duct



Low union
with common
hepatic duct



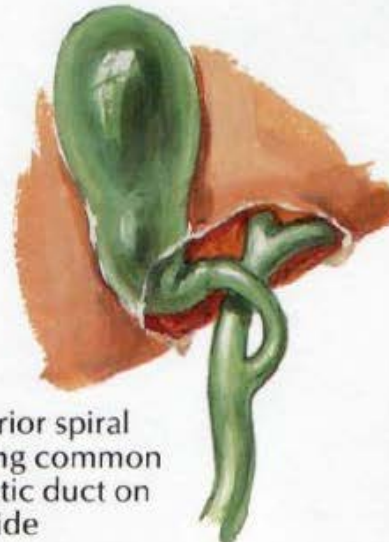Adherent to
common
hepatic duct



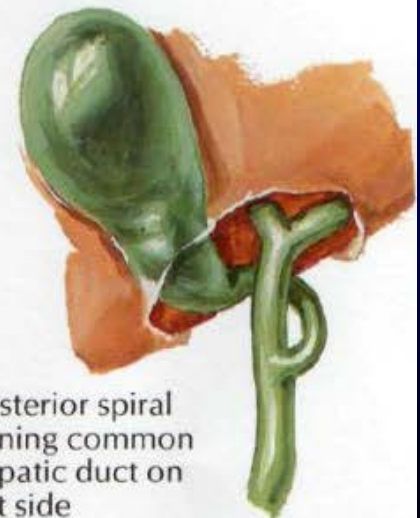High union
with common
hepatic duct



Cystic duct
absent or
very short



Anterior spiral
joining common
hepatic duct on
left side

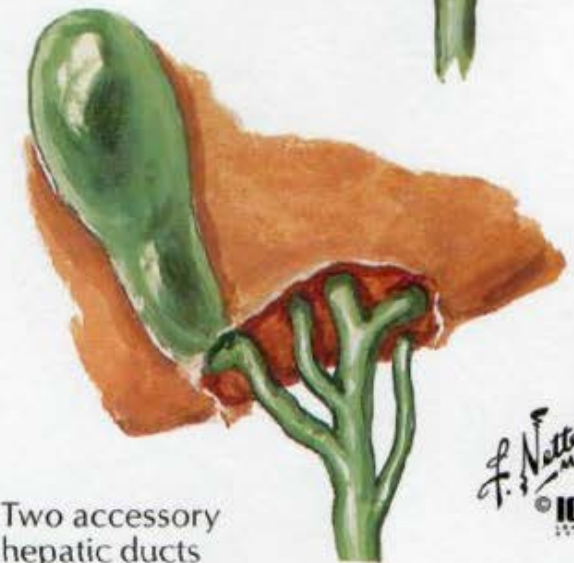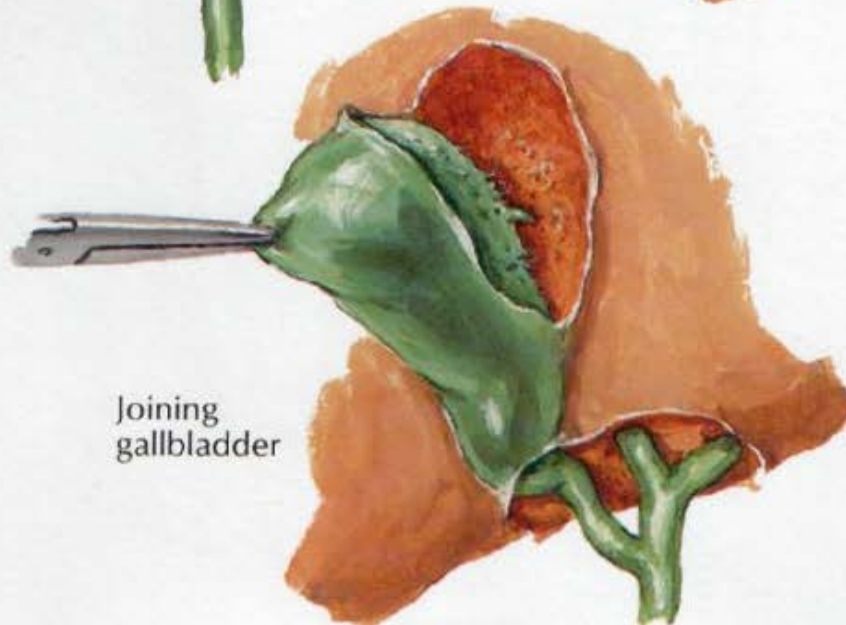

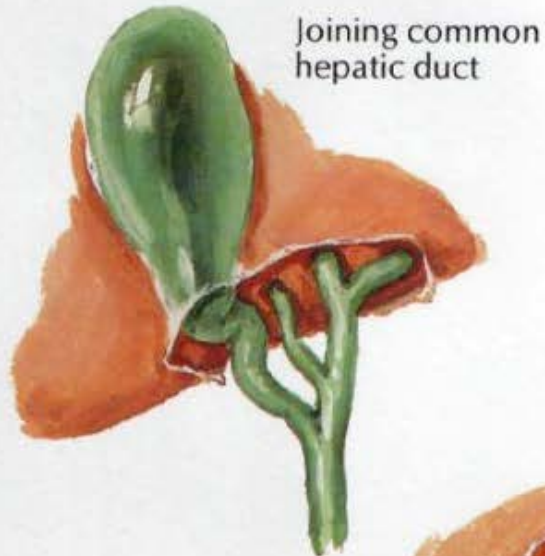


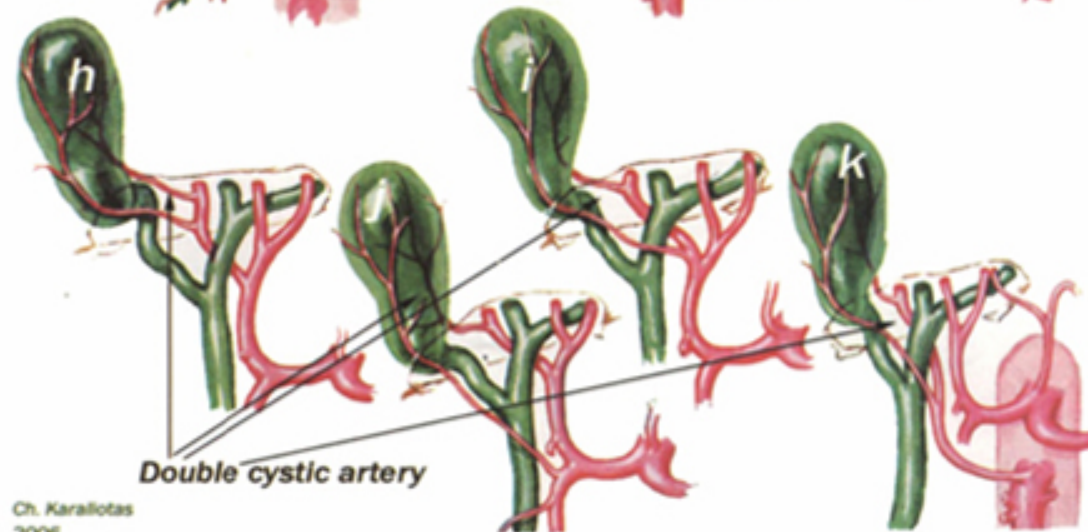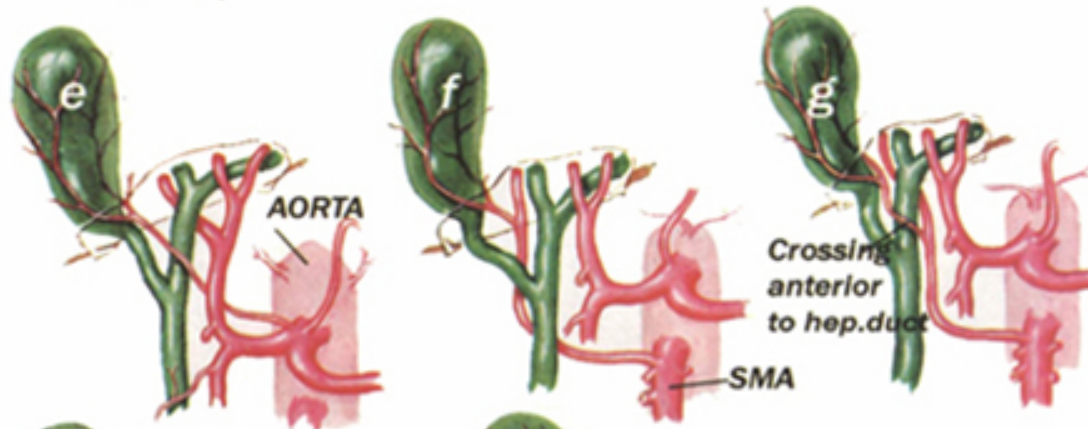
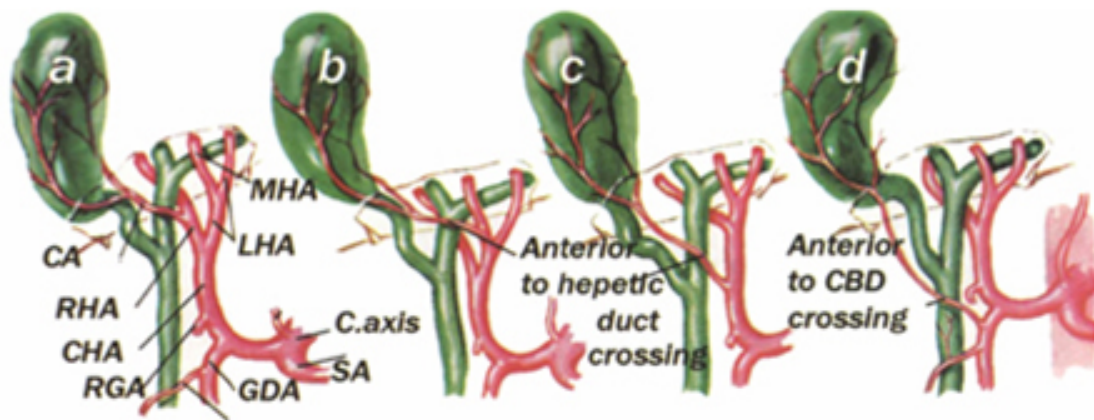
Posterior spiral
joining common
hepatic duct on
left side

ANATOMY AND PHYSIOLOGY

Accessory (aberrant) hepatic ducts

Ducts of Luschka



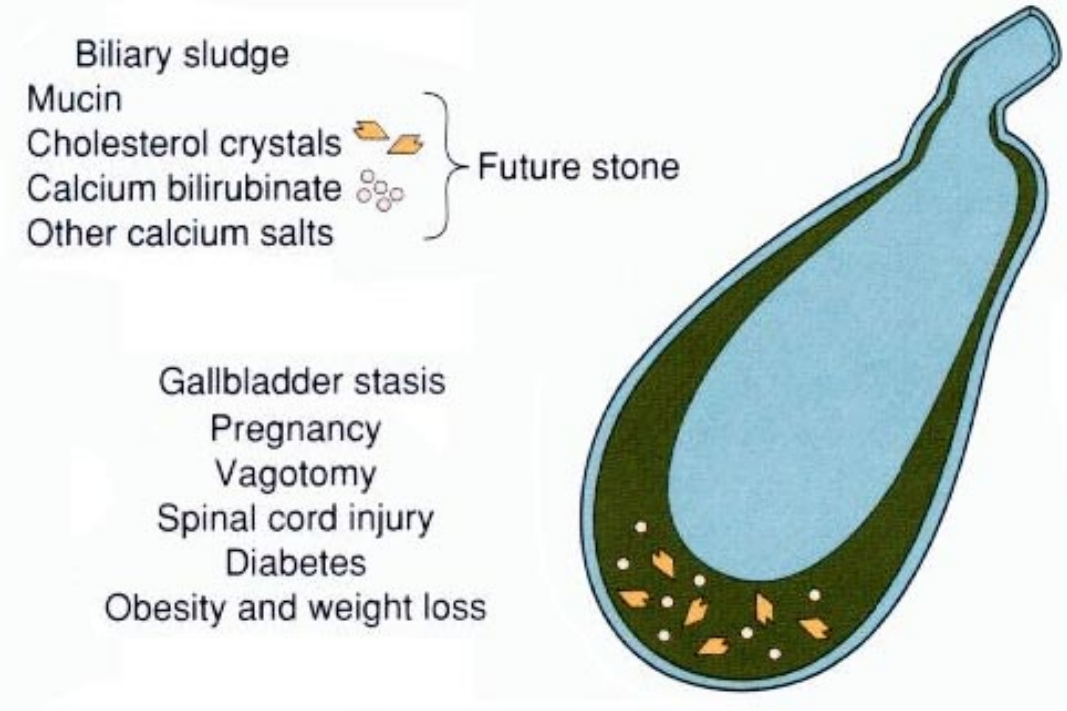


ANATOMY AND PHYSIOLOGY

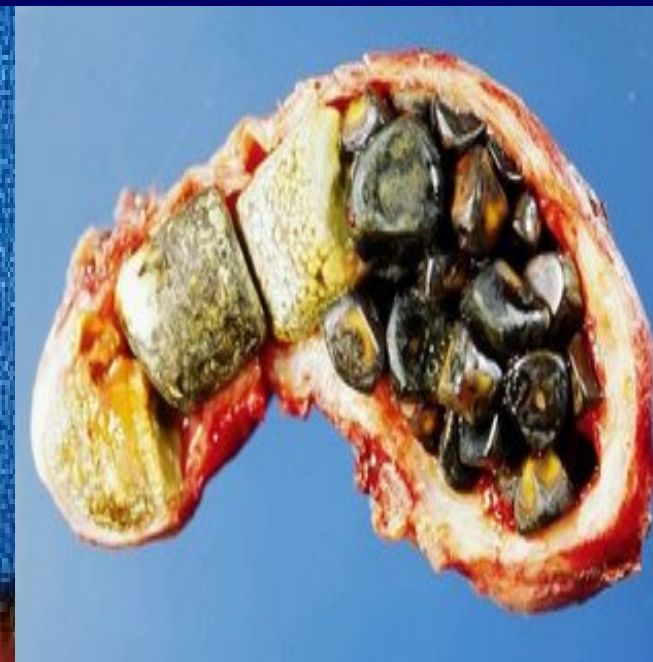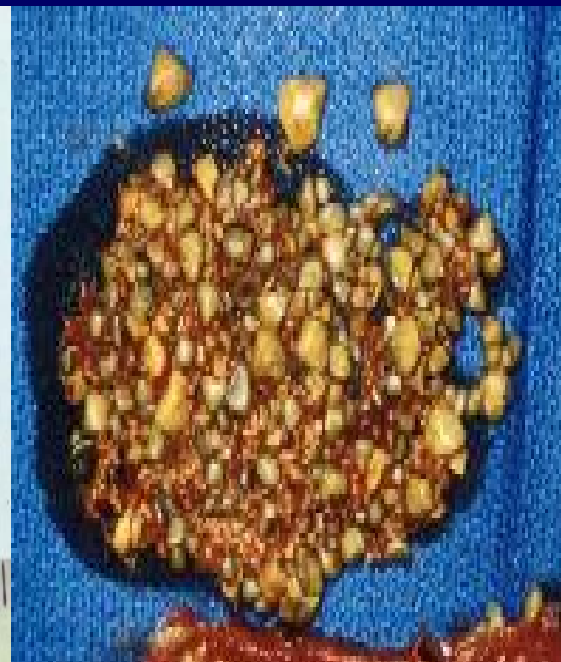Gallstone Pathogenesis

- **Bile = bile salts, phospholipids, cholesterol**
 - Also bilirubin which is conjugated
- **Gallstones due to imbalance rendering cholesterol & calcium salts insoluble**
- **Pathogenesis involves 3 stages:**
 - 1. cholesterol supersaturation in bile
 - 2. crystal nucleation
 - 3. stone growth

Gallstone Pathogenesis



=



Gallstone Pathogenesis

Pathogenesis of cholesterol gallstones involves:

- 1) cholesterol supersaturation in bile, exceeding their maximum solubilities**
- 2) crystal nucleation,**
- 3) gallbladder dysmotility,**
- 4) gallbladder absorption**

The underlying factors implicated are:

- a) Metabolic factor**
- b) Stasis factor**
- c) Reflux factor**
- d) Infective factor**
- e) Hemolytic factor**

METABOLIC FACTOR

- ❑ The solubility of bile cholesterol depends on the concentration of lithogenic (supersaturated) bile salts and phospholipids (lecithin predominantly) in the bile.
- ❑ Cholesterol is insoluble in aqueous solution.
- ❑ It is dissolved in bile acids into micelles along with phospholipids.
- ❑ The normal ratio of bile acid to cholesterol is 25:1.
- ❑ When this ratio falls to 13:1, the cholesterol precipitates and gallstone forms.

BILE STASIS FACTOR

- ❑ Temporary cessation of bile flow into intestine and stagnation of bile in the gallbladder has incriminated a major factor in producing gallstones.
- ❑ Bile flow interruption → Impairs enterohepatic circulation → decrease output of bile salts and phospholipids → reduce solubility of cholesterol → gallstone formation.

TYPES OF GALL STONES

1. CHOLESTEROL STONES

Consist of almost entirely cholesterol (cholesterol solitaire)

2. PIGMENT STONES

Composed almost entirely of calcium bilirubinate. They are mostly small, black and multiple. Some are hard and coral like, others are soft and really concretions of sludge rather than stones

2. MIXED STONES

Cholesterol is the major component. Other components includes calcium bilirubinate, calcium palmitate, calcium carbonate, calcium phosphate and proteins. They are usually multiple and often they are faceted.

Definitions

Symptomatic cholelithiasis	Wax/waning postprandial epigastric/RUQ pain due to transient cystic duct obstruction by stone, no fever/WBC, normal LFT
Acute cholecystitis	Acute GB inflammation due to cystic duct obstruction. Persistent RUQ pain +/- fever, ↑WBC, ↑LFT, +Murphy's = inspiratory arrest
Chronic cholecystitis	Recurrent bouts of colic/acute chol'y leading to chronic GB wall inflamm/fibrosis. No fever/WBC.
Acalculous cholecystitis	GB inflammation due to biliary stasis(5% of time) and not stones(95%). Seen in critically ill pts
Choledocholithiasis	Gallstone in the common bile duct (primary means originated there, secondary = from GB)
Cholangitis	Infection within bile ducts usu due to obstrux of CBD. Charcot triad: RUQ pain, jaundice, fever (seen in 70% of pts), can lead to septic shock

CLINICAL FORMS

- **PAINFUL FORM (SYMPTOMATIC, BILIARY COLIC)**
- **LATENT OR ASYMPTOMATIC FORM**
- **DYSPEPTIC FORM**
- **RECURRENT FORM**
- **CARDIAC FORM (SYMPTOME OF BOTKIN)**

Symptomatic cholelithiasis

- aka “biliary colic”
- The pain occurs due to a stone obstructing the cystic duct, causing wall tension; pain resolves when stone passes
- Pain usually lasts 1-5 hrs, rarely > 24hrs

It can cause intense pain, appearing as a sharp cramp just under the right ribcage, which recurs and subsides. In some cases, the pain will shoot into the right shoulder or back, often :

- ✓ pain in the back between the shoulder blades
- ✓ pain under the right shoulder
- Ultrasound reveals evidence at the crime scene of the likely etiology: gallstones
- Exam, WBC, and LFT normal in this case
- Symptomatic cholelithiasis can be a herald to:
 - an attack of acute cholecystitis
 - or ongoing chronic cholecystitis
- May also resolve

Chronic calculous cholecystitis

- **Recurrent inflammatory process due to recurrent cystic duct obstruction, 90% of the time due to gallstones**
- **Overtime, leads to scarring/wall thickening**
- **Treatment: laparoscopic cholecystectomy**

COMPLICATIONS

THREE GROUPS OF COMPLICATIONS OF THE CHOLELITHIASIS:

INFECTIOUS

ACUTE CHOLECYSTITIS

CHOLANGITIS

MECHANICAL

HYDROPS

SECONDARY CHOLEDOCHOLITHIASIS

BILIARY FISTULAS

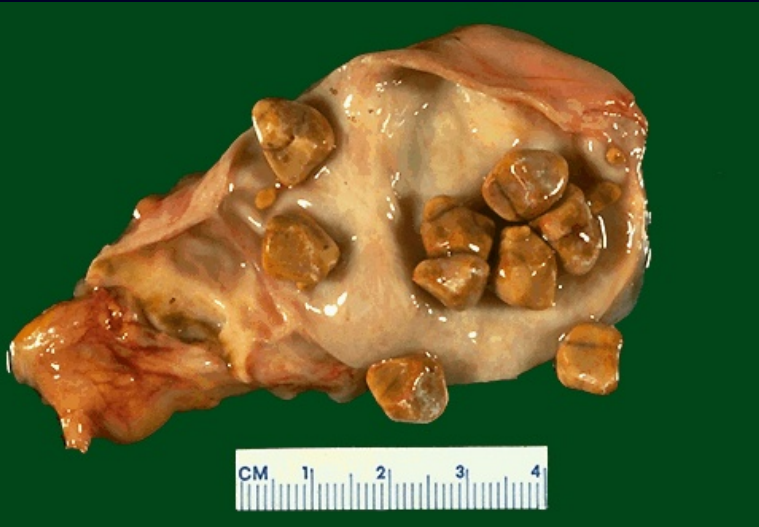GALLSTONE ILEUS

DEGENERATIVE

CBD STRICTURES

CARCINOMA OF THE GALLBLADDER

Acute calculous cholecystitis



- Persistent cystic duct obstruction leads to GB distension, wall inflammation & edema
- Can lead to: empyema, gangrene, rupture
- Pain usu. persists >24hrs & a/w N/V/Fever
- Palpable/tender or even *visible* RUQ mass

CLINICAL SIGNS

MURPHY'S SIGN

ORTNER-GRECOV'S SIGN

MUSSI-GHEORGHIEVSCH'S SIGN

BLUMBERG'S SIGN

MANDEL-RAZDOLSKY'S SIGN

CLASSIFICATION

CATARRHAL

FLEGMONOUS

GANGRENOUS

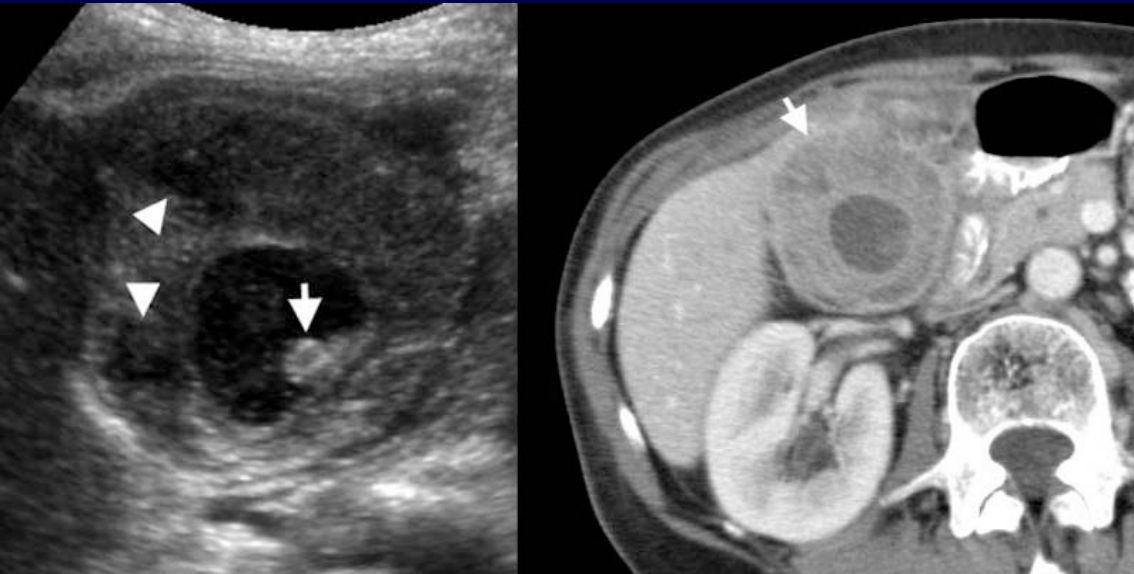
OBSTRUCTIVE FLEGMONOUS
(EMPYEMA OF THE GALLBLADDER)

LABORATORY FINDINGS:

- Full blood pictures- Elevated white blood cell count in 85% of cases. Not elevated in the elderly and those who take anti-inflammatory drugs.
- Liver function test- One half of cases have elevation of serum bilirubin
- Serum amylase- increased in one third of cases.

Acute acalculous cholecystitis

- In 5-10% of cases of acute cholecystitis
- Seen in critically ill pts or prolonged TPN
- More likely to progress to gangrene, empyema, perforation due to ischemia
- Caused by gallbladder stasis from lack of enteral stimulation by cholecystikinin
- **Tx:** Emergent cholecystectomy *usu* open



It was first discovered and reported in the medical literature in 1976 by J.J. McCoy, Jr., and colleagues

Xanthogranulomatous cholecystitis is an uncommon form of chronic cholecystitis, representing between 0.7% and 13.2% of gallbladder disease and mainly affecting women between 60 and 70 years old.

Its importance lies in the fact that clinically and radiologically it can be confused with the carcinoma of the gallbladder.

Complications of acute cholecystitis

Empyema of gallbladder	Pus-filled GB due to bacterial proliferation in obstructed GB. Usu. more toxic, high fever
Emphysematous cholecystitis	<p>Emphysematous cholecystitis, known less commonly as clostridial cholecystitis, is an acute infection of the gallbladder wall caused by gas-forming organisms (eg, <i>Clostridium</i> or <i>Escherichia coli</i>) that is generally considered a surgical emergency. An infrequent, insidious, and rapidly progressive form of acute cholecystitis, emphysematous cholecystitis is characterized by early gangrene, perforation of the gallbladder and high mortality.</p> <p>More commonly in men and diabetics. Severe RUQ pain, generalized sepsis. Imaging shows air in GB wall or lumen</p>
Perforated gallbladder	Occurs in 10% of acute chol'y, usually becomes a contained abscess in RUQ
	Less commonly, perforates into adjacent viscus = cholecystoenteric fistula & the stone can cause SBO (gallstone ileus)

What are the useful imaging modalities to investigate cholecystitis?

- 1.US
- 2.HIDA
- 3.CT
- 4.Four views of abdomen

Indicate the utility of each imaging procedure and when you would select each one:

Ultrasound

- ✓ It should be the first imaging modality used when suspecting cholecystitis.
- ✓ It's non-invasive, fast, easily tolerable by the patient, and reliable in the hands of an experienced operator.
- ✓ It may also be difficult to detect stones in the neck of the gallbladder and cystic duct since the valves of Heister typically show echogenicity with strong shadows mimicking calculi.

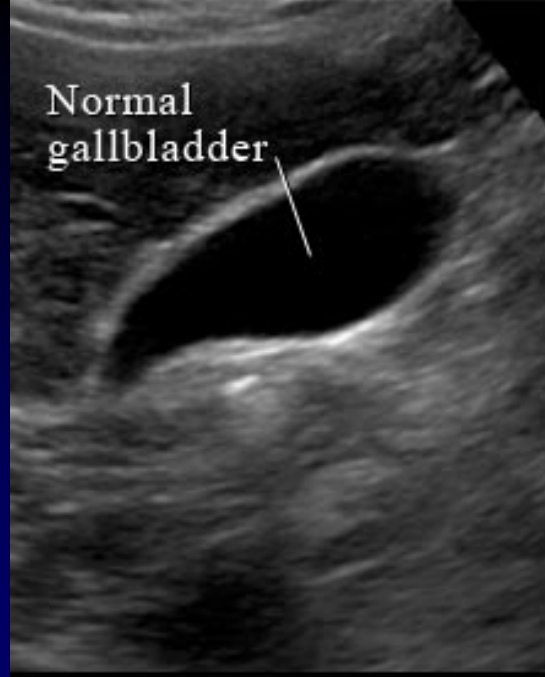
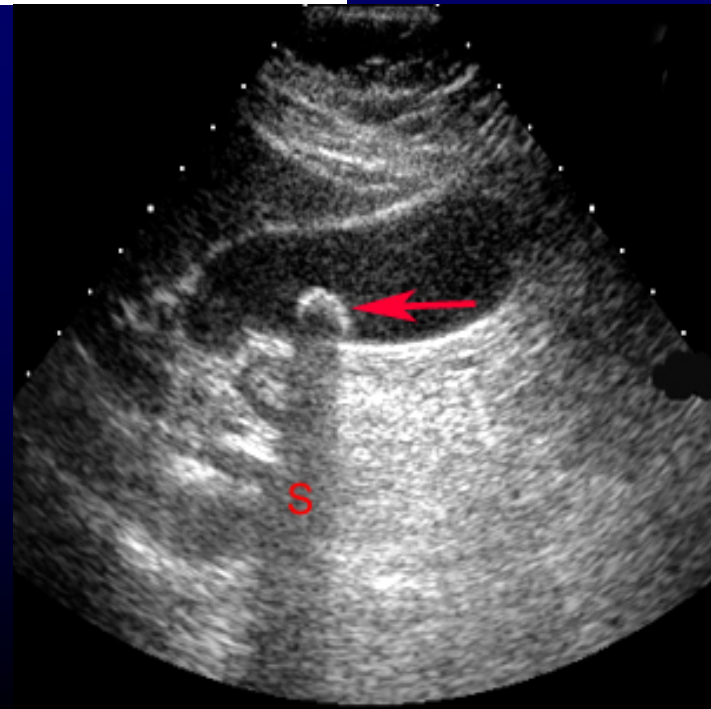
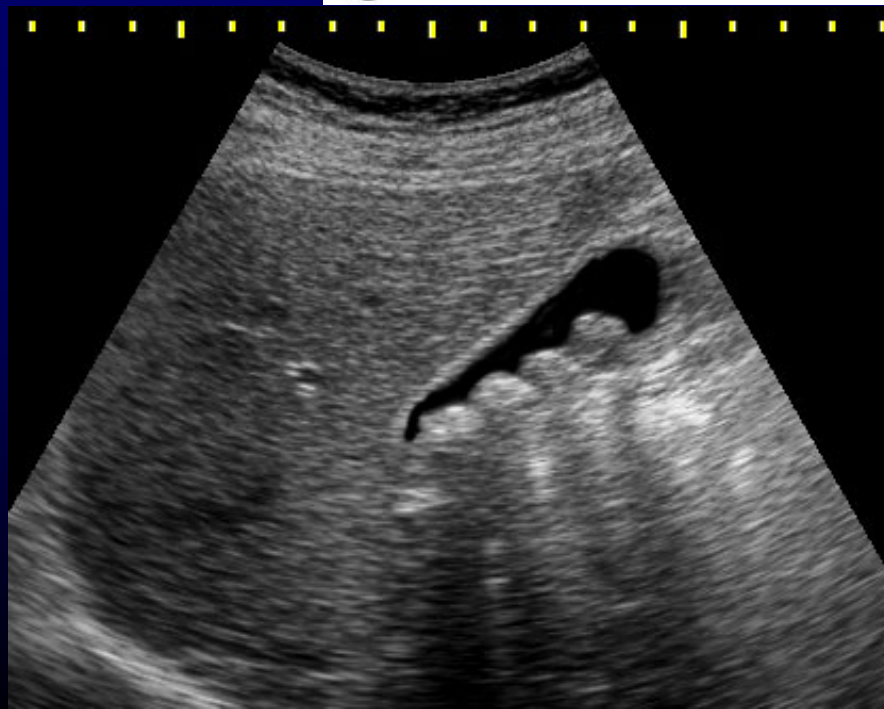


Figure 1

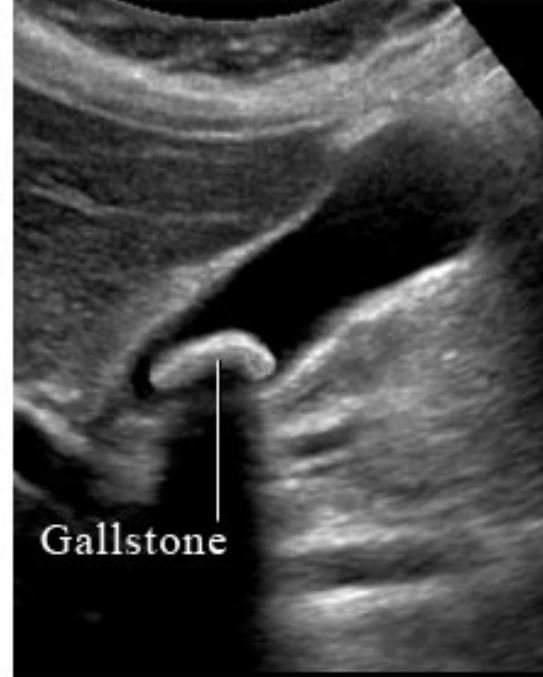

Figure 2



What are the imaging findings of acute cholecystitis in abdominal ultrasound?

Ultrasound findings:

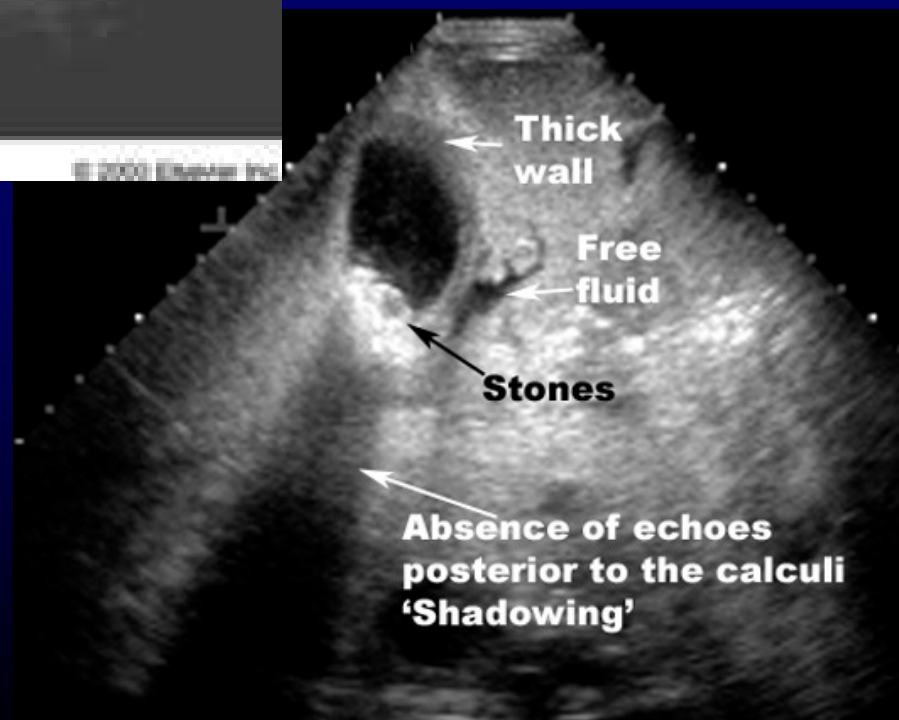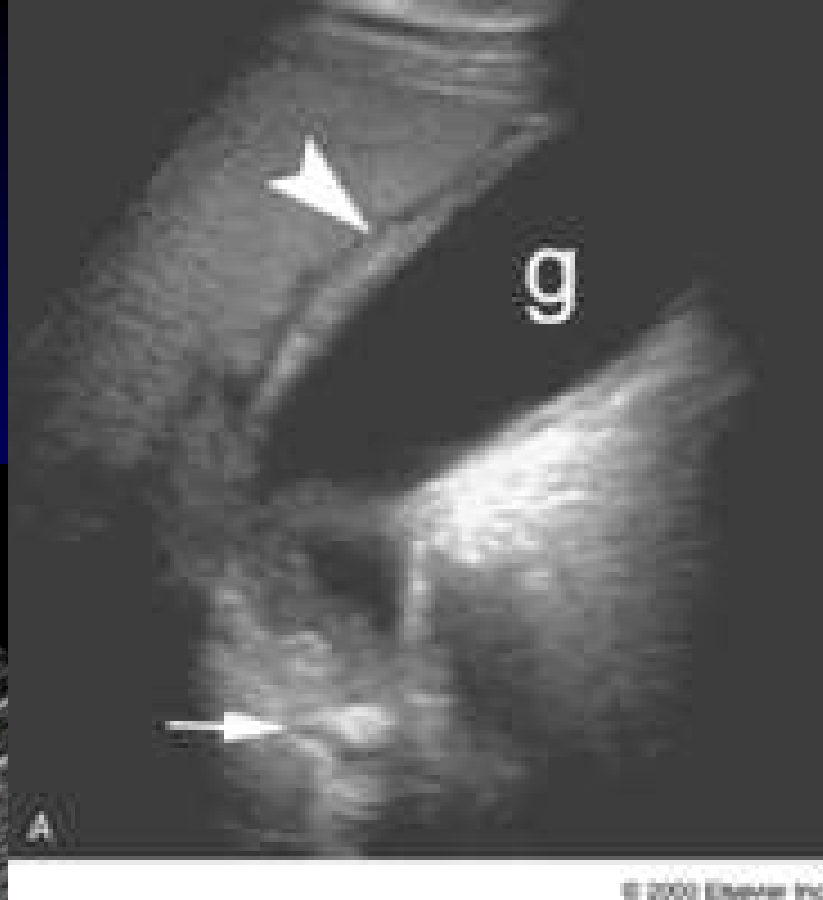
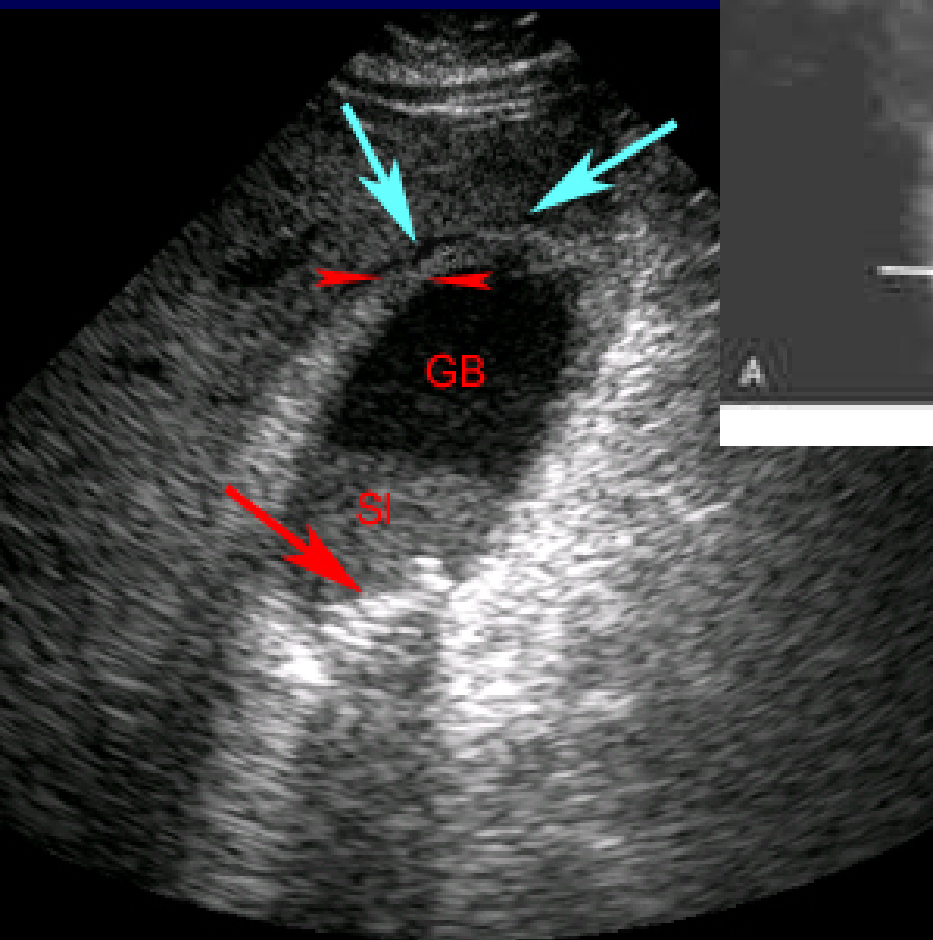
- Thick gallbladder wall - greater than 3 mm
- Stones present in gallbladder
- Pericholecystic fluid
- Sonographic Murphy's sign - tenderness over the gallbladder from the ultrasound transducer

Emphysematous cholecystitis:

- Air in gallbladder
- Air in wall of gallbladder

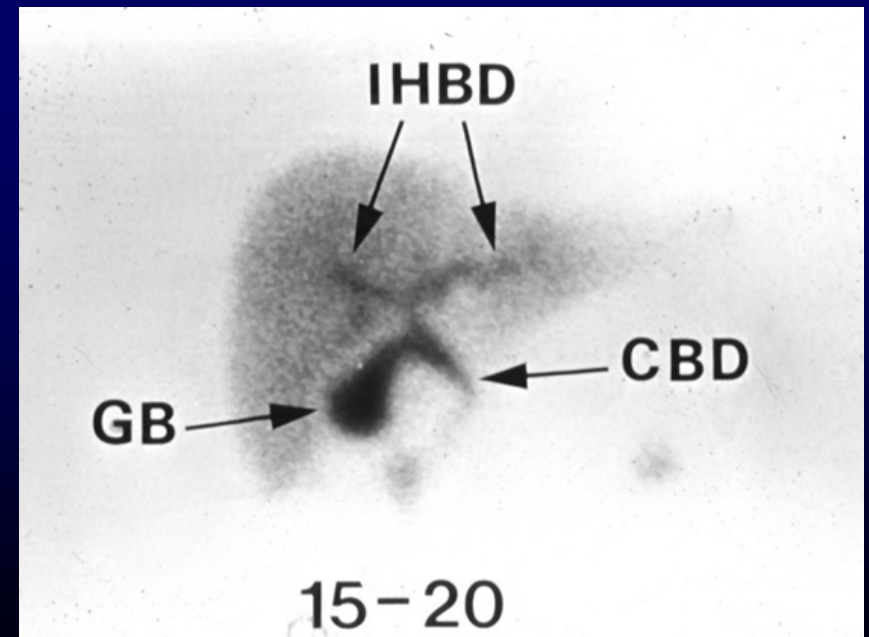
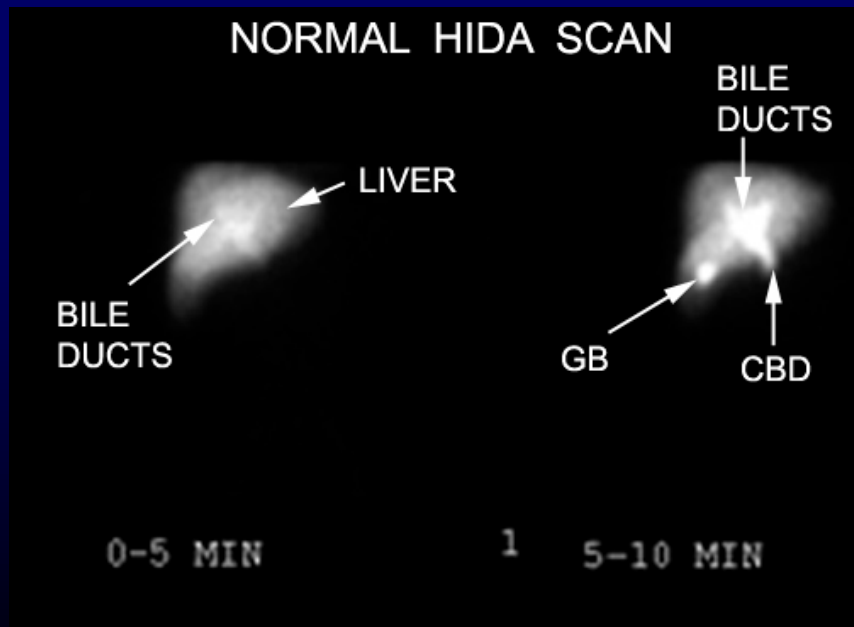
Acalculus cholecystitis:

- Thickened gallbladder wall
- No stones seen



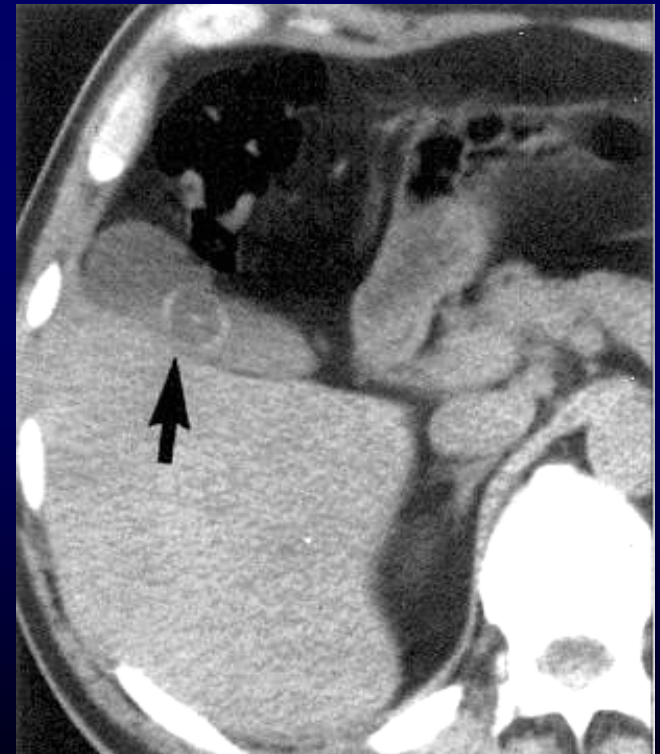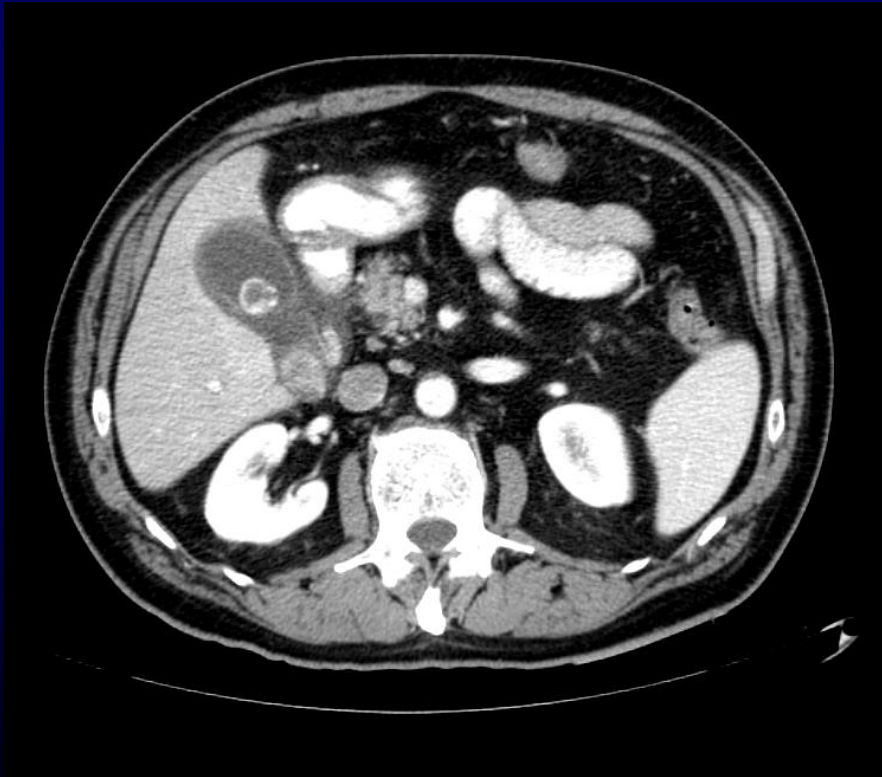HIDA Scan (hepatobiliary iminodiacetic acid)

- ✓ The HIDA scan should be used when ultrasound is equivocal.
 - ✓ Intravenous technetium labeled hepatic iminodiacetic acid (HIDA) is taken up by the hepatocytes and excreted into the bile.
- After 30-60 minutes, the scan will show (excretion of isotope) the flow of bile through the biliary tree including common bile duct, cystic duct, and gallbladder.
- ✓ Good for detecting cystic duct obstruction or CBD obstruction
 - ✓ Also very useful in determining bile leaks after cholecystectomy
 - ✓ HIDA scans can be falsely positive when the gallbladder does not fill in the absence of cholecystitis. These situations include severe liver disease, patients on total parenteral nutrition, hyperbilirubinemia, alcohol and opiate abuse.



CT

- ✓CT has a secondary role in evaluating the biliary tree with the availability and accuracy of ultrasound.
- ✓However, it is best employed when ultrasound is difficult due to obesity or when complications such as perforation or abscess formation are suspected.
- ✓It can also be used when findings are confusing on ultrasound exam.
- ✓Computed tomography can accurately identify gallstones and gallbladder wall edema.

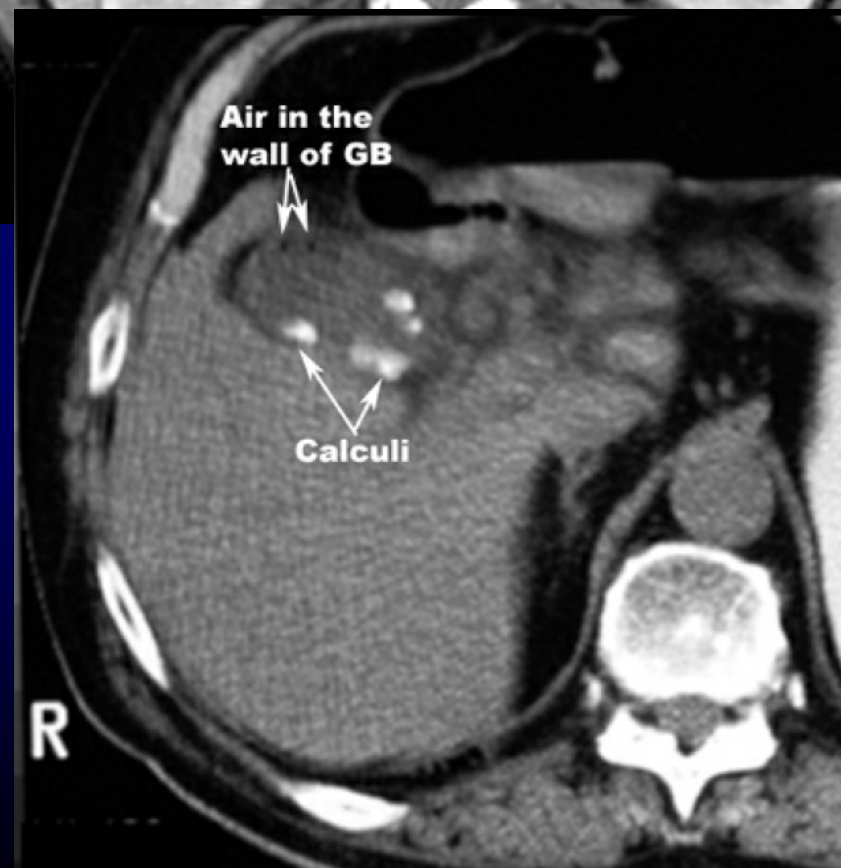
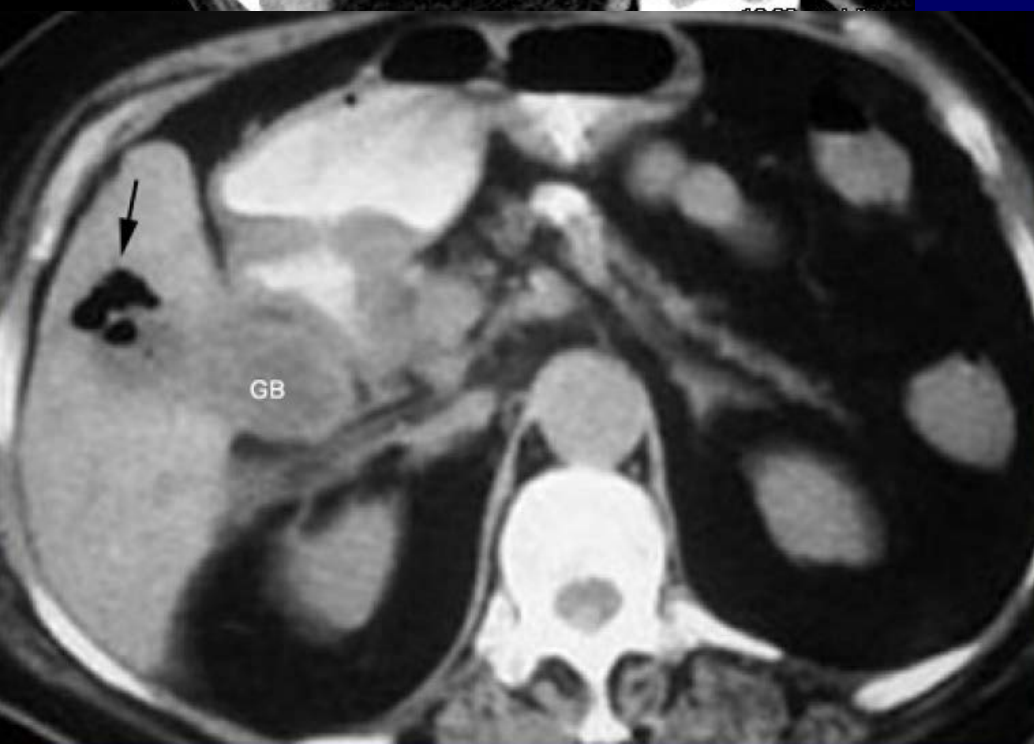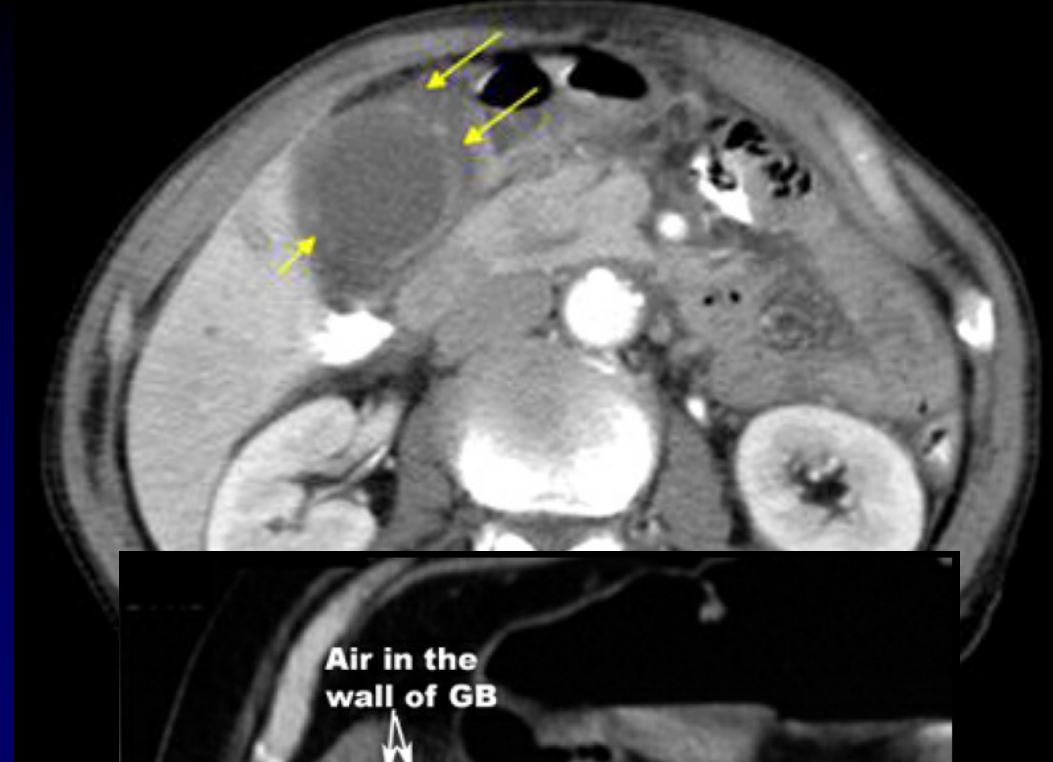
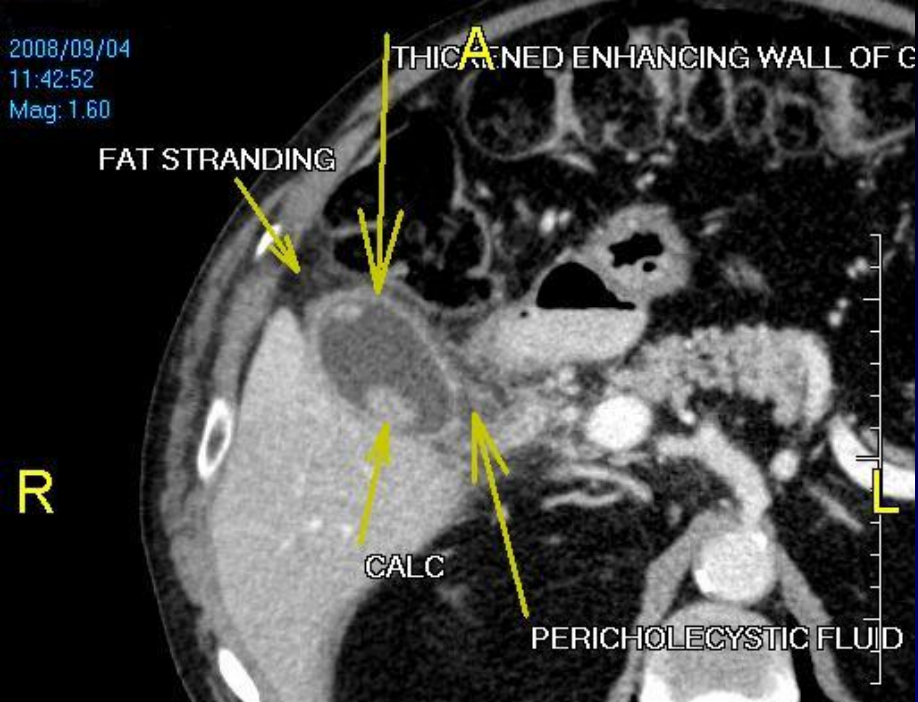


What are the imaging findings of acute cholecystitis in CT abdomen?

The most common findings on CT are:

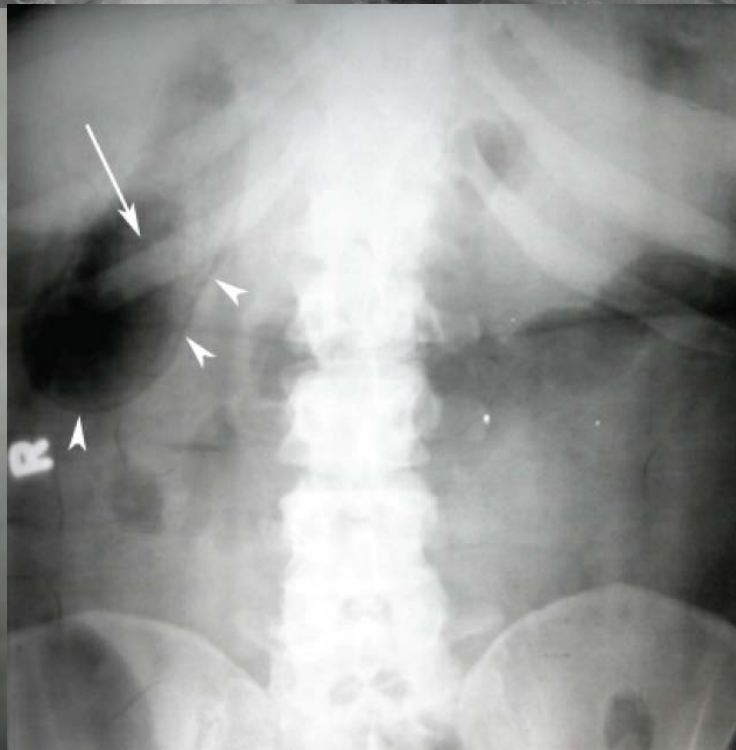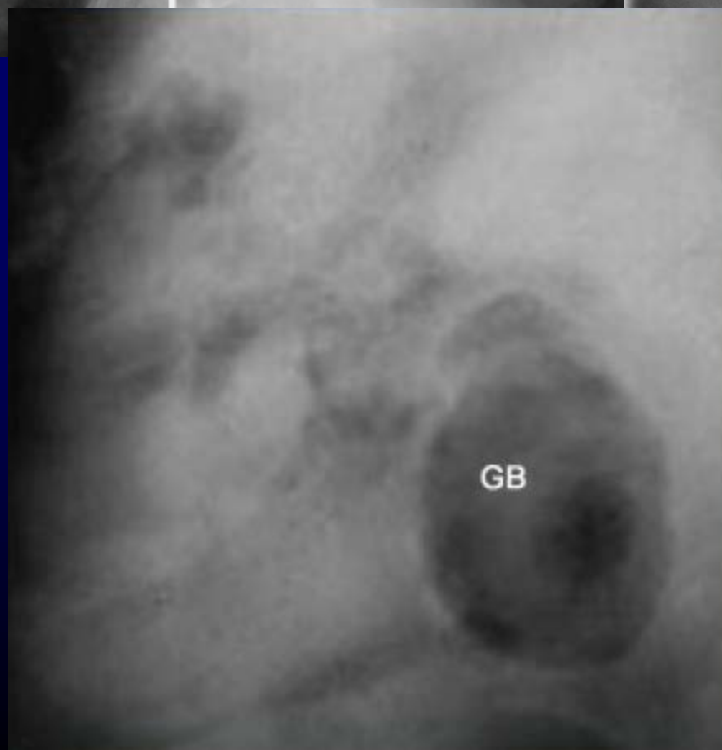
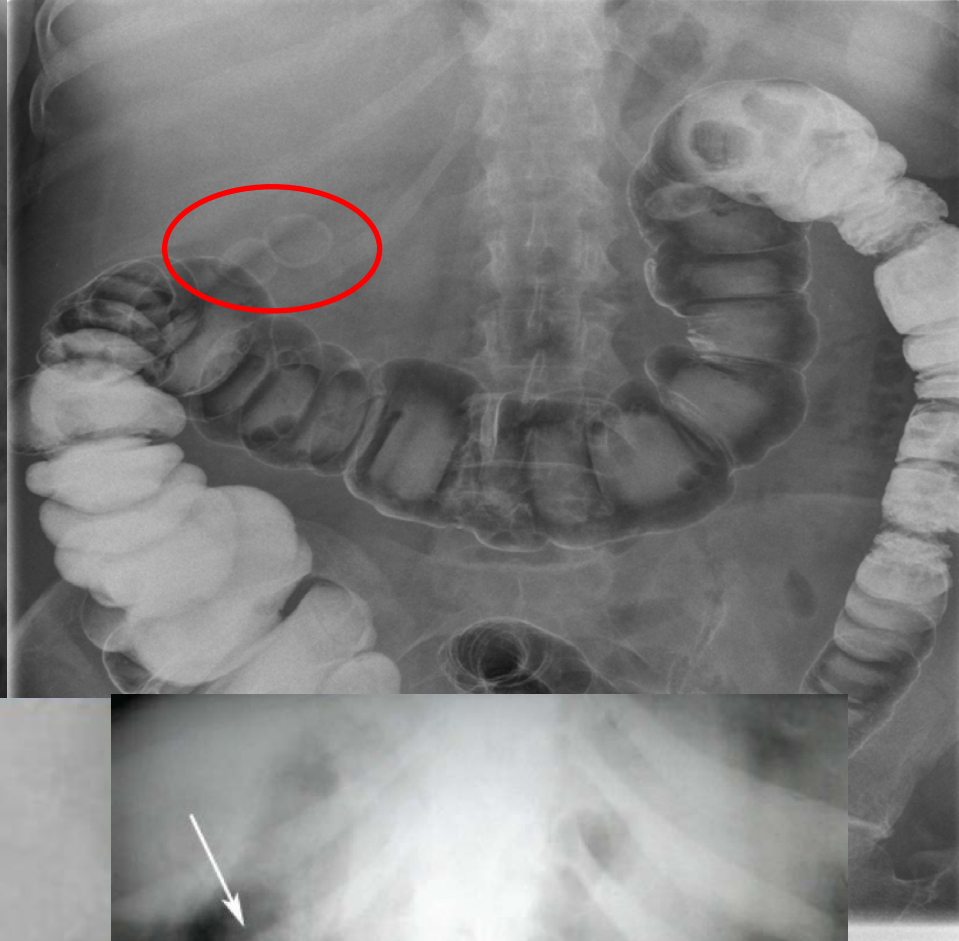
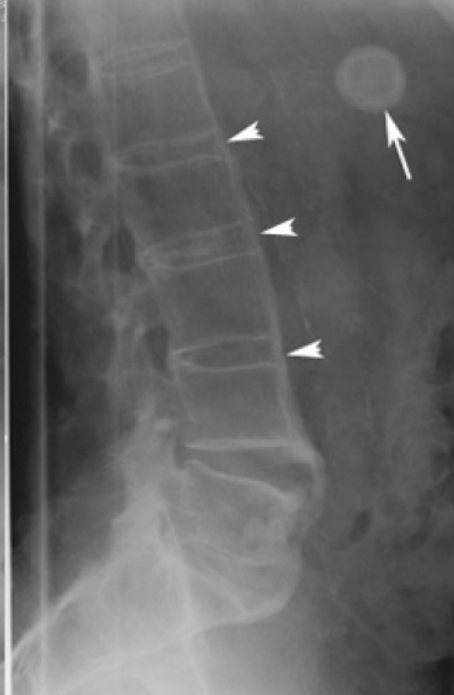
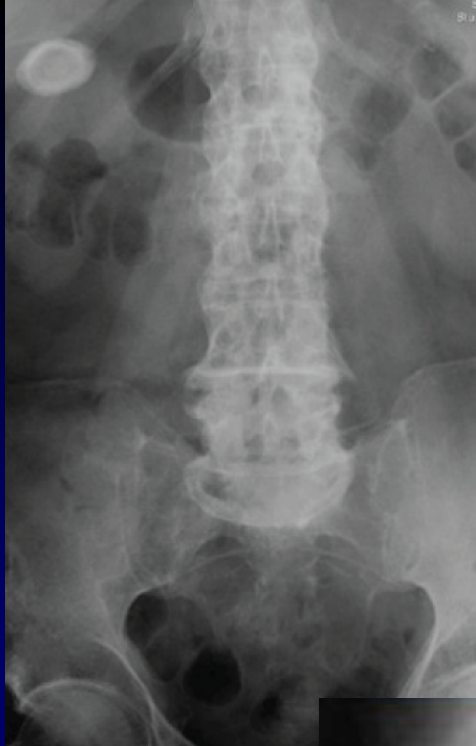
- gallstones
- wall thickening (>3 mm)
- pericholecystic fluid
- inflammation in the pericholecystic fat
- subserosal edema seen by poor definition of the gallbladder/liver wall interface
- Air in GB: Emphysematous cholecystitis
- Air in GB wall

2008/09/04
11:42:52
Mag: 1.60



What are the imaging findings of cholecystitis in abdomen X-ray?

- Acute cholecystitis is associated with gallstones in approximately 95% of cases, thus it is possible to see gallstones on plain radiograph. (Only 20% of gallstones, however, contain sufficient calcium to be seen on a plain radiograph).
- The duodenum and/or hepatic flexure of the colon may show an ileus from the resulting inflammation of the adjacent gallbladder.
- Very rarely gas may be seen in the biliary tree.
- In two-thirds of cases, the plain radiograph is completely normal or may show mild dilation of small and large bowel.
- In emphysematous cholecystitis air can be recognized in the gall bladder and gall bladder wall.



- **Some disorders that may be confused with acute cholecystitis:**
 - perforated peptic ulcer
 - acute pancreatitis
 - appendicitis (high lying appendix)
 - liver abscess
 - hepatitis
 - pneumonia w/pleurisy on right side
 - myocardial ischemia
 - **Should keep in mind the Saint's triad** (coexistence of gallstones, diverticulosis of the colon, and hiatus hernia)

Management

□ Conservative Tx:

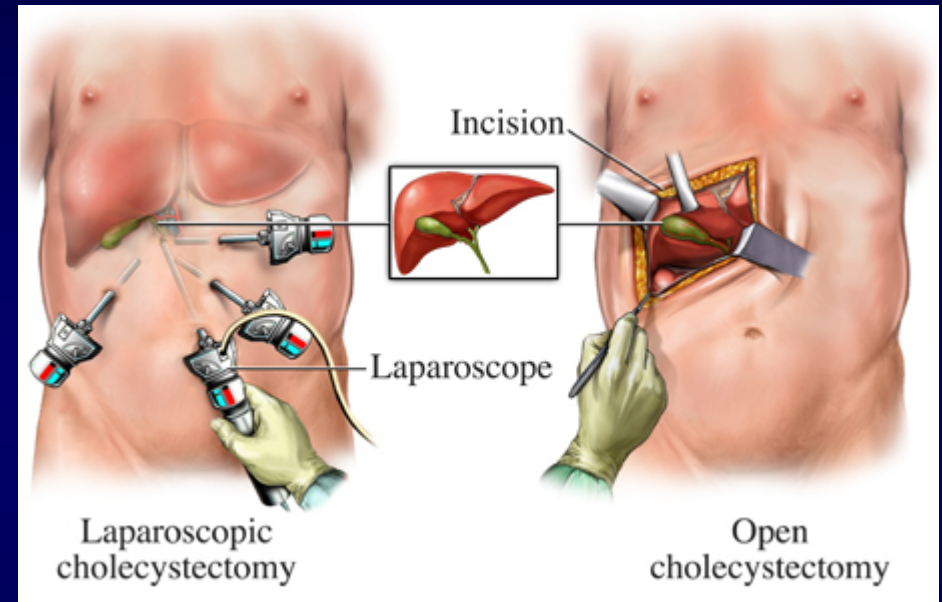
- NPO,
- IVF,
- Abx (GNR & enterococcus),
- analgesics, spasmolytics

THREE MAIN TYPES OF SURGERY TIMING FOR ACUTE CHOLECYSTITIS:

IMMEDIATE OPERATION – 6-12 HOURS

URGENT OPERATION –24-48 HOURS

PROGRAMMED (DELAYED) OPERATION

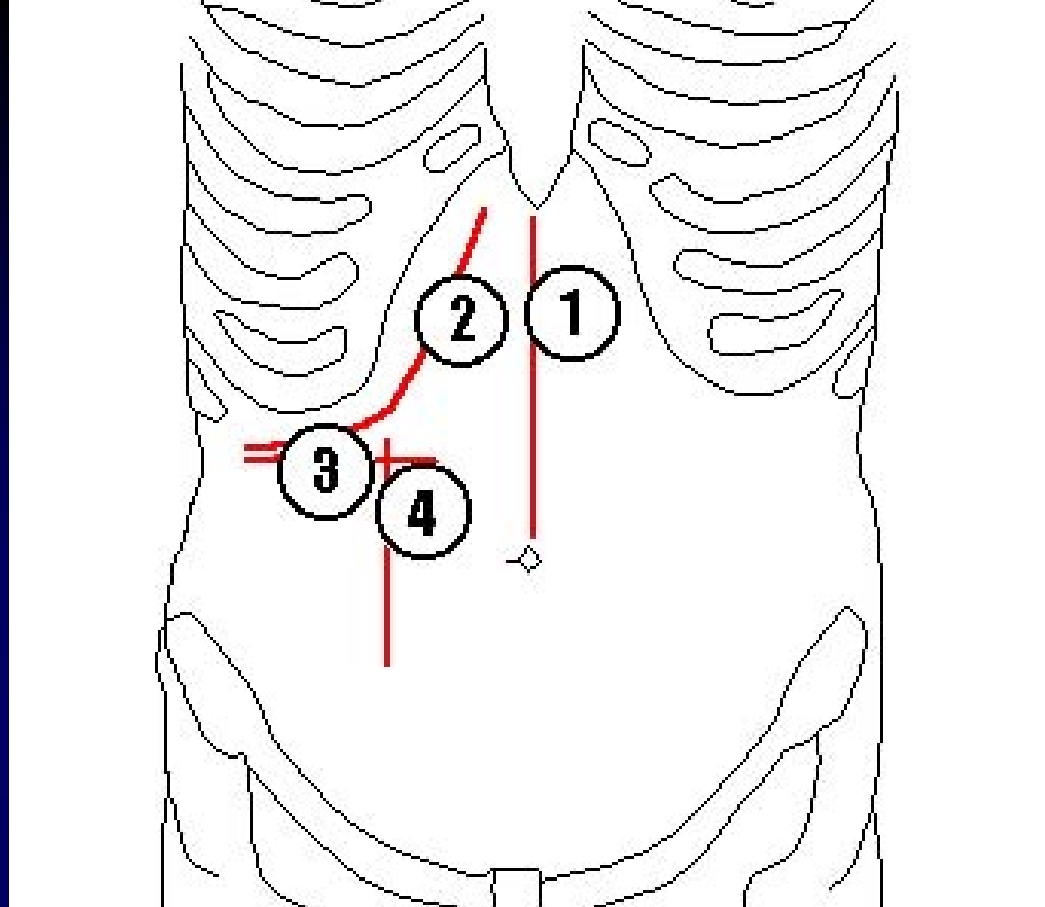


TYPES OF SURGERY

1. Open cholecystectomy
2. Laparoscopic surgery



Carl Langenbuch
1882 first cholecystectomy

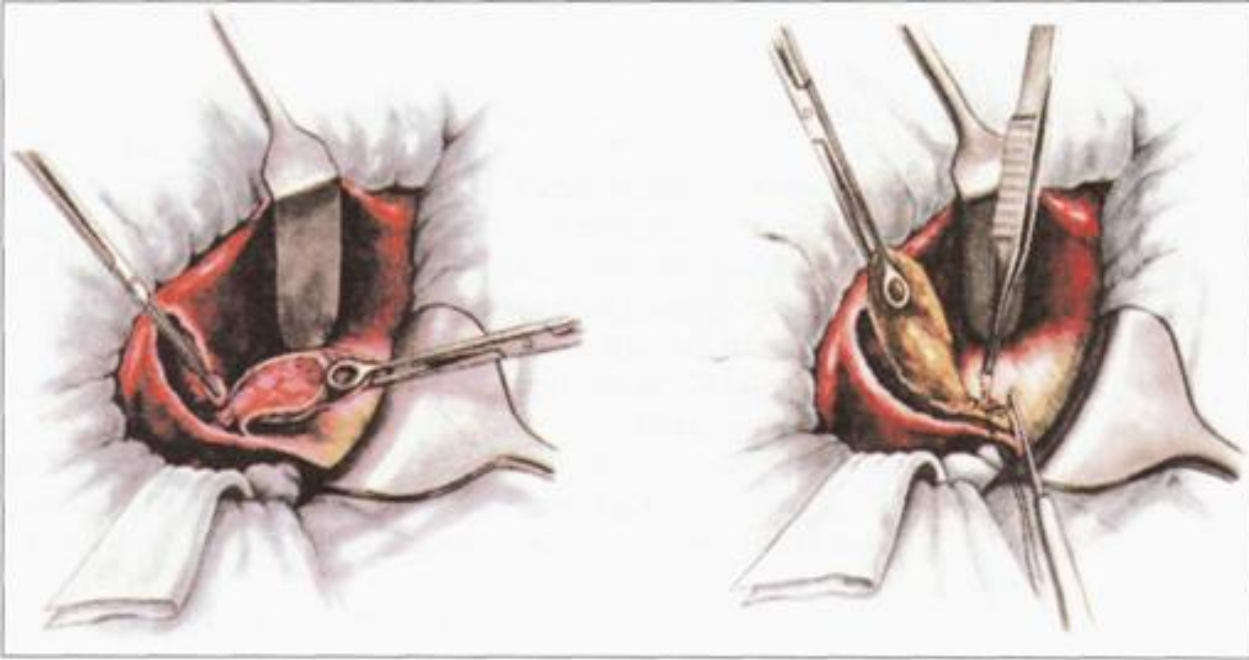


**1. MIDLINE LAPAROTOMY
(LEBKER)**

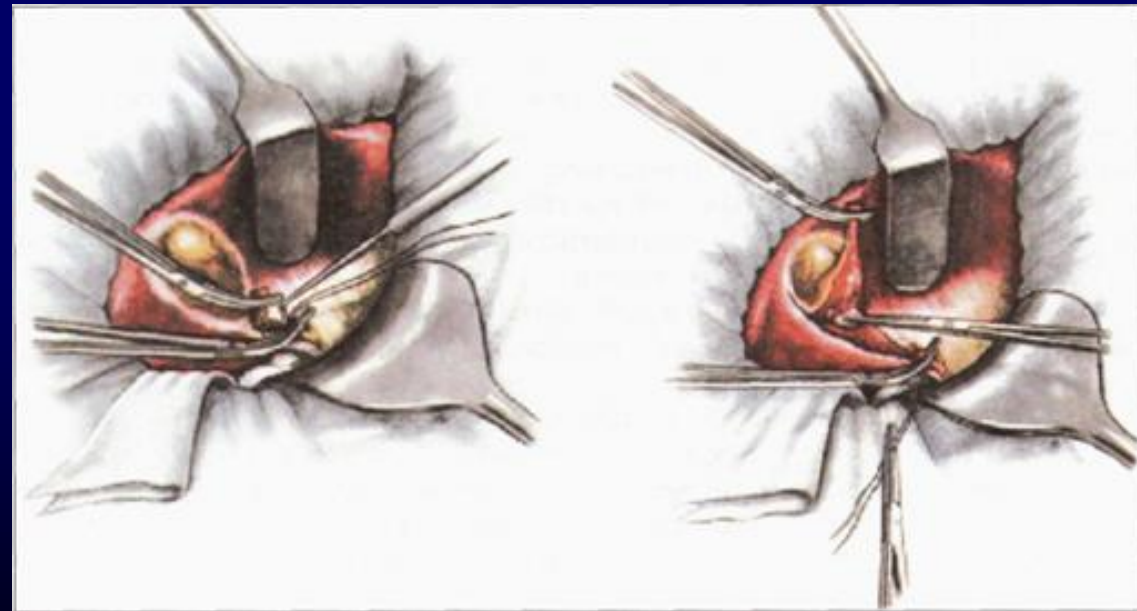
**2. RIGHT SUBCOSTAL INCISION
(KOCHER)**

**3. TRANSVERSAL LAPAROTOMY
(SPRENGEL)**

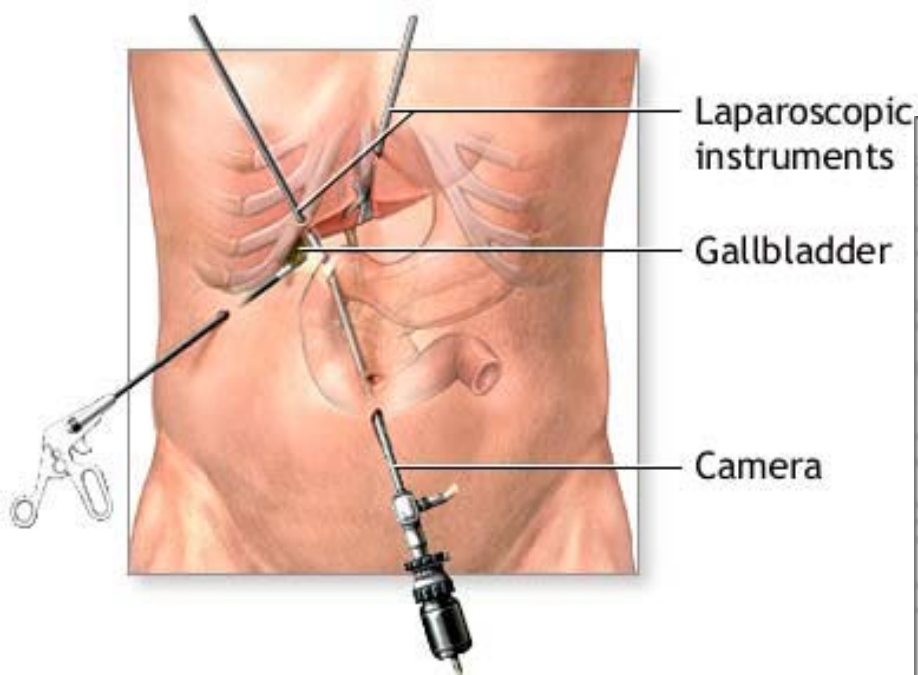
**4. RIGHT PARARECTAL INCISION
(CZERNI)**



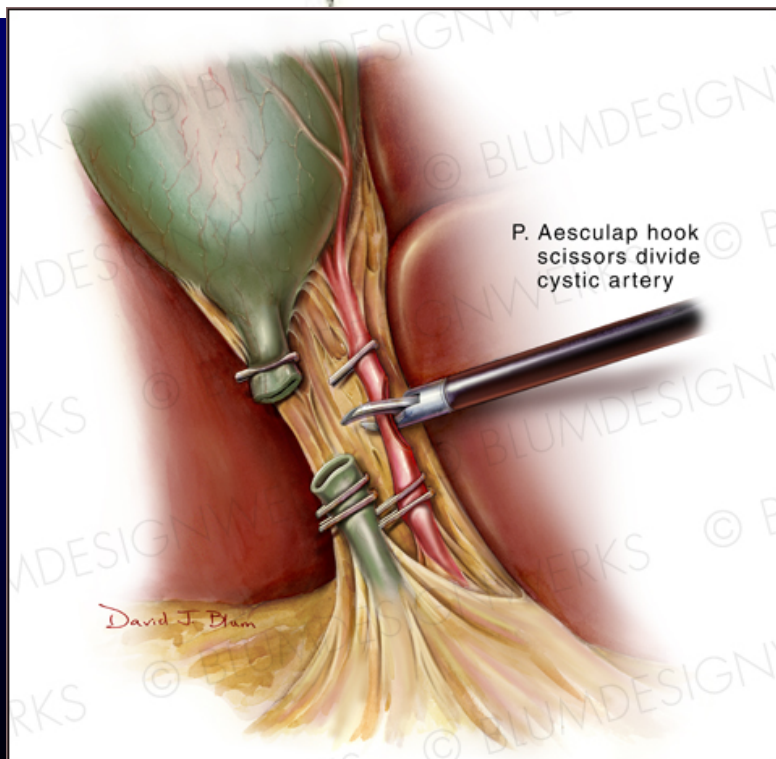
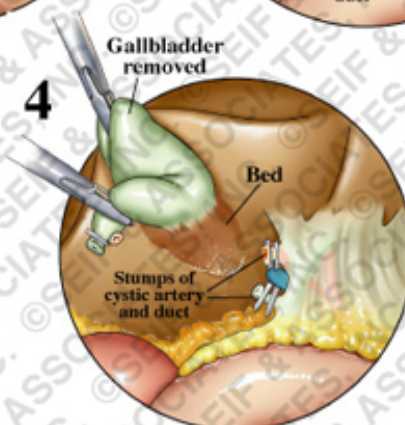
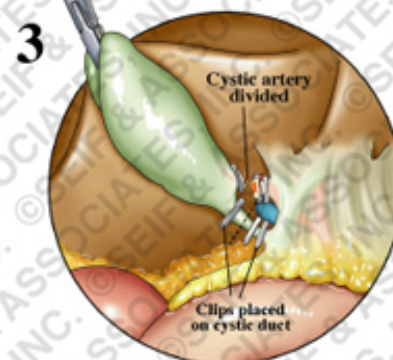
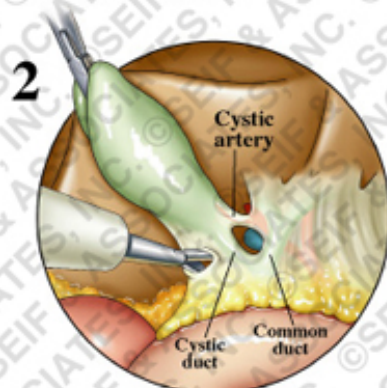
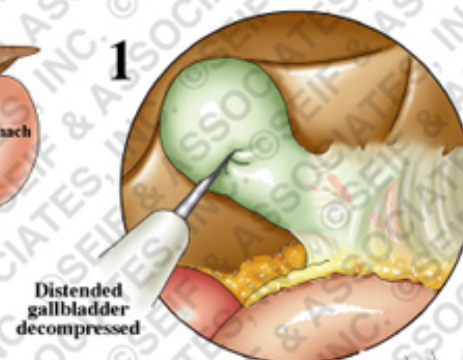
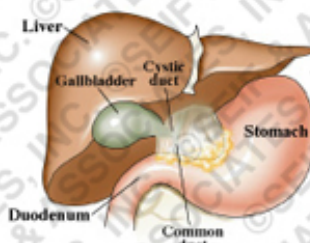
Antegrade cholecystectomy (from bottom to the neck)

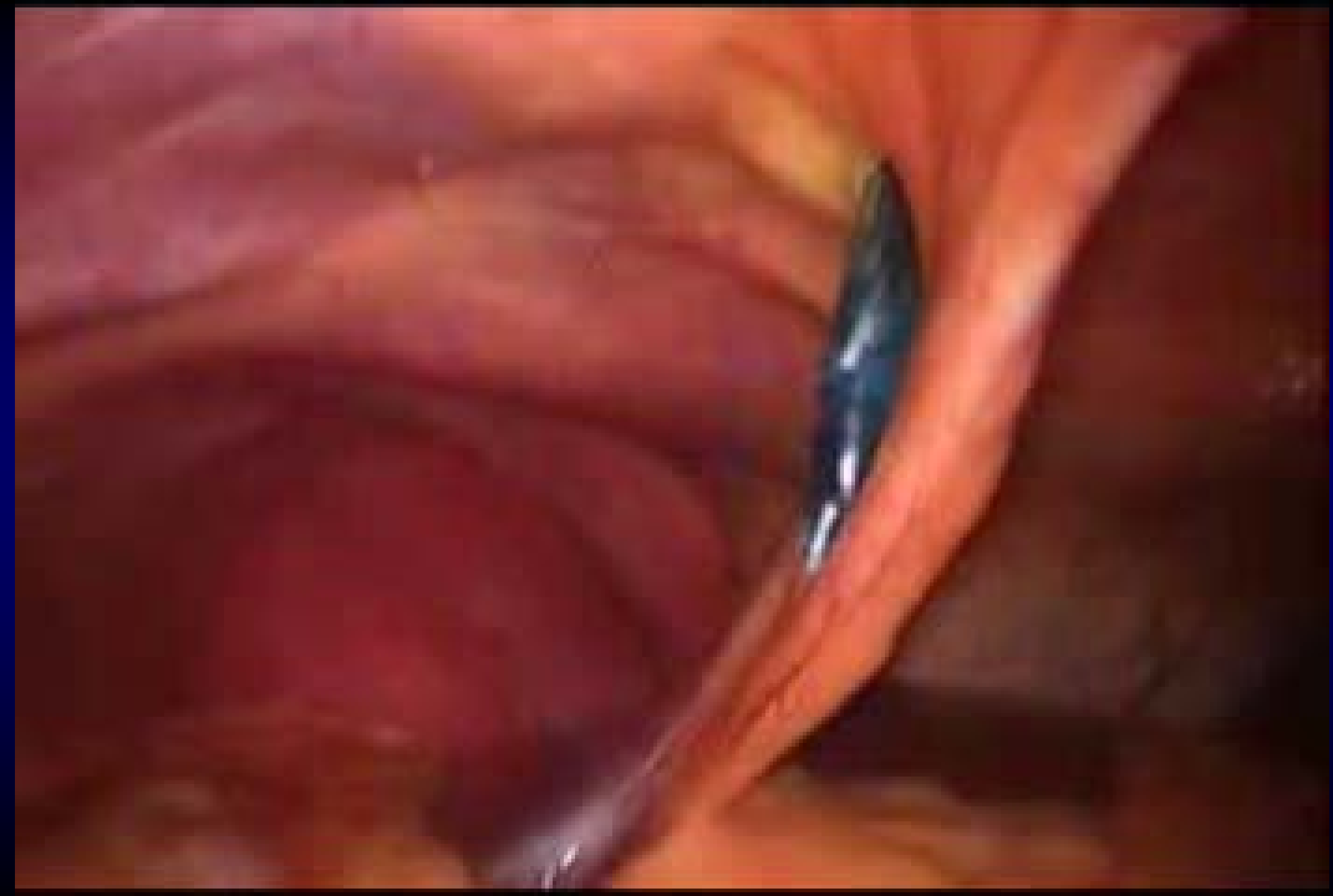

Retrograde cholecystectomy (from neck to the bottom)



LAPAROSCOPIC CHOLECYSTECTOMY





LAPAROSCOPIC SURGERY

A) ADVANTAGES

- ☐ Patient can leave the hospital and resume normal activities earlier than in open surgery.
- ☐ Incision is small as compared to laparotomy
- ☐ Less post operative pain and disability
- ☐ Fewer complications

B) CONTRAINDICATIONS

a) ABSOLUTE CONTRAINDICATION

1) Patient who is unfit to sustain general anesthesia-as procedure takes long time.

2) Pregnancy –Since the effects of pneumoperitoneum on the fetus thus laparoscopic surgery should not be done in pregnant women.

Soper- recommend to be done in Second trimester and in experienced laparoscopic surgeon in case a patient has severe biliary disease.

3) Acute cholangitis

- as the patient has obstructed ductal system that cannot be cleared readily by laparoscopic cholecystectomy**

4) Septic peritonitis/septic shock

5) Severe bleeding disorders

6) Pancreatitis

7) Cholecystoenteric fistula

8) Doubt of malignancy

b) RELATIVE CONTRAINDICATIONS

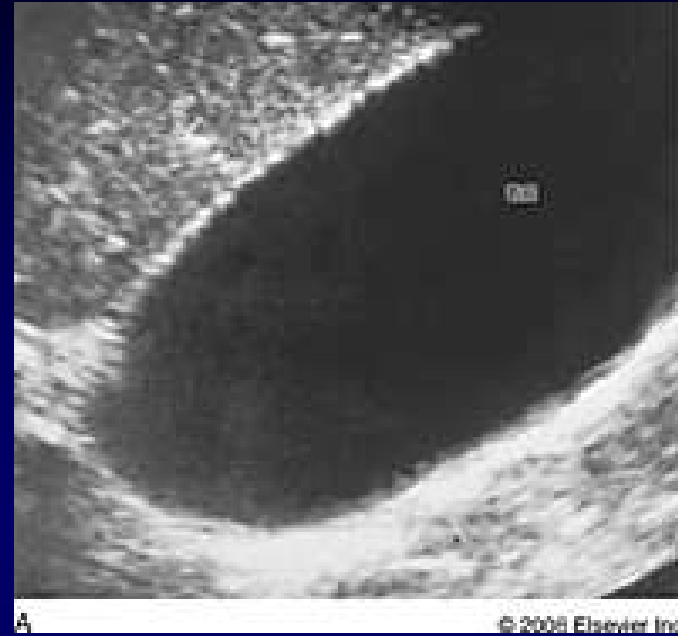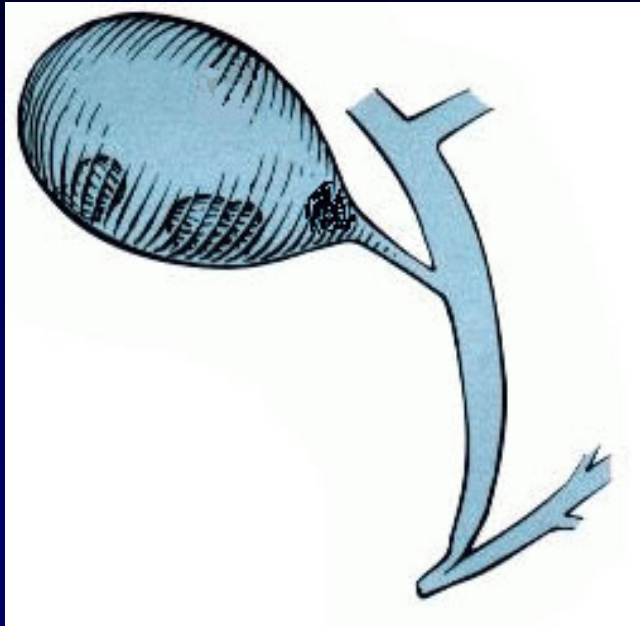
- 1) Acute cholecystitis**
- 2) Prior abdominal surgery**
- 3) Inflammatory bowel diseases**
- 4) Abdominal malignancy**
- 5) Advanced liver diseases**
- 6) Untreated choledocholithiasis**
- 7) Coexisting medical conditions**
- 8) Minor bleeding disorder**
- 9) Obesity**

C) CONDITIONS TO CHANGE FROM LAPAROSCOPIC TO OPEN SURGERY

- 1. Bleeding or bile leak that cannot be stopped safely without risk of injury to important structures.**
- 2. Cholecystoenteric fistula**
- 3. Perforation in the RUQ**
- 4. Big stone that cannot be removed laparoscopically.**
- 5. Unexpected problem that needs open surgery.**
- 6. Internal structures not clearly visible**
- 7. Possible or known injury of major blood vessels.**
- 8. Local abscess**
- 9. Previous endoscopic sphincterotomy**

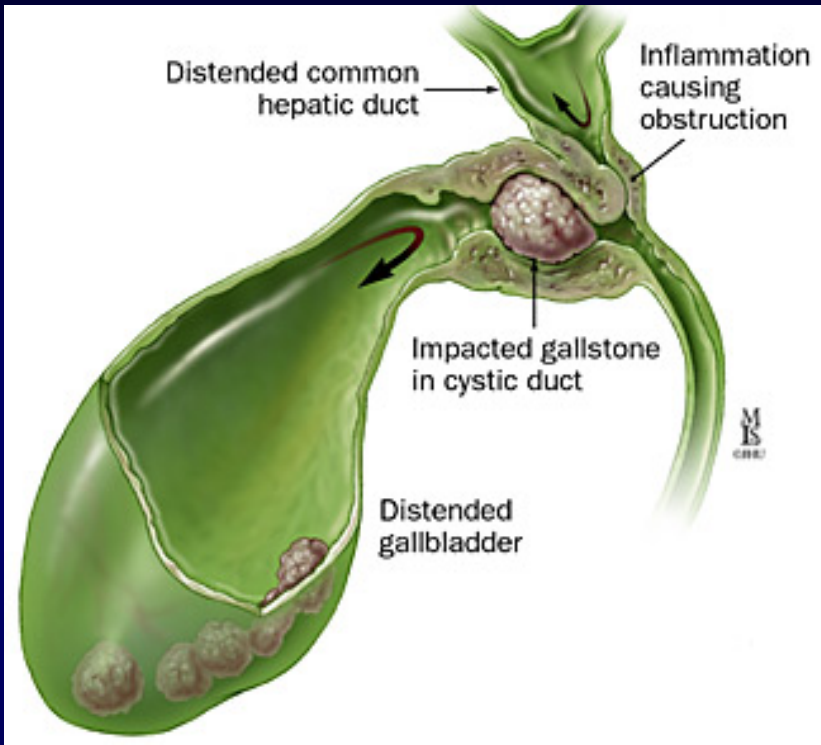
D) COMPLICATIONS OF LAPAROSCOPIC SURGERY

- 1) Bowel and liver laceration with bleeding.**
- 2) Complications related to pneumoperitoneum**
- 3) Gallstone spillage**
- 4) Injury of bile duct**
- 5) 6% of procedures surgeon miss the stone.**

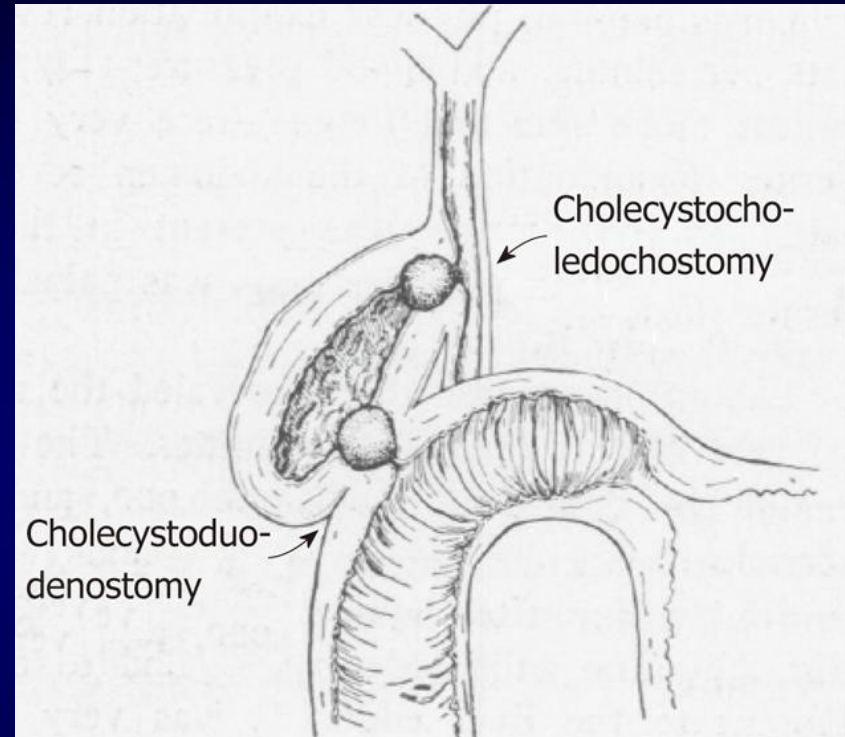


HYDROPS

BILIARY FISTULAS

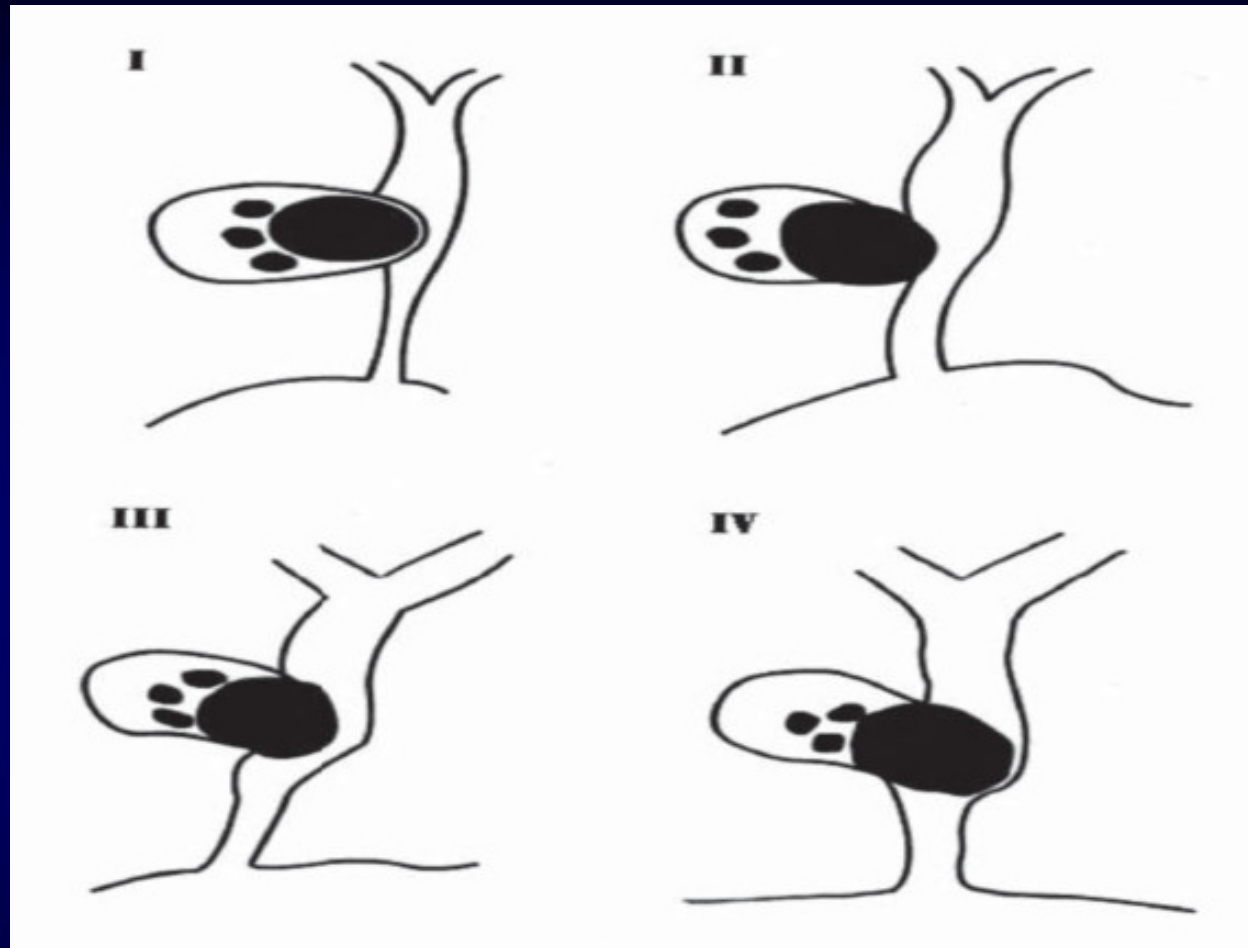


**BILIO-BILIARY FISTULAS
(MIRIZZI SYNDROME)**



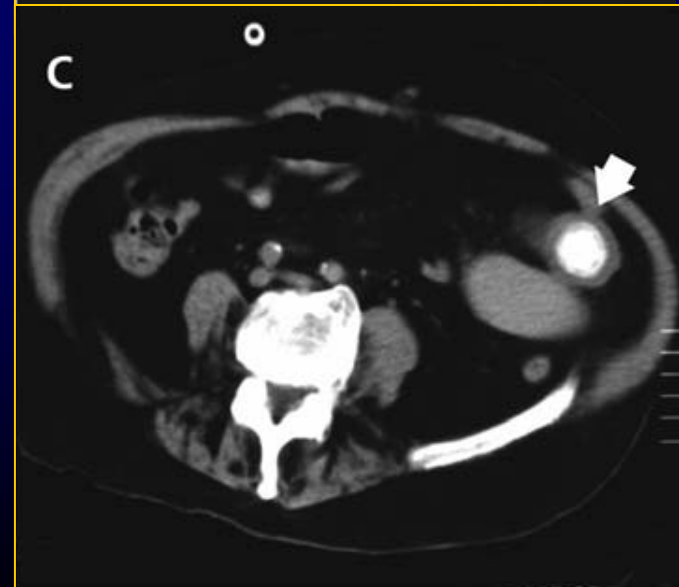
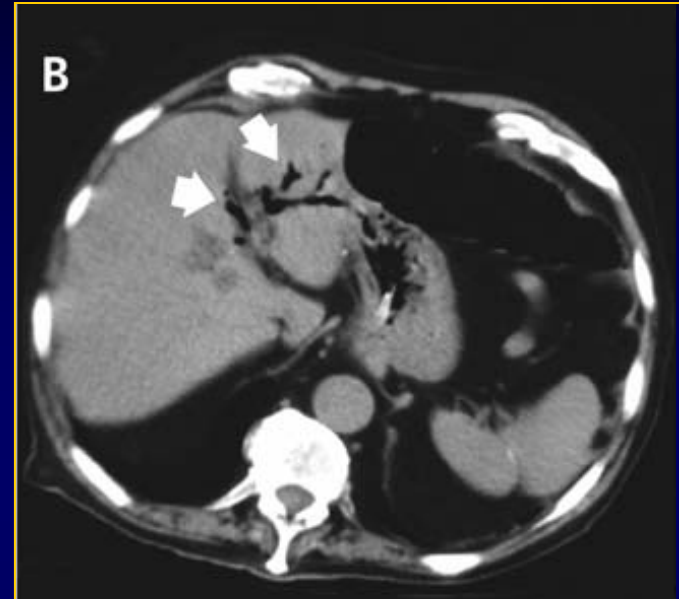
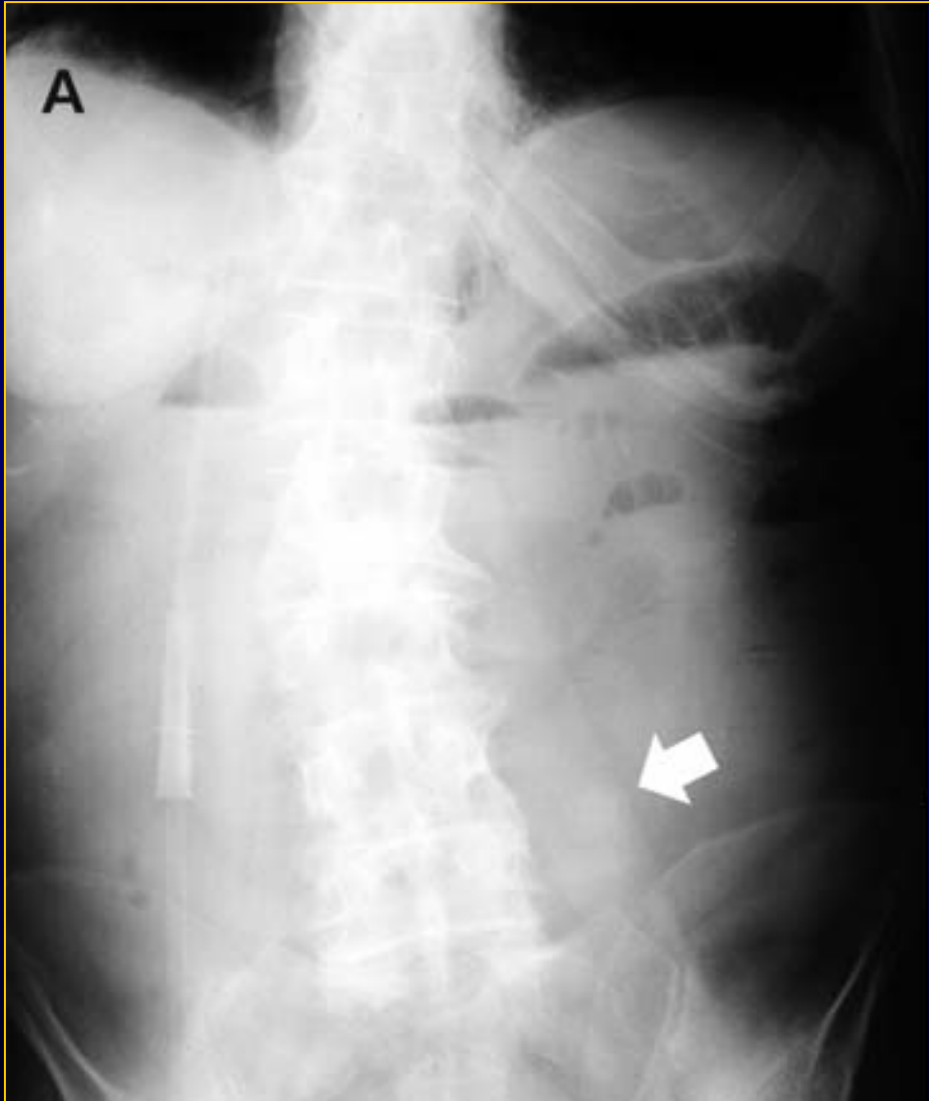
BILIO-DIGESTIVE FISTULAS

CHOLECYSTO-CHOLEDOCAL FISTULAS (MIRIZZI SYNDROME)



Chatzoulis *et al.* Schematic representation of Csendes classification for Mirizzi syndrome. *BMC Surgery* 2007 7:6 doi:10.1186/1471-2482-7-6

Rigler triad (**A** - small bowel obstruction, **B** - pneumobilia, and **C** - gallstones usually seen in the right iliac fossa)



1.5T MEDPC

Ex: 299118

I2_haste_1s_cor_FETTONA

Sr: 8/16

Im: 1/1

Cor: A15.3 (COI)

Sr

Pres. Osp. F. Lotti

1932 May 14 F TOSUSL600005075

Acc: 8-64-302397

2010 Mar 09

Acq Tm: 15:51:57.710000

384 x 269

Rr

Lr

ET: 256

TR: 4500.0

TE: 751.0

50.0thk/-50.0sp

Id:DCM / Lin:DCM / Id:ID

W:430 L:174

La

DFOV: 30.0 x 30.0cm



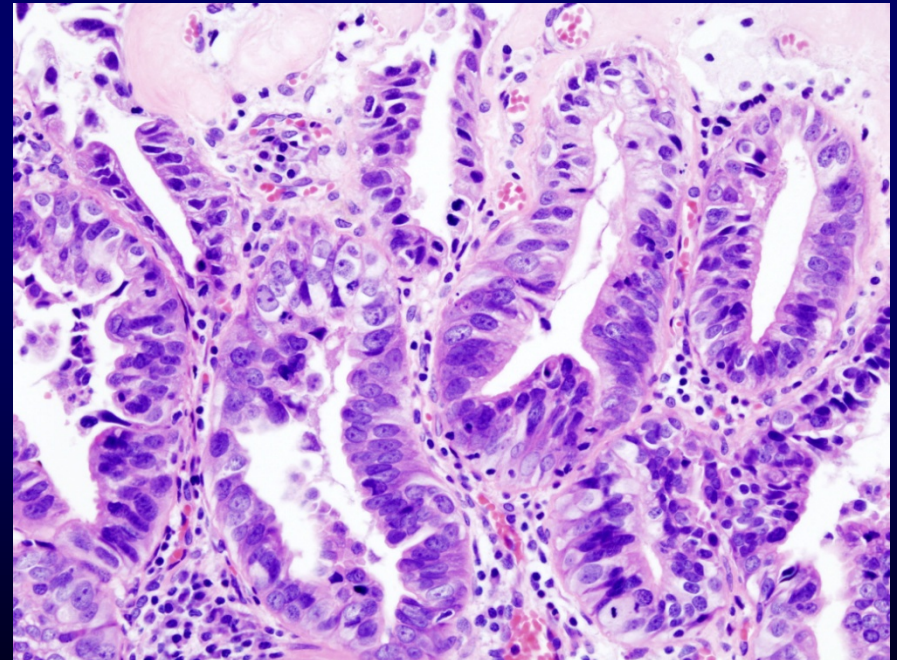
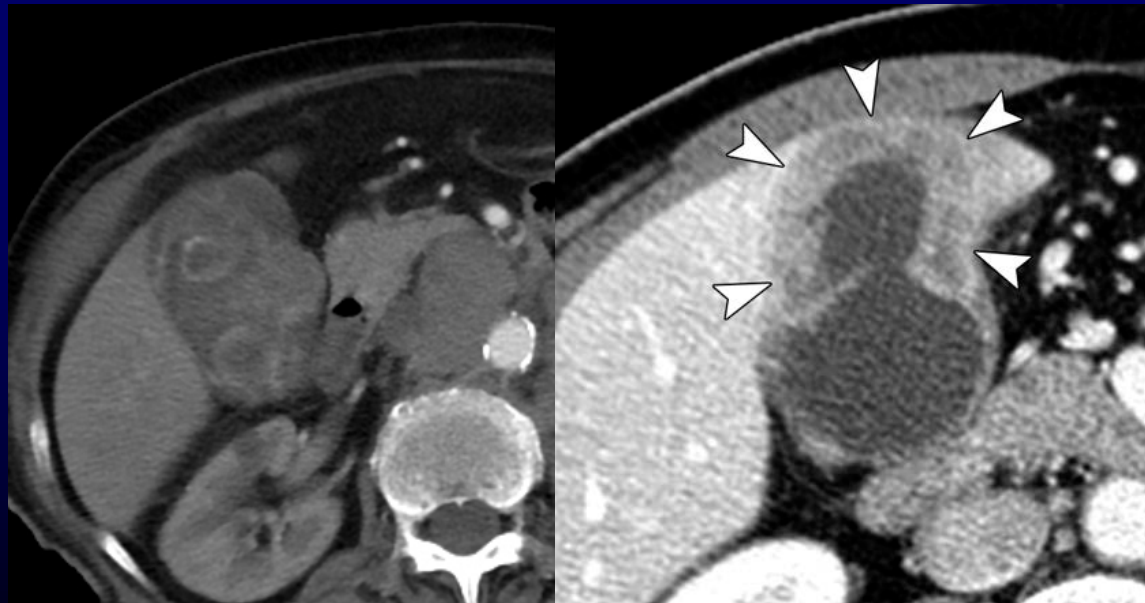
Carcinoma of Gallbladder

- Occurs in 2% of people surgically treated for biliary disease
- Insidious onset - usually discovered during surgery
- Cholelithiasis usually present
- Other risk factors:
 - Chronic gallbladder infection with salmonella typhi
 - gallbladder polyps over 1cm
 - mucosal calcification of the gallbladder (**porcelain gallbladder**)
 - anomalous pancreaticobiliary ductal junction

The most common type is gallbladder adenocarcinoma

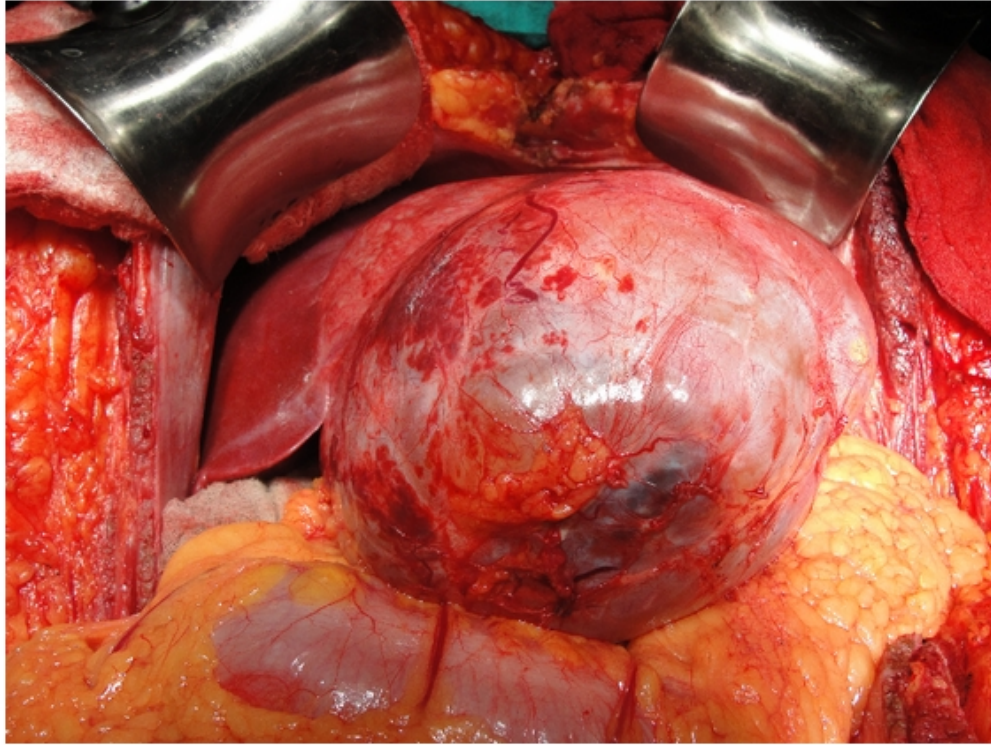
Rare types of gallbladder cancer

- Squamous cell cancer of the gallbladder
- Adenosquamous carcinoma of the gallbladder
- Small cell carcinoma of the gallbladder
- Sarcoma of the gallbladder
- Neuroendocrine tumour of the gallbladder
- Lymphoma and melanoma of the gallbladder

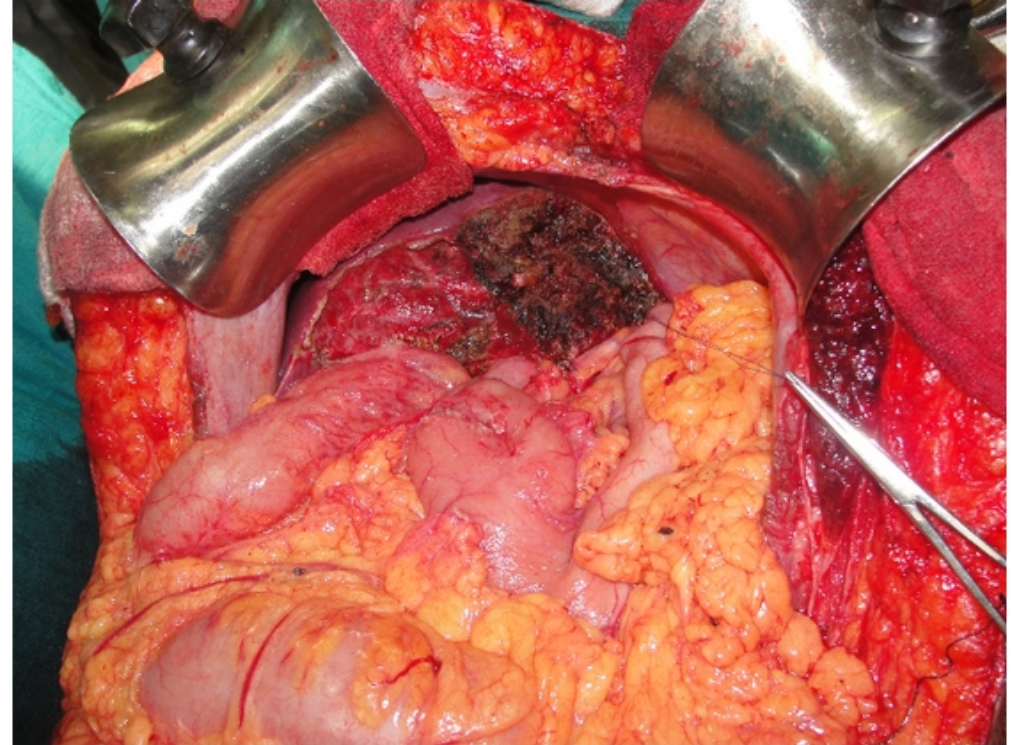


Gallbladder adenocarcinoma: histopathology

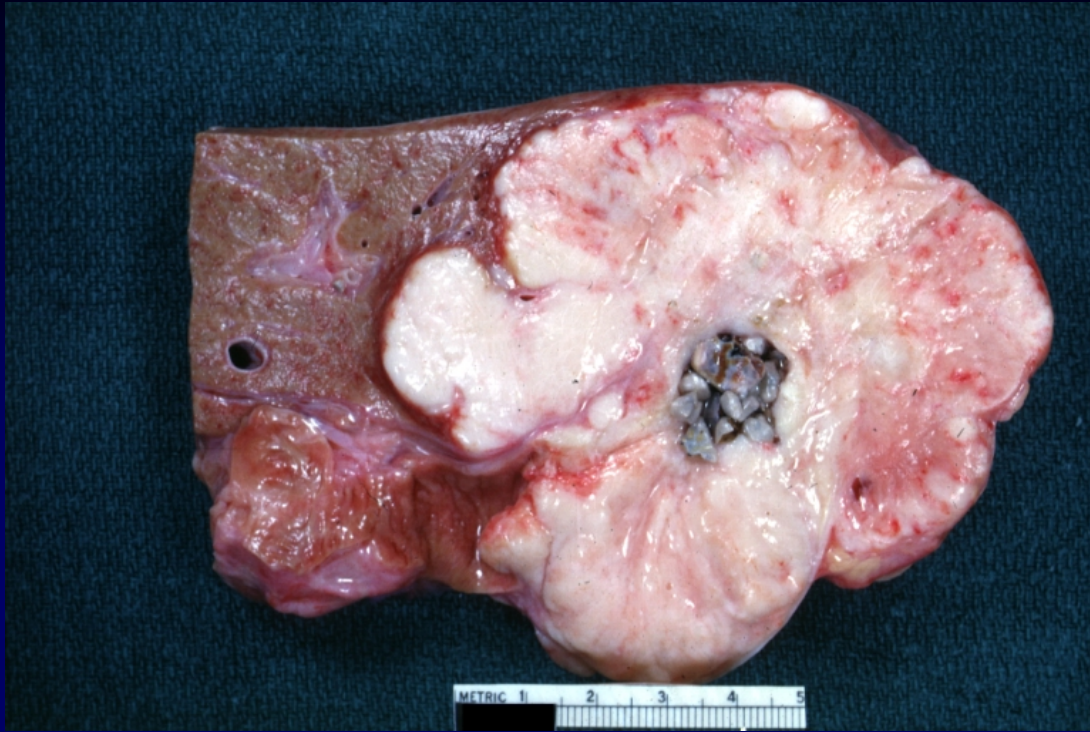Biliary cystadenoma



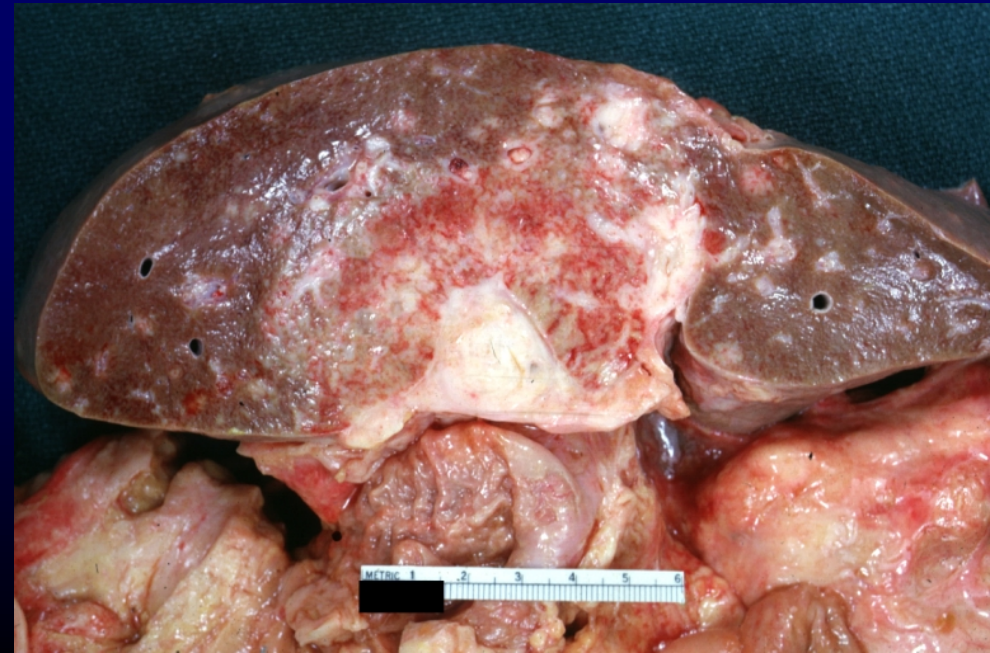Intraoperative picture showing large thick-walled cystic lesion arising from left lobe of liver.



Remnant right lobe of liver after left hepatectomy.



Gallbladder neoplasm invading liver and surround a cavity with mixed type gallstones



OBSTRUCTIVE JAUNDICE (a.k.a. POSTHEPATIC, MECHANICAL)

Jaundice (also known as **icterus**; from the Greek word *ίκτηρος*, attributive adjective: **icteric**) is a yellowish pigmentation of the skin, the conjunctival membranes over the sclerae, and other mucous membranes caused by hyperbilirubinemia. This hyperbilirubinemia subsequently causes increased levels of bilirubin in the extracellular fluid. Concentration of bilirubin in blood plasma does not normally exceed 1mg/dL ($>17\mu\text{mol/L}$). A concentration higher than 1.8 mg/dL ($>30\mu\text{mol/L}$) leads to jaundice.

Post-hepatic jaundice, also called obstructive jaundice, is caused by an interruption to the drainage of bile in the biliary system.

The most common causes are:

- gallstones in the common bile duct (choledocolithiasis),
- pancreatic cancer in the head of the pancreas
- parasites in the common bile duct
- strictures of the common bile duct,
- biliary atresia
- cholangiocarcinoma
- pancreatitis and pancreatic pseudocysts
- Mirizzi syndrome

Classification of obstructive jaundice

Type I : complete obstruction

- Tumors : Ca. head of Pancreas
- Ligation of the CBD
- Cholangio carcinoma
- Parenchymal Liver diseases

Type II : Intermittent obstruction

- **Choledocholithiasis**
- **Periampullary tumor**
- **Duodenal diverticula**
- **Choledochal Cyst**
- **Papillomas of the bile duct**
- **Intra biliary parasites**
- **Hemobilia**

TYPE III : Chronic incomplete obstruction

➤ Strictures of the CBD

Congenital

Traumatic

Sclerosing cholangitis

Post radiotherapy

➤ Stenosed biliary enteric anastamosis

➤ Cystic fibrosis

➤ Chronic pancreatitis

➤ Stenosis of the Sphincter of Oddi

TYPE IV : Segmental Obstruction

- **Traumatic**
- **Hepatodocholithiasis**
- **Sclerosing cholangitis**
- **Cholangio carcinoma**

Jaundice is a sign of an underlying disease. Common signs and symptoms include:

- **yellow discoloration of the skin, mucous membranes, and the sclerae,**
- **light-colored (acholic) stools,**
- **dark-colored urine, and**
- **itching of the skin.**

The underlying disease may result in additional signs and symptoms. These may include:

- nausea and vomiting,
- abdominal pain fever,
- weakness,
- etc

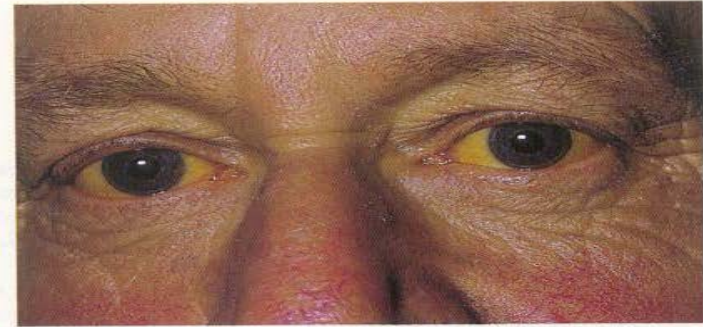

Fig. 71 Icteric sclerae in obstructive jaundice.

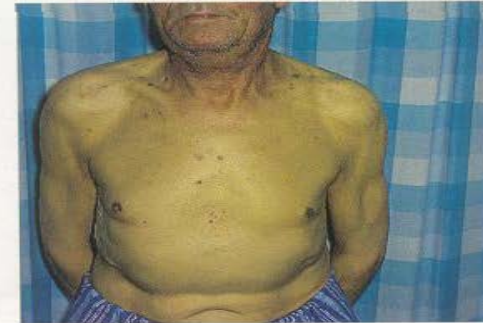

Fig. 72 A jaundiced patient.



Fig. 73 Faeces and urine in obstructive jaundice.

Abnormal LFTs

	Obstruction	Hepatitis	Cirrhosis
Bilirubin	↑↑	↑↑	↑
Alk phos	↑↑	→/↑	→/↑
ALT/AST	→/↑	↑↑	→/↑
gGT	↑↑	↑↑	→/↑
PT (INR)	→	→	↑

Goal of Treatment

➤ Obstructive Jaundice

- Relief of Obstruction
- Prevent Complication
- Prevent Recurrence

The role of Radiology

Are the ducts dilated

What is the level of obstruction

What is the cause

What is the best therapeutic approach

Investigations

Non-invasive

AXR

US

CT

HIDA Scintigram

MRI/MRCP

Invasive

ERCP

PTC

Operative
cholangiogram

T-tube
cholangiogram

Angiogram

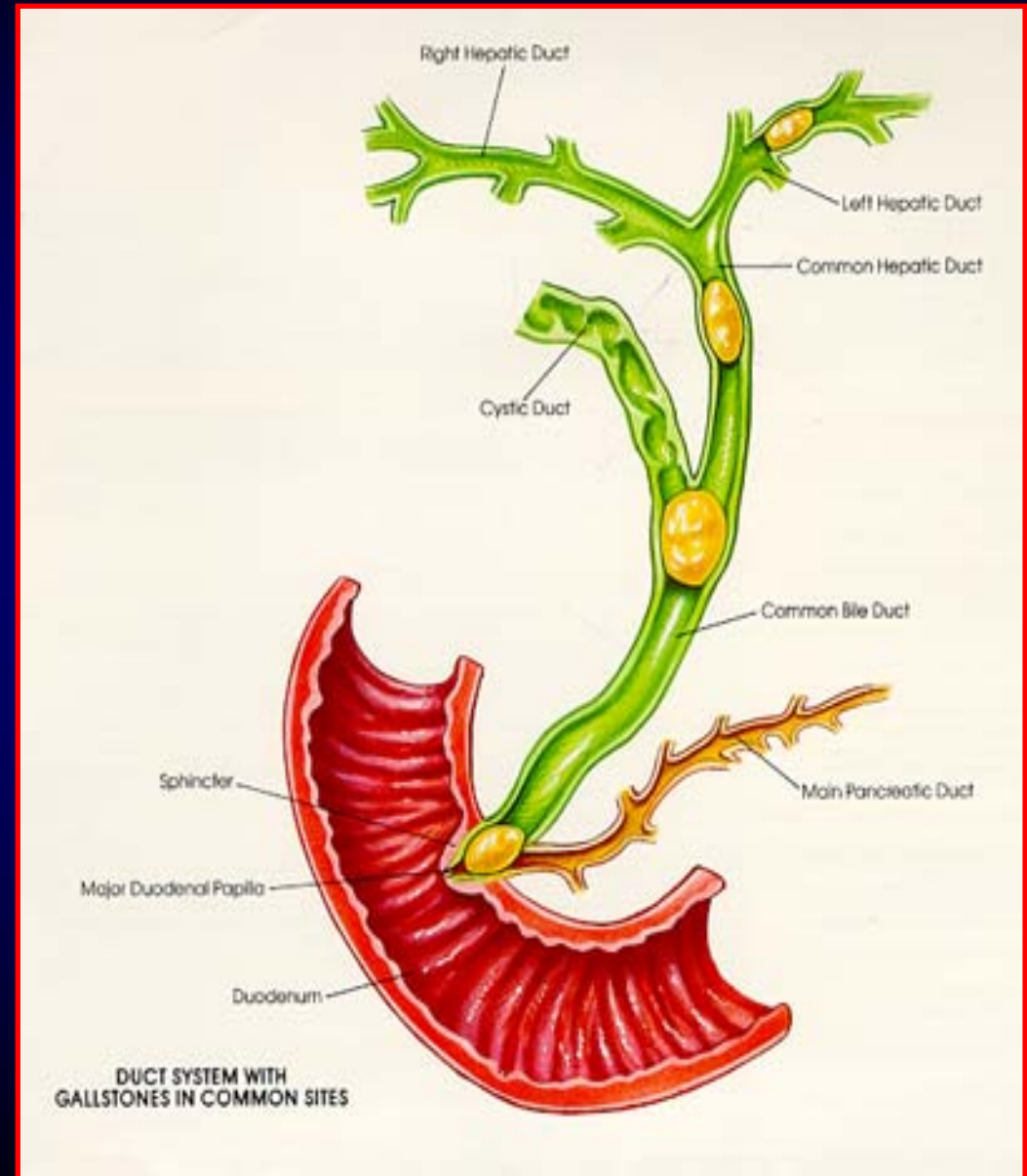
Biopsy

Choledocholithiasis

- **Choledocholithiasis - common bile duct stones**
- **Occur in 15% of patients with gallstones**
- **Increases with age - in elderly w/gallstones occurrence as high as 50%**
- **Usually condition goes unknown until obstruction occurs**

CHOLEDOCHOLITHIASIS

- **PRIMARY**
- **SECONDARY**



Cholangitis

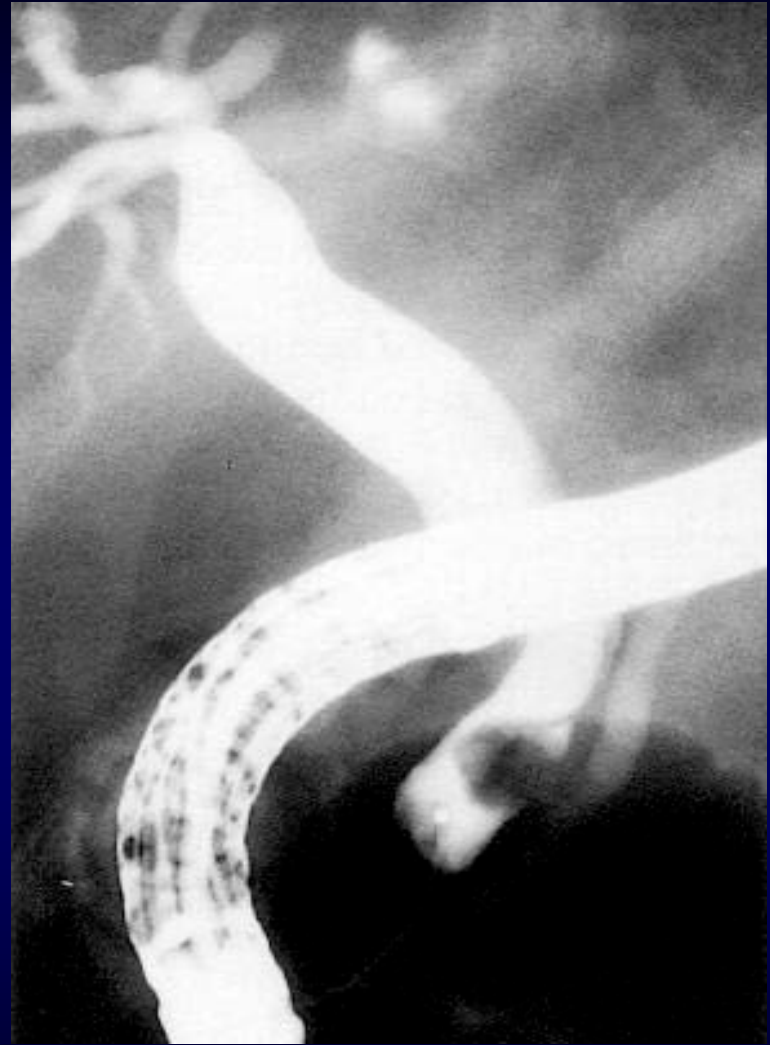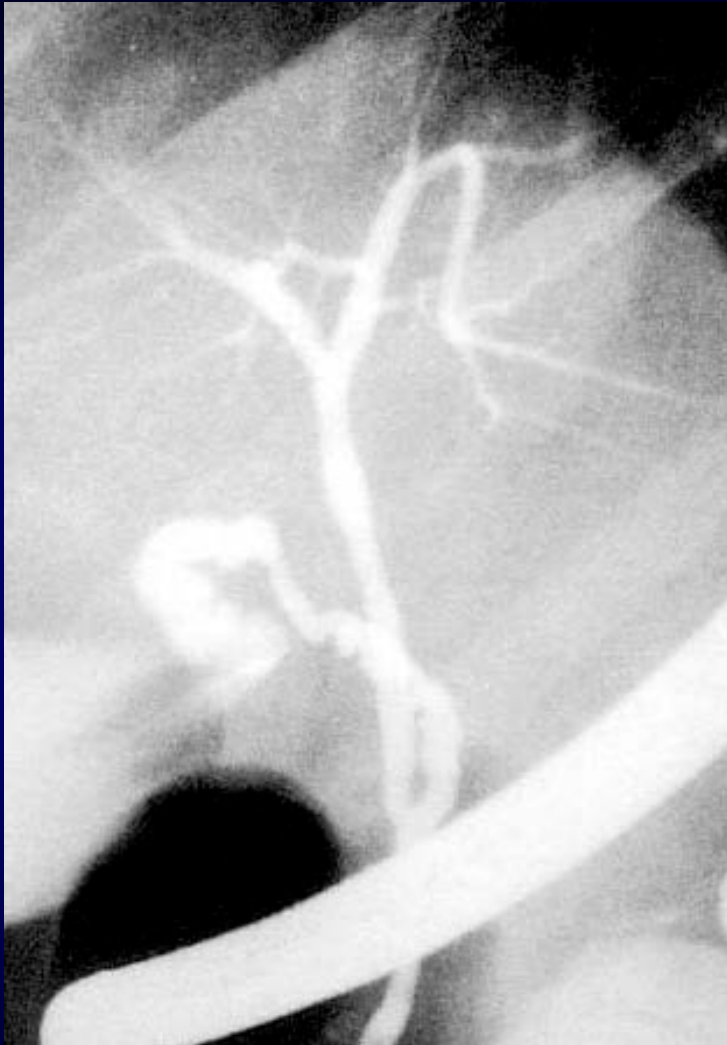- Infection of the bile ducts due to CBD obstruction 2ndary to stones, strictures
- History suggestive of biliary colic or jaundice
- Frequent/recurrent attacks of severe RUQ pain- duration of several hours
- severe colic - chills/fever
- **Charcot's Triad** - classic picture of cholangitis seen in 70% of pts:
 - ✓ Pain
 - ✓ Fever & Chills
 - ✓ Jaundice
- May lead to life-threatening sepsis and septic shock (**Raynaud's pentad**)

- The most direct and accurate way to determine the cause, location, and extent of obstruction:

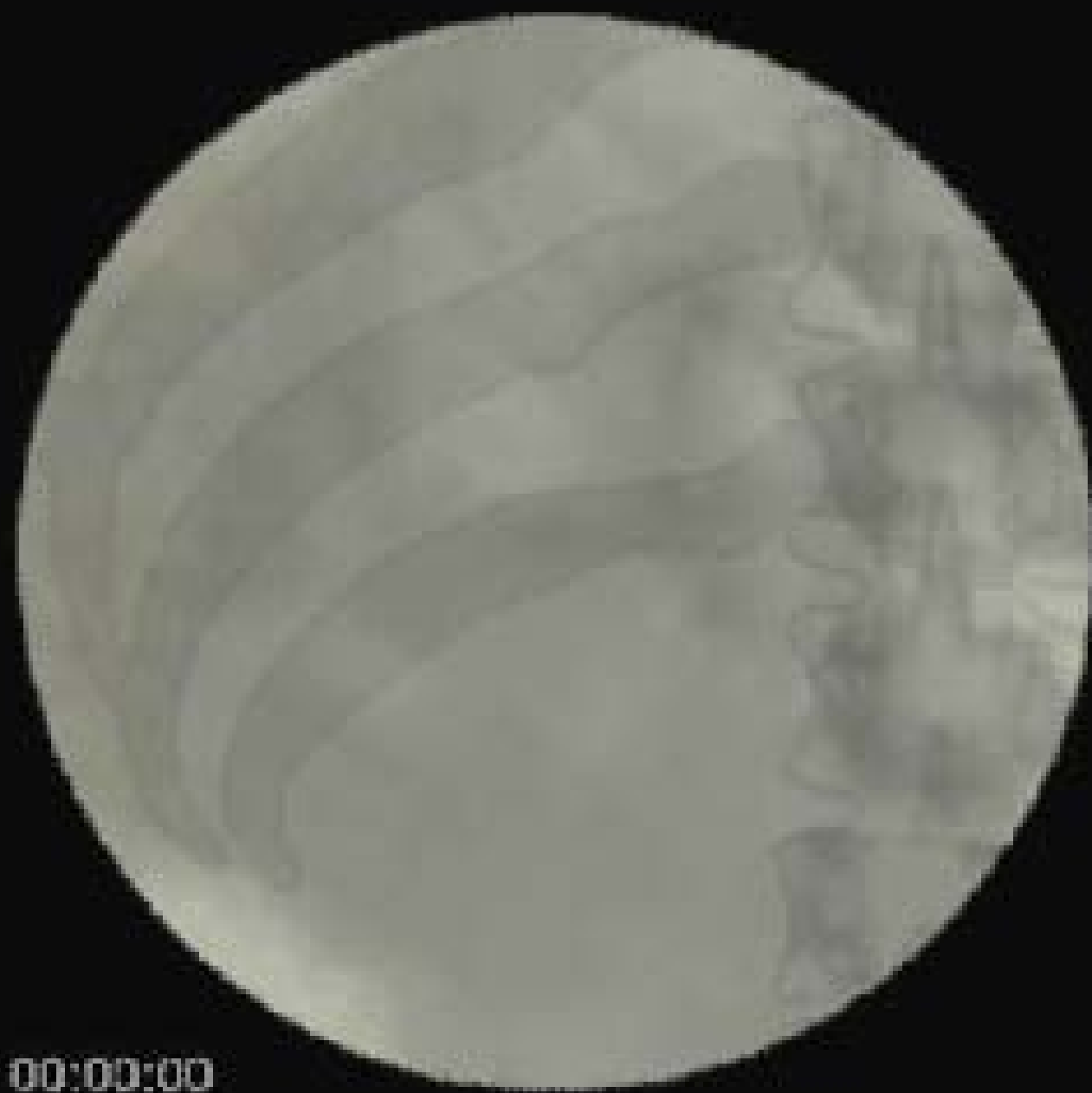- **ERCP**
- **percutaneous transhepatic cholangiography**

ERCP

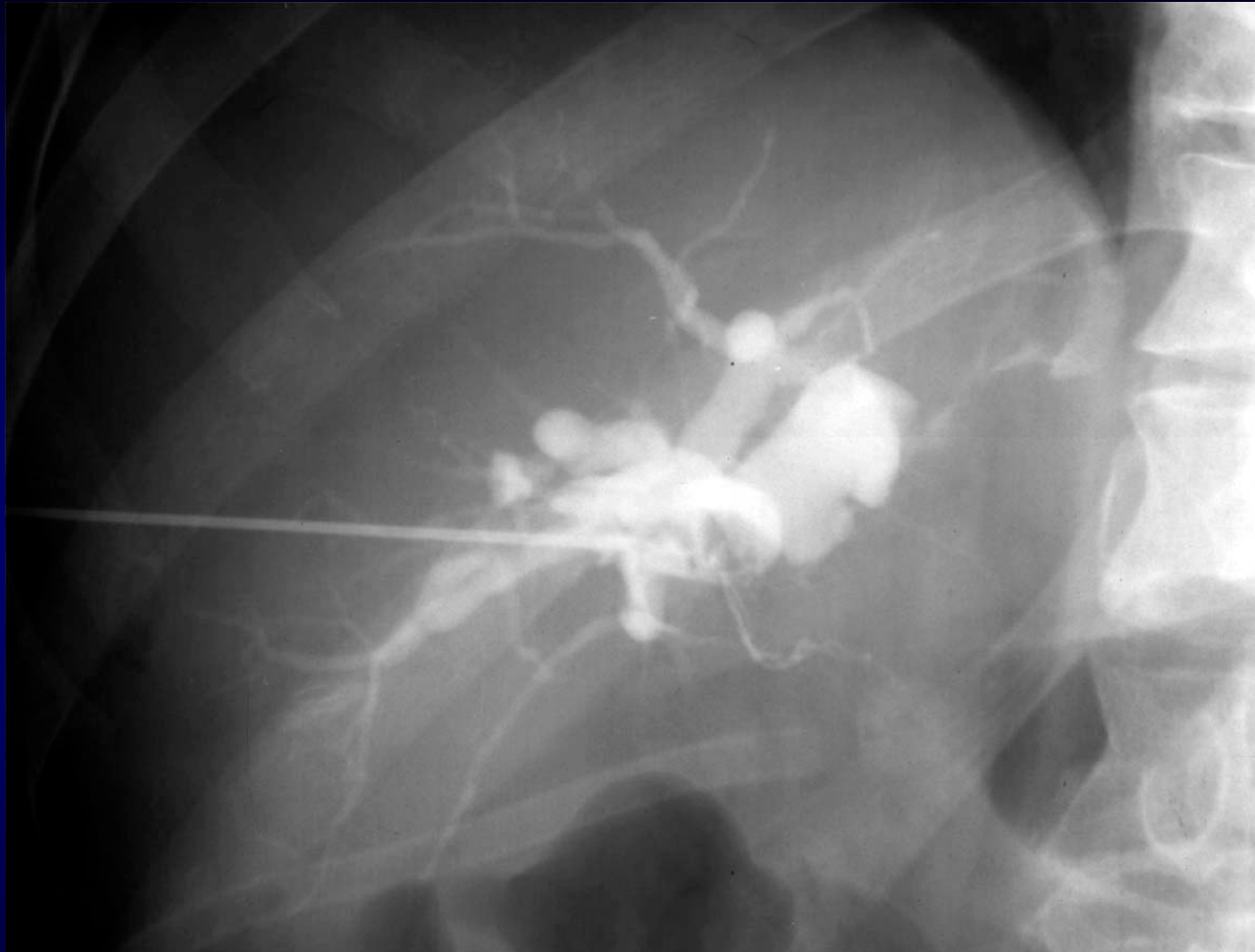- **Primary diagnostic and therapeutic modality**
- **Sphincterotomy and stone extraction**
- **Placement of stent if stone extraction unsuccessful**
- **Mortality rate 1.5%**



**ENDOSCOPIC RETROGRADE
CHOLANGIOPANCREATOGRAPHY (ERCP)**



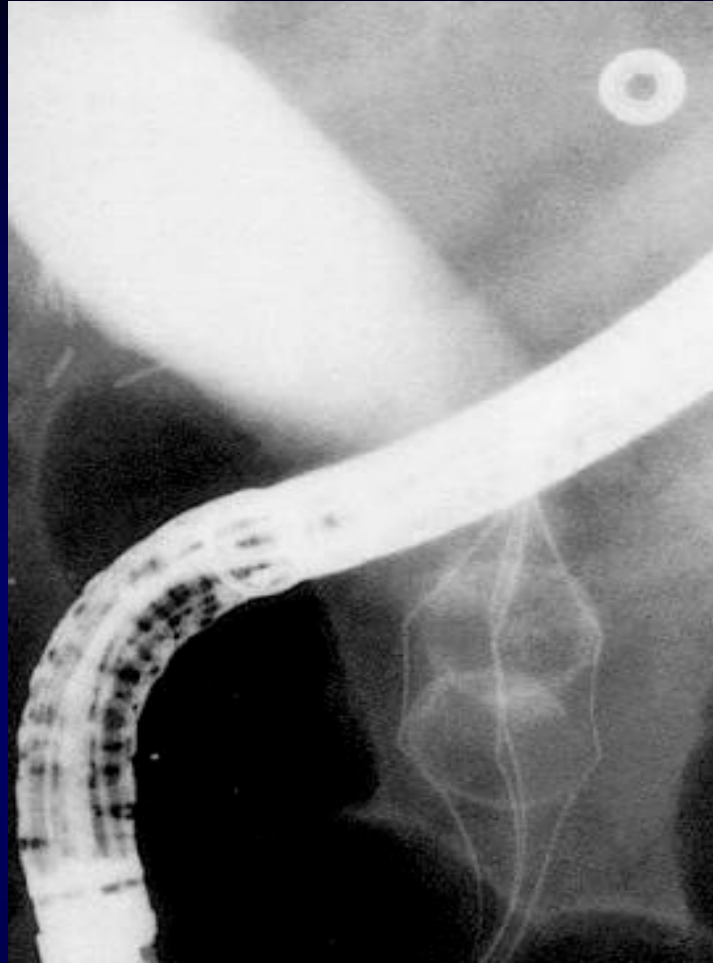
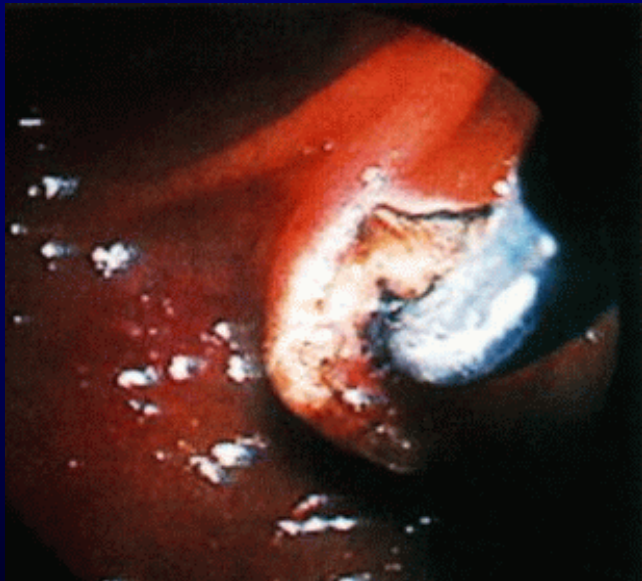
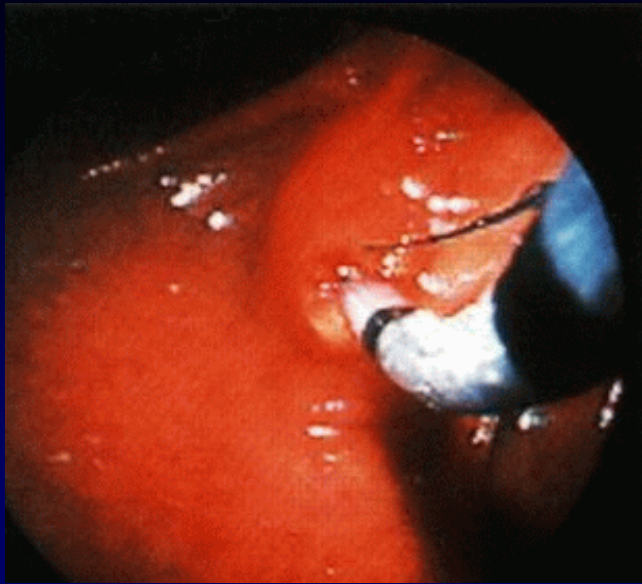
00:00:00



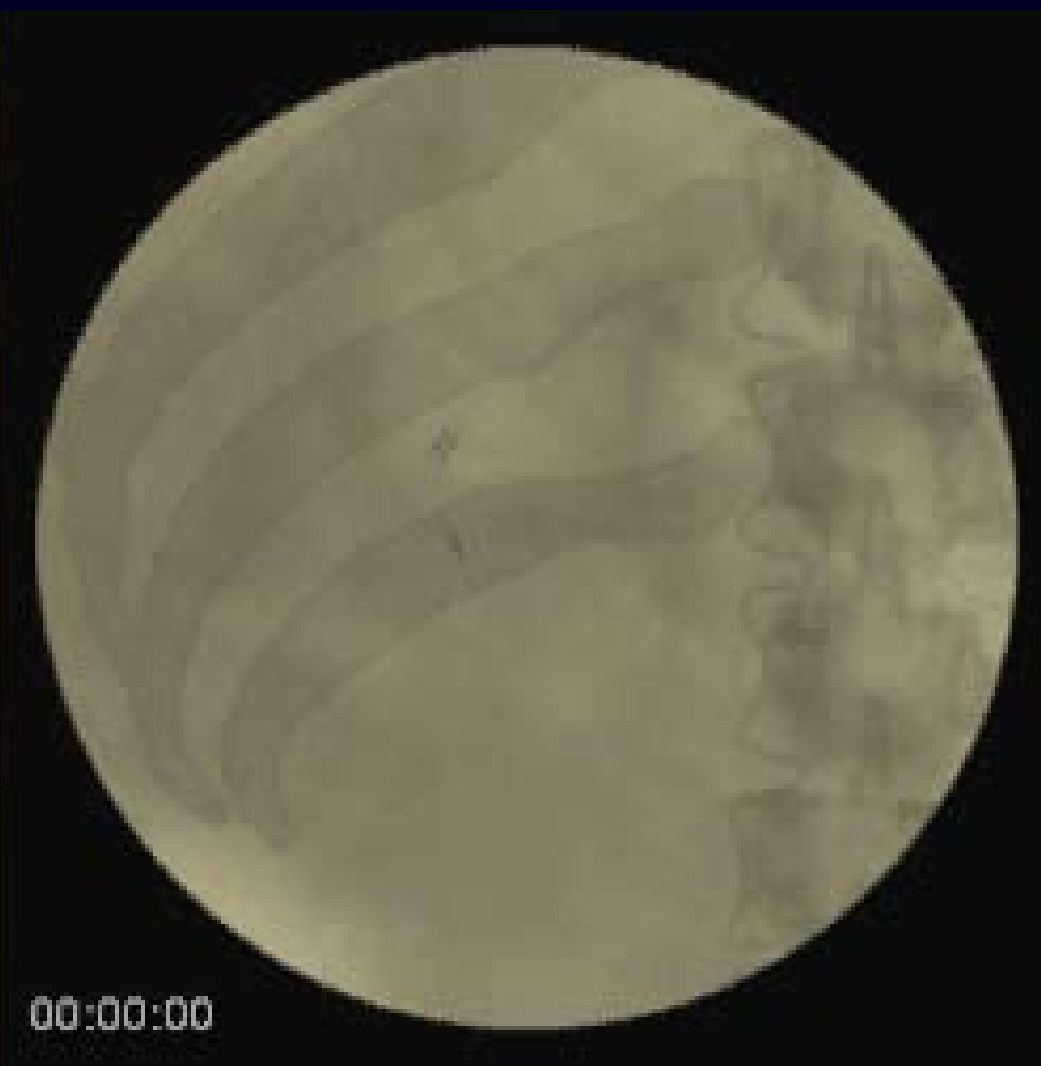
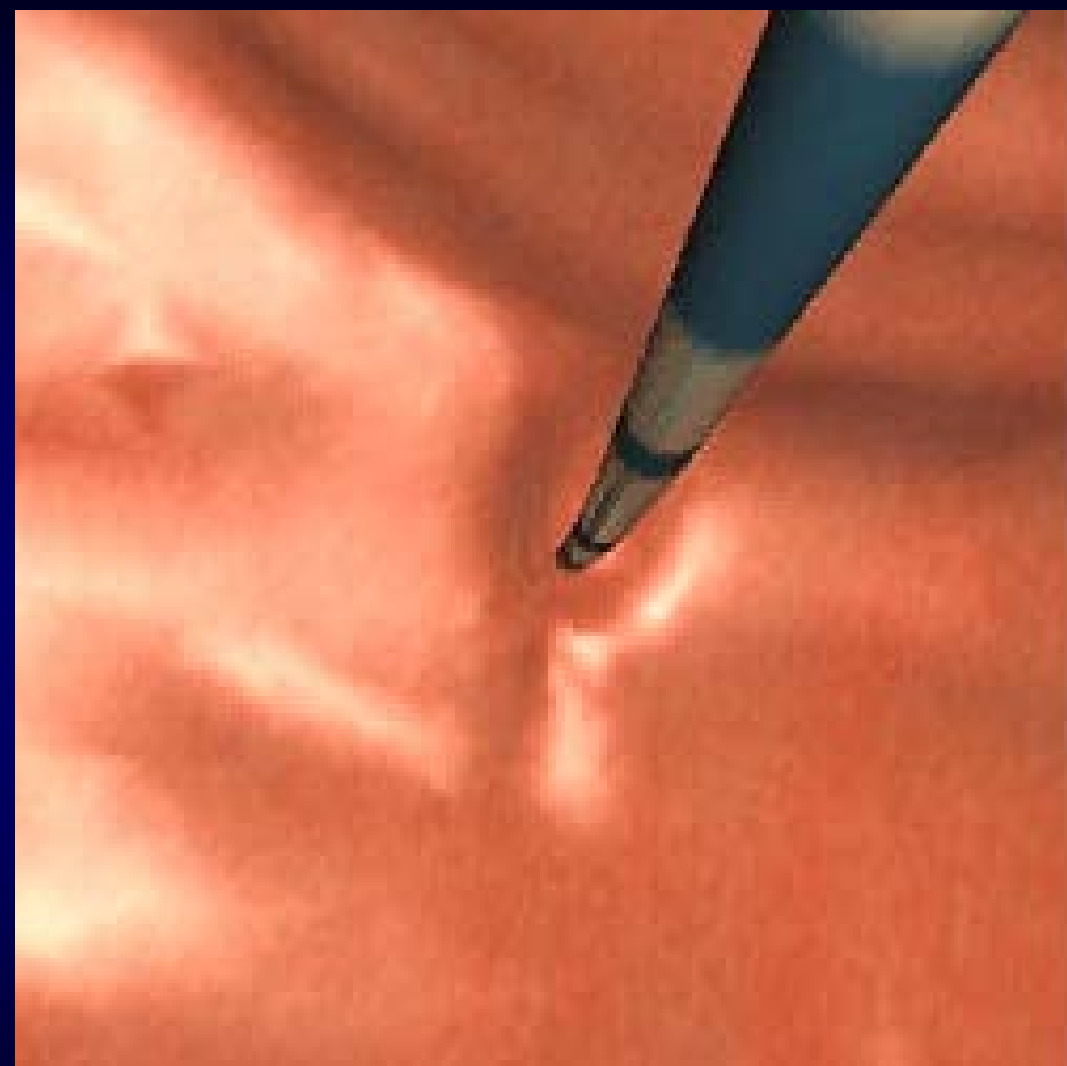
PERCUTANEOUS TRANSHEPATIC CHOLANGIOGRAPHY

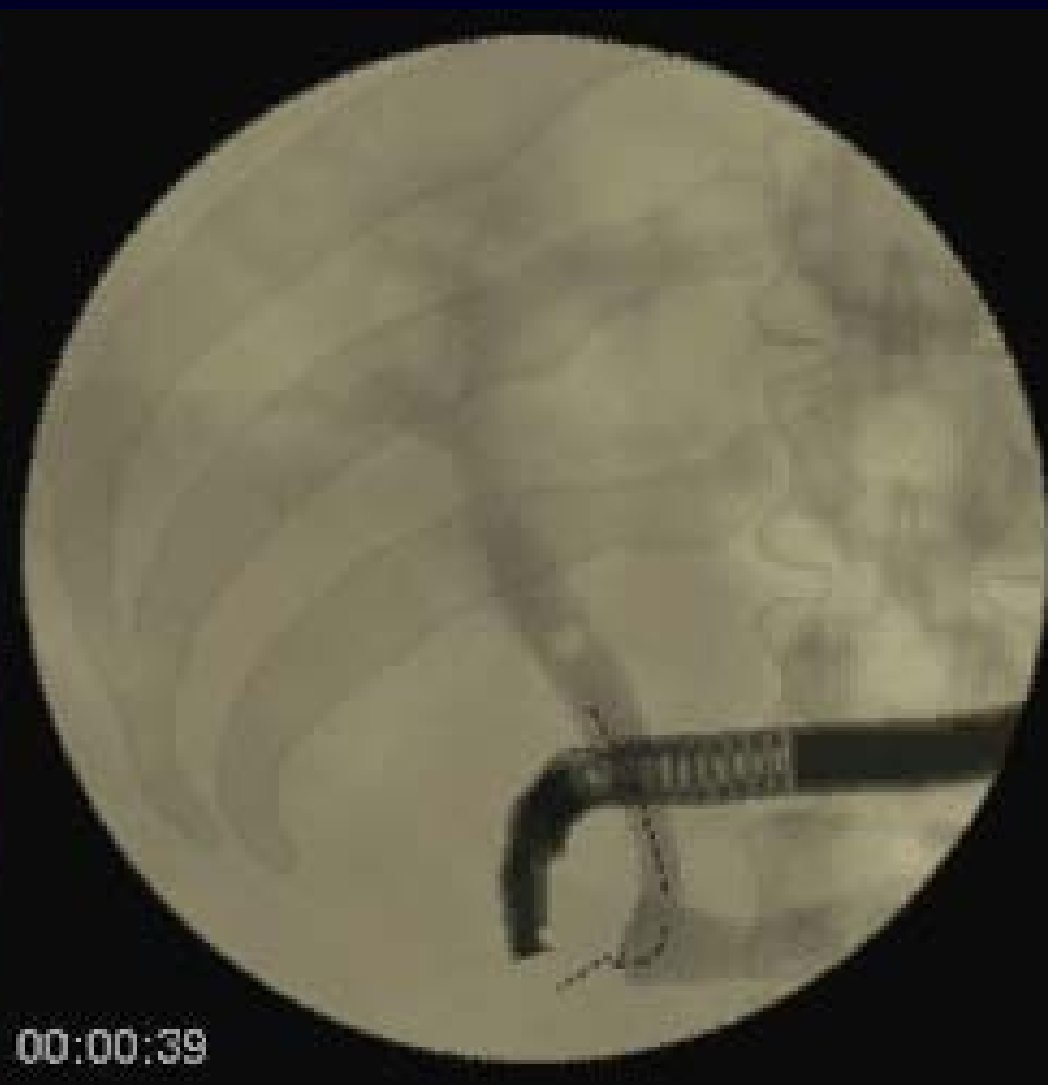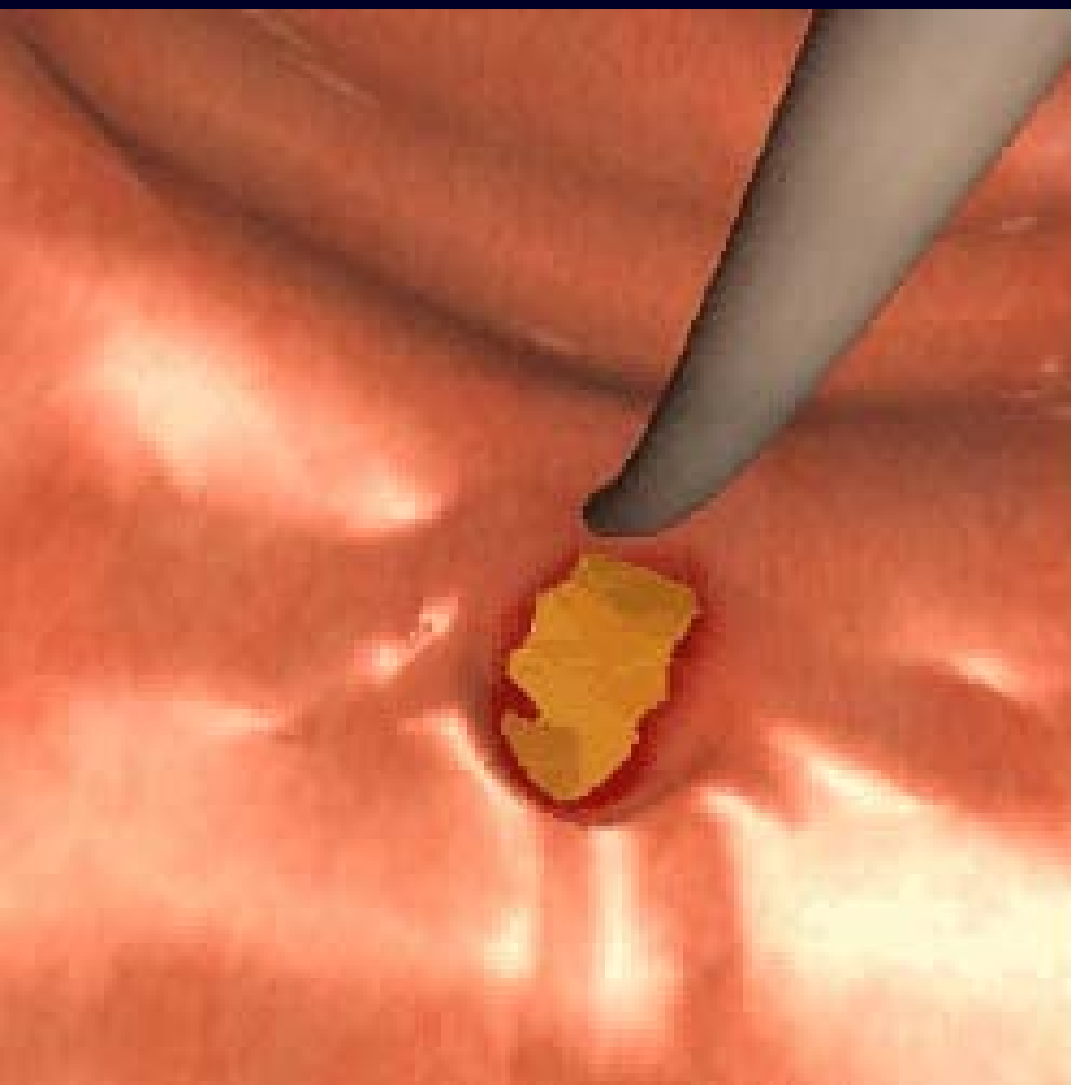
Treatment

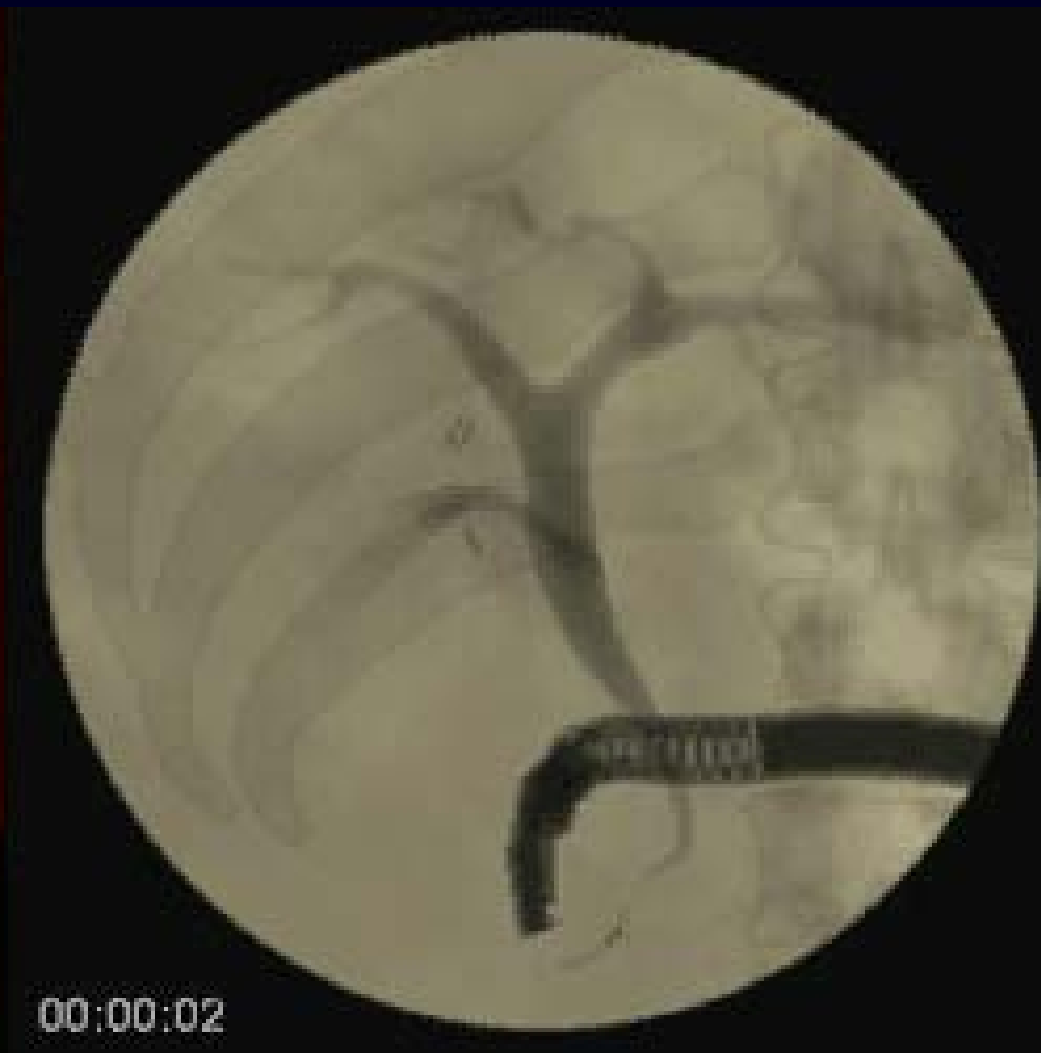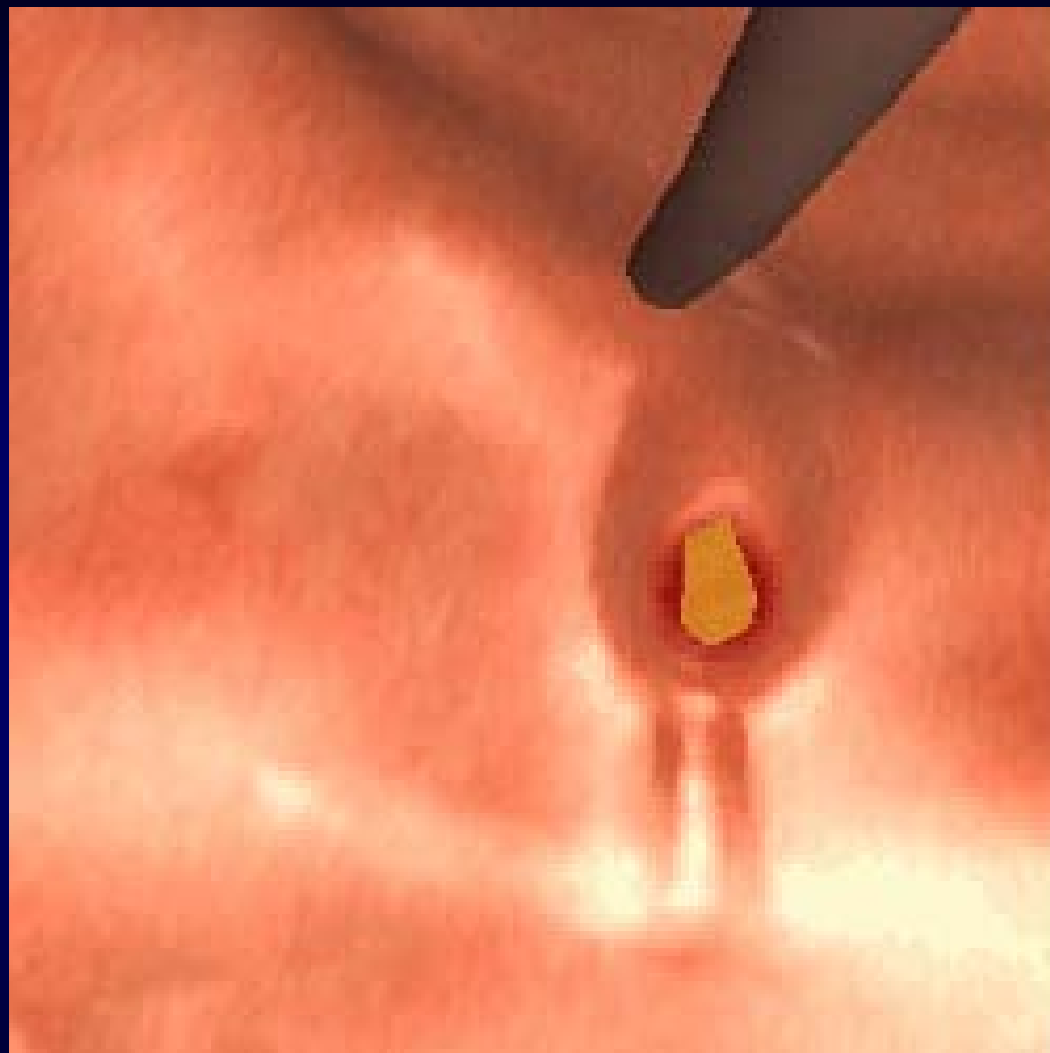- **Common duct stone in patient with cholelithiasis and cholecystitis is usually treated with endoscopic papillotomy and stone extraction - followed by laparoscopic cholecystectomy**
- **Ciprofloxacin, 250mg IV q 12 hours effective tx for cholangitis**
- **alternative tx - mezlocillin, 3g IV q 4 hours with either metronidazole or gentamicin or both**
- **Aminoglycosides should not be used for more than several days due to increased risk of aminoglycoside nephrotoxicity in cholestasis**



**ENDOSCOPIC SPHINCTEROTOMY AND DORMIA
BASKET EXTRACTION OF COMMON BILE DUCT
STONES**







Open CBD Exploration

Indications

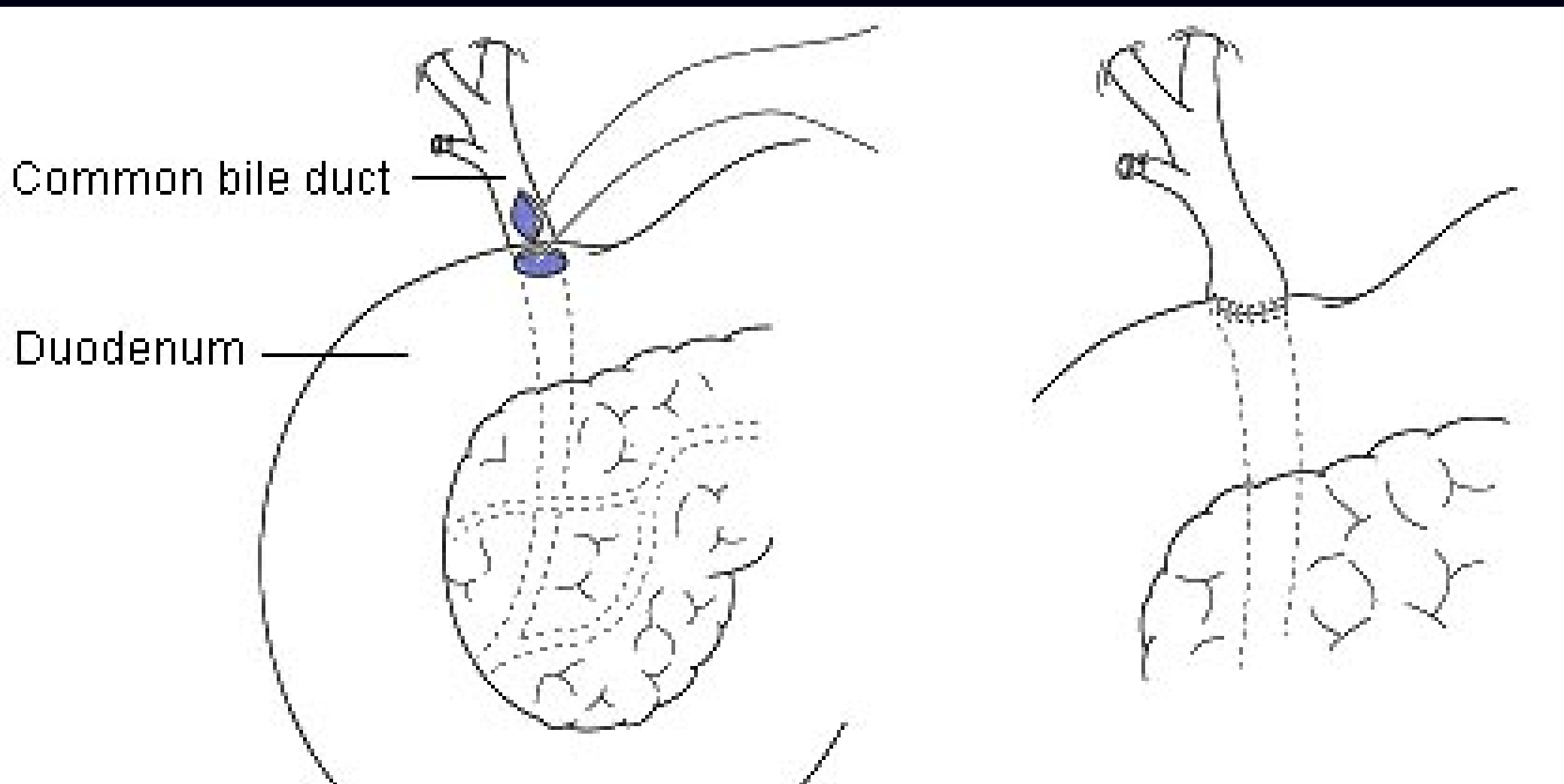
- Presence of multiple stones (more than 5)
Stones > 1 cm
- Multiple intra hepatic stones
- Distal bile duct strictures
- Failure of ERCP
- Recurrence of CBD stones after sphincterotomy

Perioperative management of obstructive jaundice

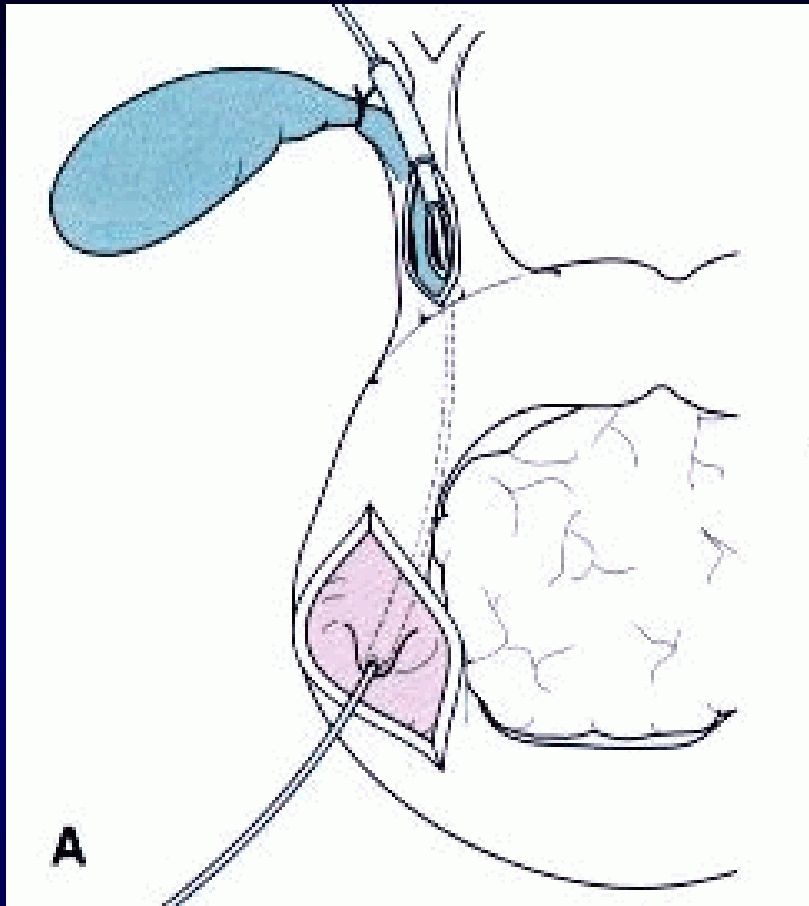
- Preoperative biliary decompression improves postoperative morbidity
- Broad spectrum antibiotic prophylaxis
- Parenteral vitamin K +/- fresh frozen plasma
- IVI and catheter
- Pre operative fluid expansion
- Need careful post operative fluid balance to correct depleted ECF compartment
- Consider 250 ml 10% mannitol.

CBD Exploration – Surgical Options

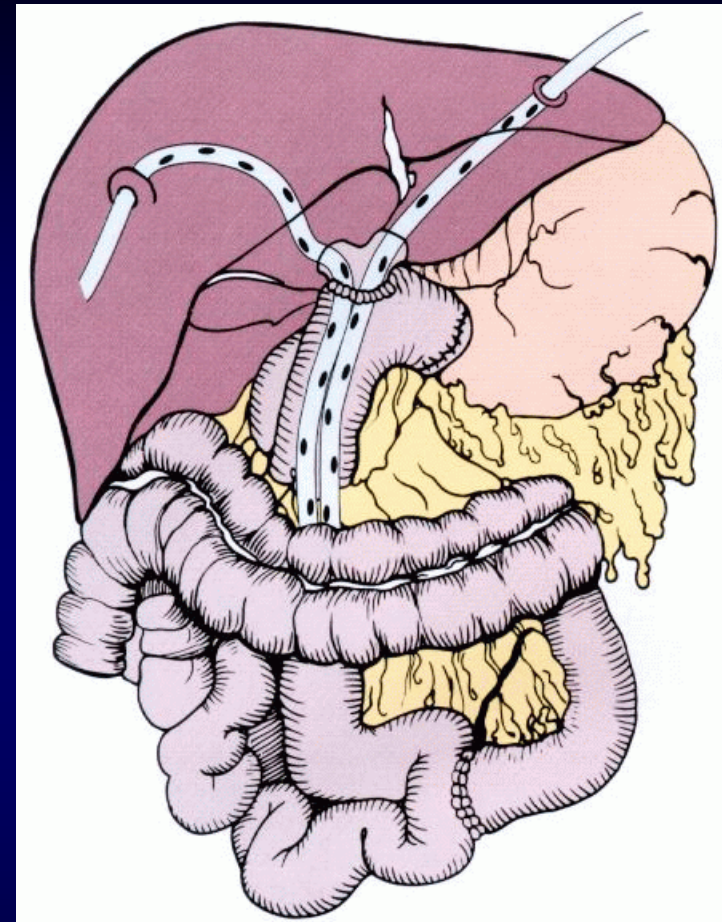
- **Common bile duct exploration with T-tube decompression**
- **Choledochoduodenostomy**
- **Transduodenal sphincterotomy and sphincterplasty**
- **Roux-en-Y Choledocho jejunostomy**



SIDE-TO SIDE CHOLEDOCHODUODENOSTOMY



**TRANSDUODENAL
SPHINCTEROPLASTY**



**ROUX-EN-Y
CHOLEDOCHOJEJUNOSTOMY**

Primary Sclerosing Cholangitis

- Rare disorder
- Characterized by diffuse inflammation of the biliary tract leading to fibrosis and strictures of the biliary system
- Most common - men aged 20-40
- Associated with histocompatible antigens HLA-B8 and -DR3 or -DR4 - suggestive of genetic etiologic role
- Sclerosing cholangitis may occur in AIDS patients from infections caused by CMV, cryptosporidium, or microsporium

- **Symptoms -**

- progressive obstructive jaundice frequently associated with:
 - malaise, pruritus, anorexia and indigestion
 - Early detection in presymptomatic phase may occur due to elevated alkaline phosphatase level
- Complications of chronic cholestasis such as osteoporosis and malabsorption of fat-soluble vitamins may occur
- Diagnosis generally made by:
 - ERCP
 - magnetic resonance cholangiography

Primary Sclerosing Cholangitis

- Tx w/corticosteroids and broad spectrum antimicrobial agents yields inconsistent and unpredictable results
- Episodes of acute bacterial cholangitis may be treated with ciprofloxacin
- high dose ursodeoxycholic acid (20mg/kg/d) may reduce cholangiographic progression and liver fibrosis

Primary Sclerosing Cholangitis

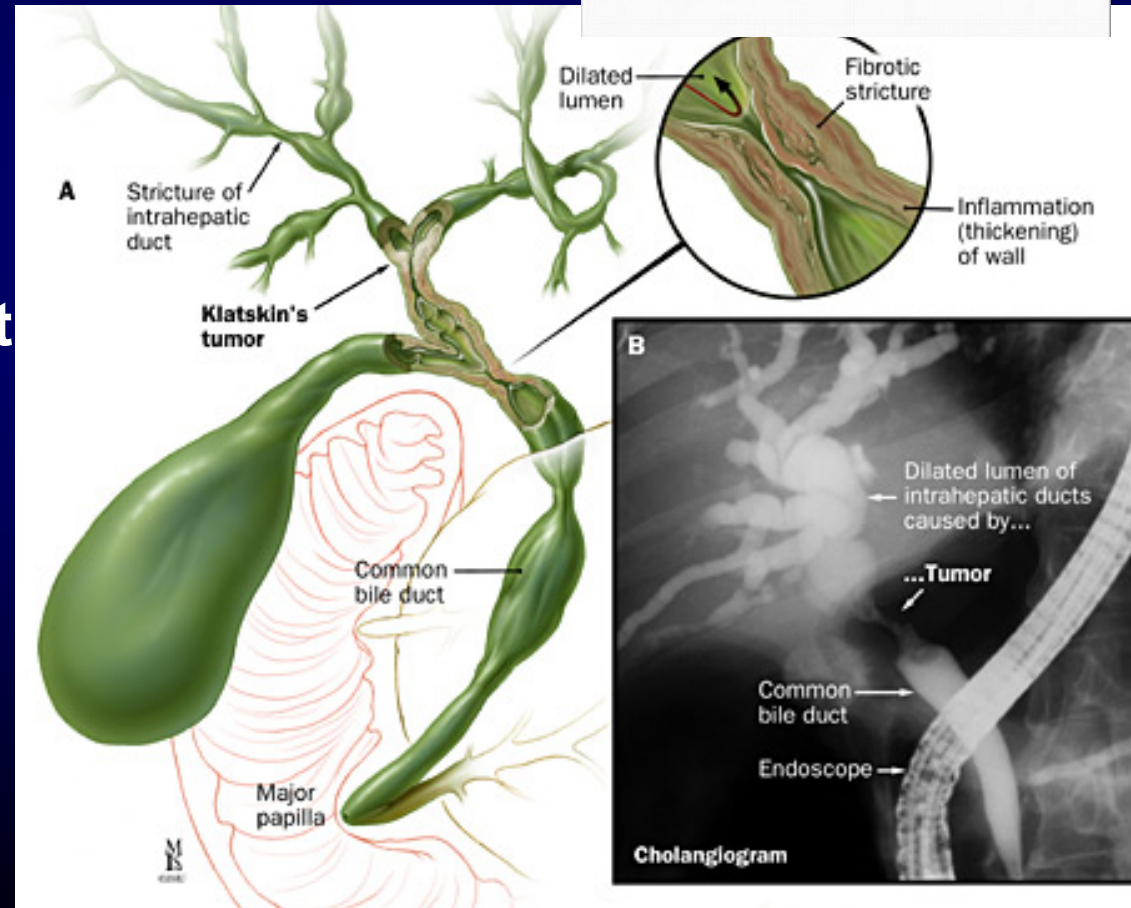
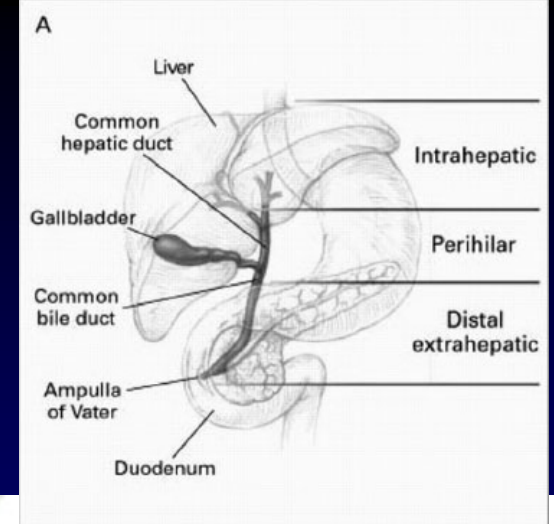
- In patients with ulcerative colitis, primary sclerosing cholangitis is an independent risk factor for development of colorectal dysplasia and cancer- routine colonoscopic surveillance is advised
- For patients with cirrhosis and clinical decompensation, liver transplantation is the procedure of choice

Primary Sclerosing Cholangitis

- **Survival of patients with primary sclerosing cholangitis averages 10 years once symptoms appear**
- **Adverse prognostic factors:**
 - increased age
 - increased serum bilirubin
 - increased aspartate aminotransferase levels
 - low albumin levels
 - history of variceal bleeding

KLATSKIN TUMOR

- Carcinoma of the bile ducts (cholangiocarcinoma) accounts for 3% of all US cancer deaths
- Effects both sexes equally
- More prevalent 50-70 age group
- 2/3 **Klatskin** tumors - arise at the confluence of hepatic ducts
- 1/4 in the distal extrahepatic bile duct
- remainder are intrahepatic



- **Signs/symptoms:**
 - Progressive jaundice
 - pain RUQ w/ pain radiating to back present in gallbladder CA but **occurs later in course of bile duct carcinoma**
 - anorexia, weight loss
 - fever, chills (due to cholangitis)
- A palpable gallbladder w/obstructive jaundice usually is said to signify malignant disease (**Courvoisier's** Law): however this has only proved to be accurate 50% of the time
- Hepatomegaly, liver tenderness
- Pruritus

Lab tests

- **Conjugated hyperbilirubinemia**
- **elevated alkaline phosphatase**
- **elevated serum cholesterol**
- **AST may be slightly elevated**
- **CA19-9 (elevated level can help distinguish cholangiocarcinoma from benign biliary stricture)**

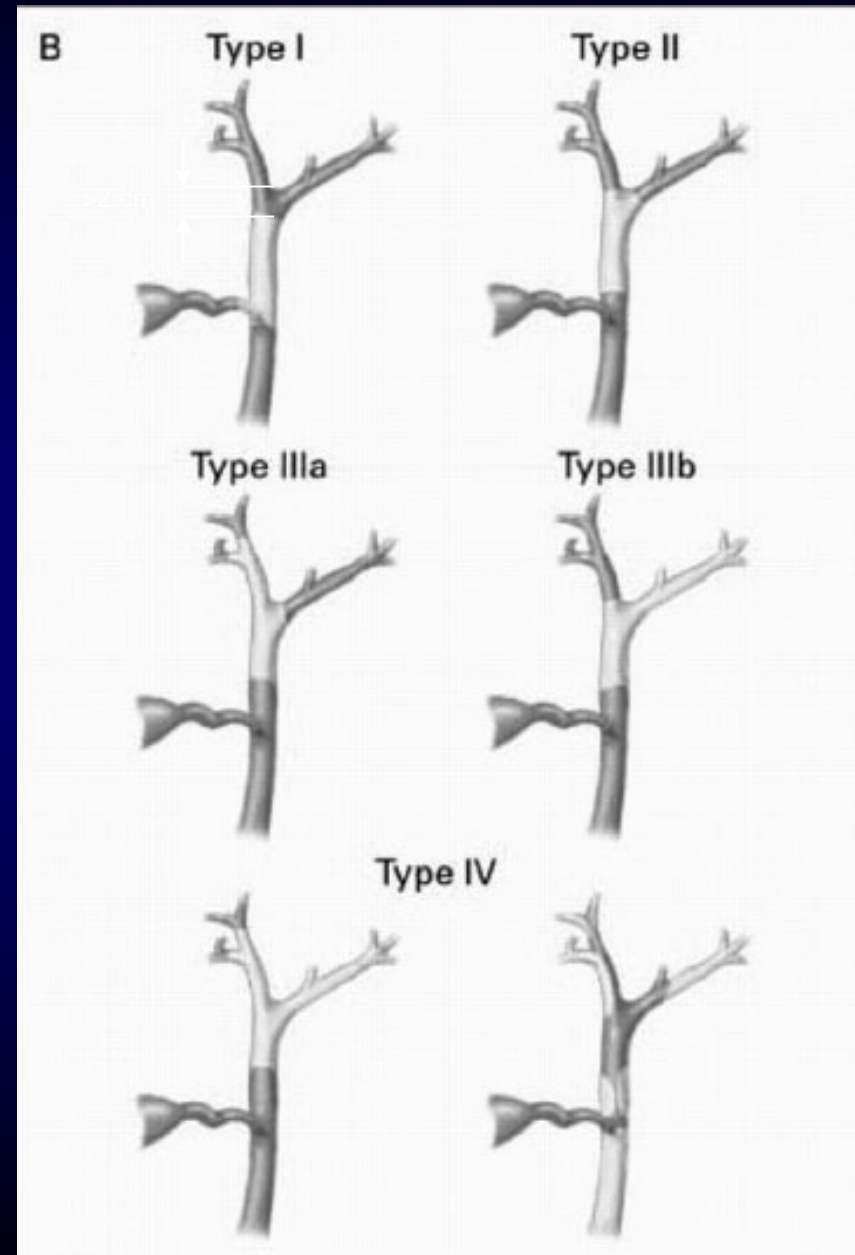
Bismuth Classification for Klatskin Tumor

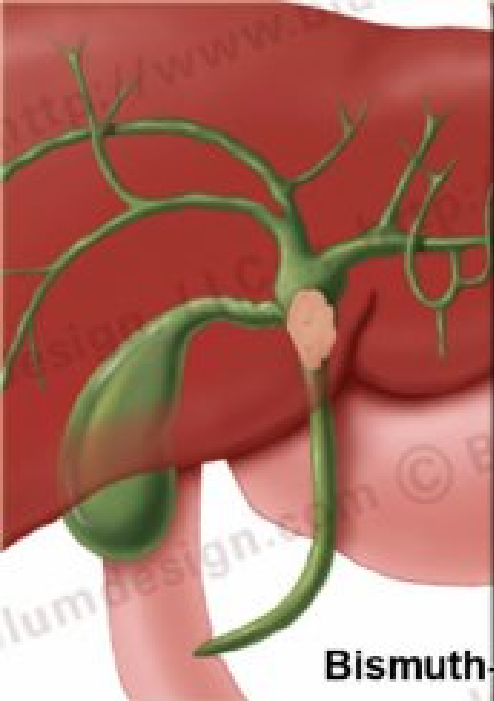Type I tumors are found below the confluence of the left and right hepatic ducts (>2 cm).

Type II tumors reach the confluence of the left and right hepatic ducts.

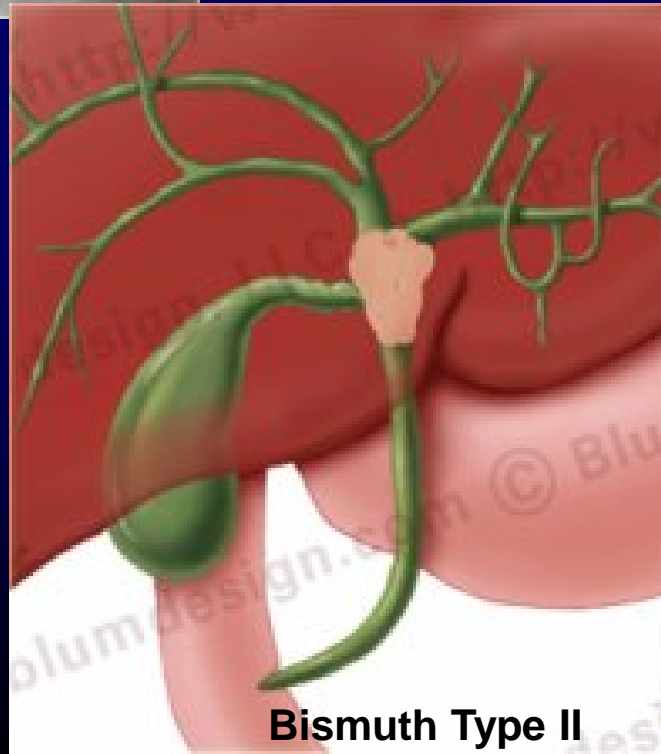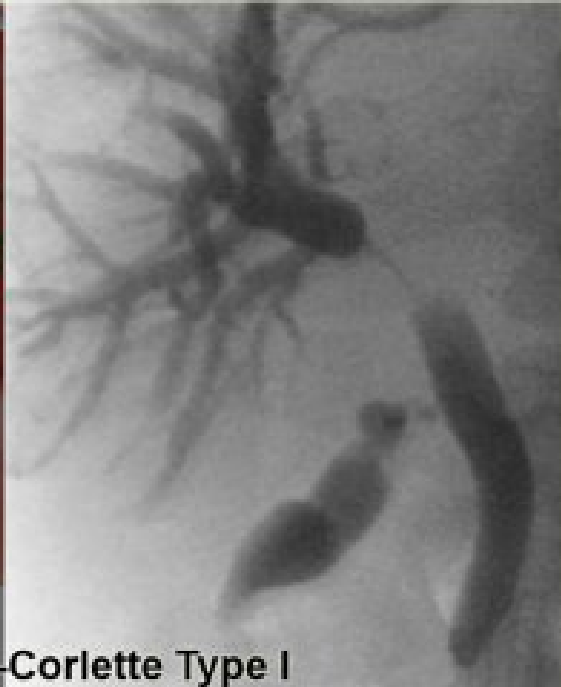
Type IIIa and IIIb tumors occlude the common hepatic duct and either the right or the left hepatic duct, respectively.

Type IV tumors are multicentric or they involve the confluence and both the right and left hepatic ducts.

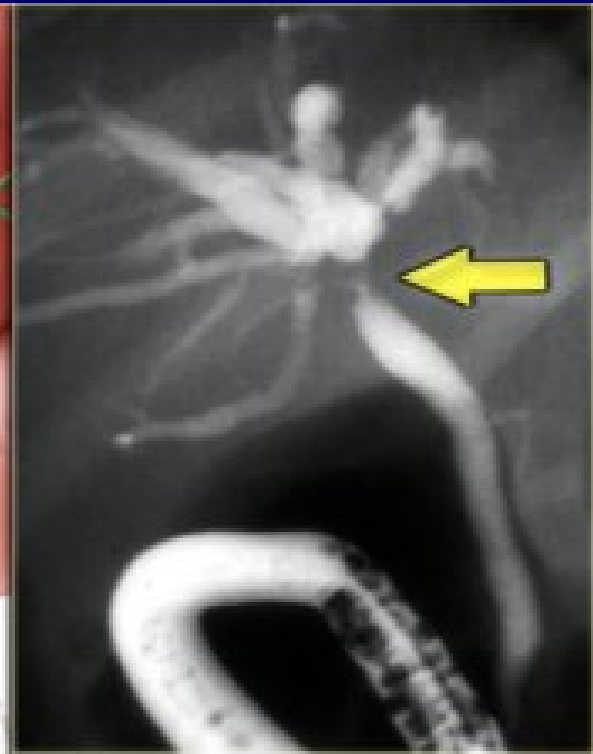


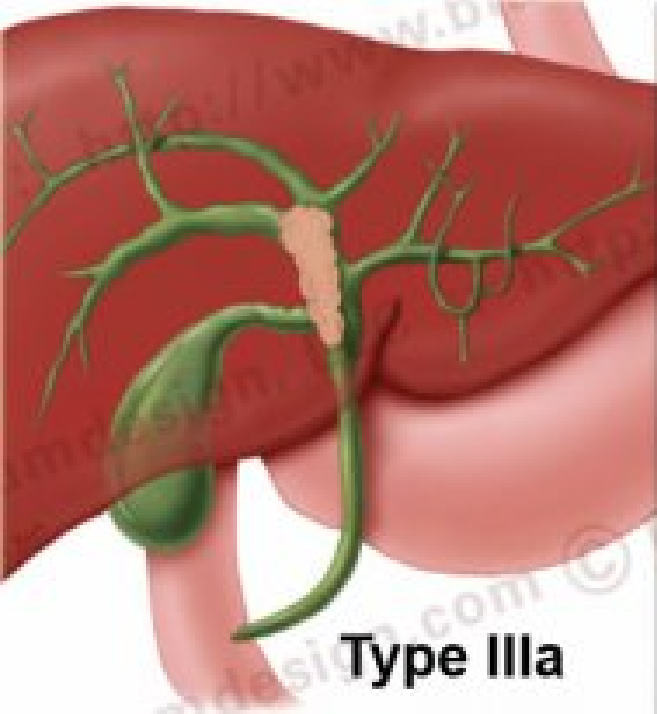


Bismuth-Corlette Type I

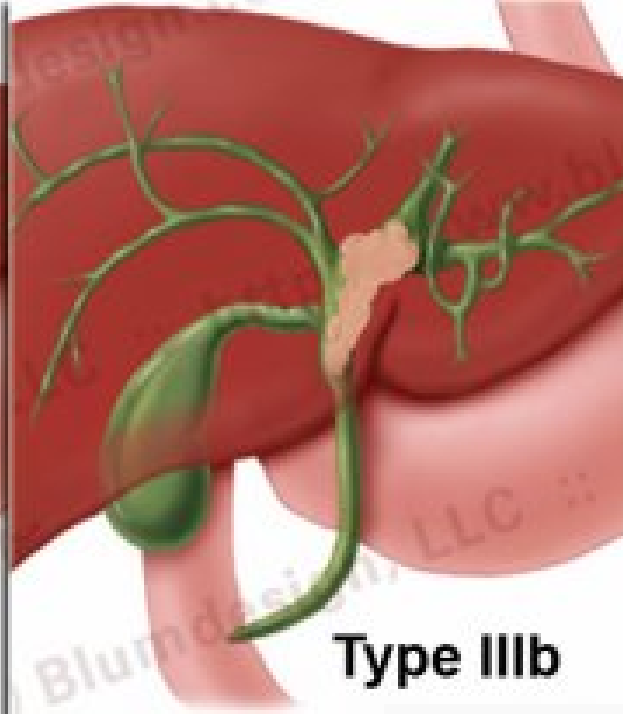


Bismuth Type II

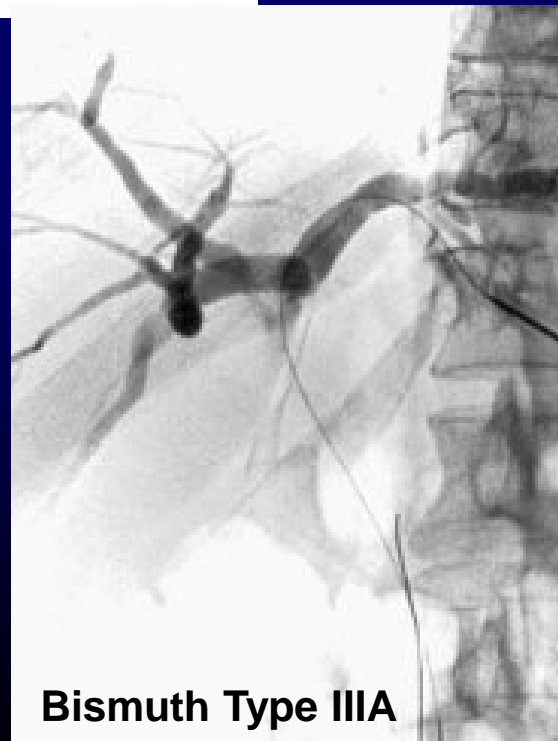



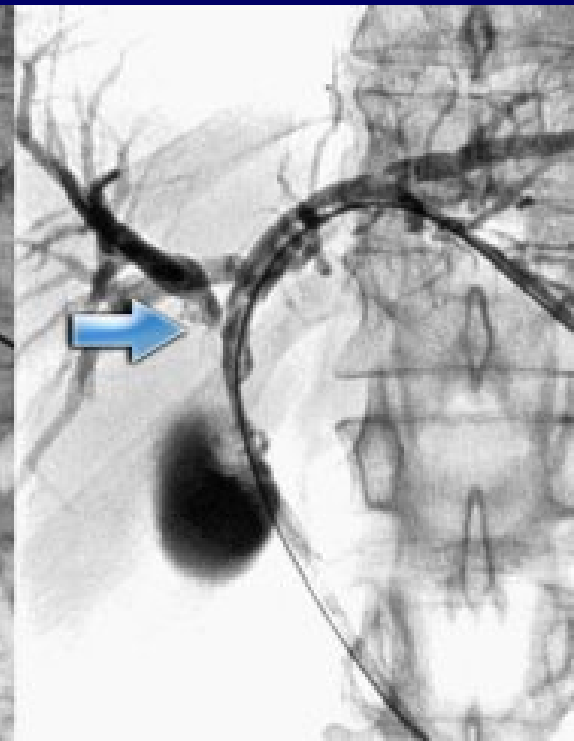Type IIIa

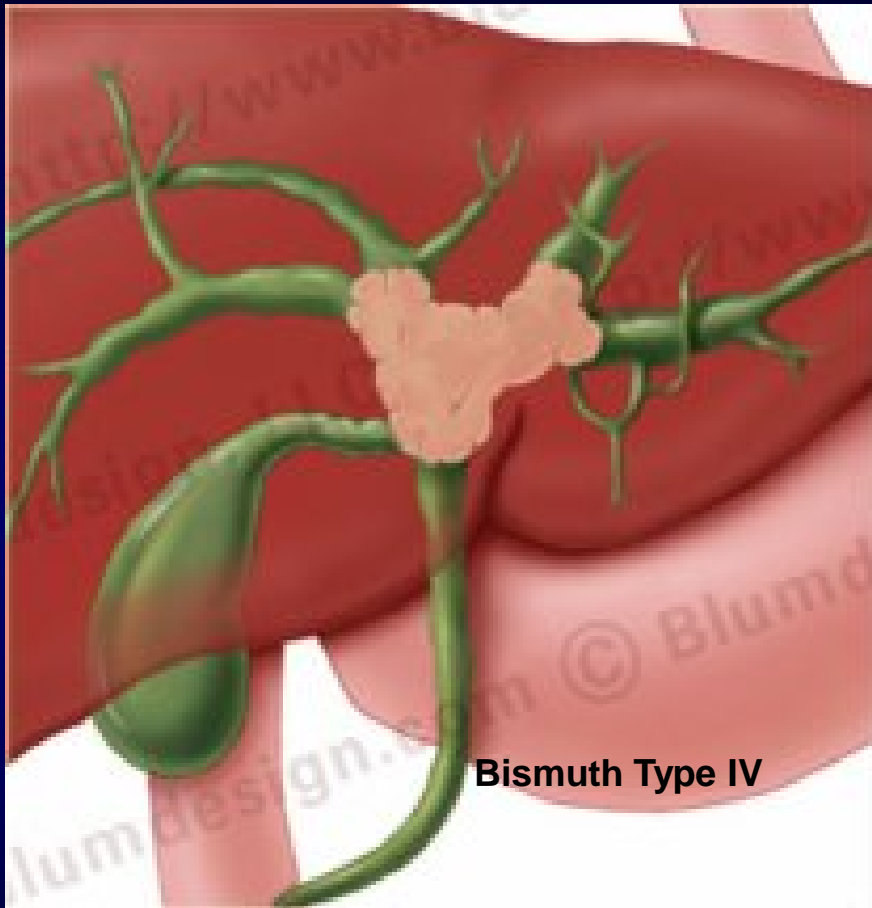


Type IIIb

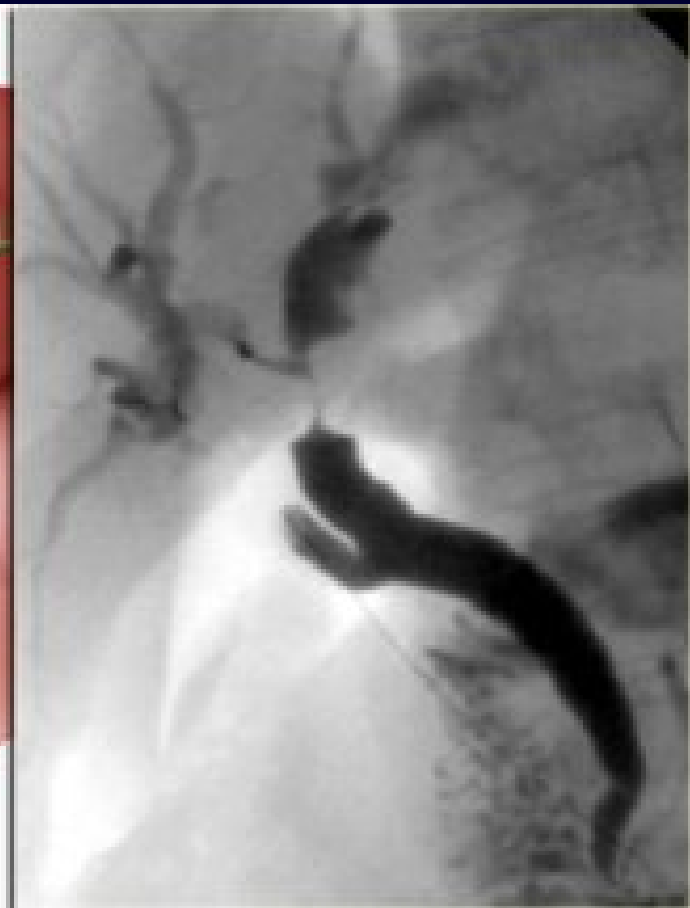

Bismuth Type IIIA





Bismuth Type IV



Periampullary Carcinoma and The Whipple

Pathology

➤ **Adeno carcinoma accounts for 95%**

Arises from 4 different tissues of origin

- **Head of pancreas**
- **Distal Bile duct**
- **Ampullary of Vater**
- **Periampullary duodenum**

Pathology

- Determination of tissue origin from FNA, **endoscopic biopsy**.
- Also from **thin section CT scan, ERCP**
- Determination of **k-Ras** also helps (95% of pancreatic cancer).

Spread

- **Loco regional spread results from lymphatic invasion and direct tumor spread to adjacent soft tissue.**
- **Ampullary lesions spread to LN 33%, typically to a single LN in the posterior pancreatoduodenal group.**
- **Duodenal has intermediate spread.**
- **Pancreas metastasizes 88% to multiple sites.**

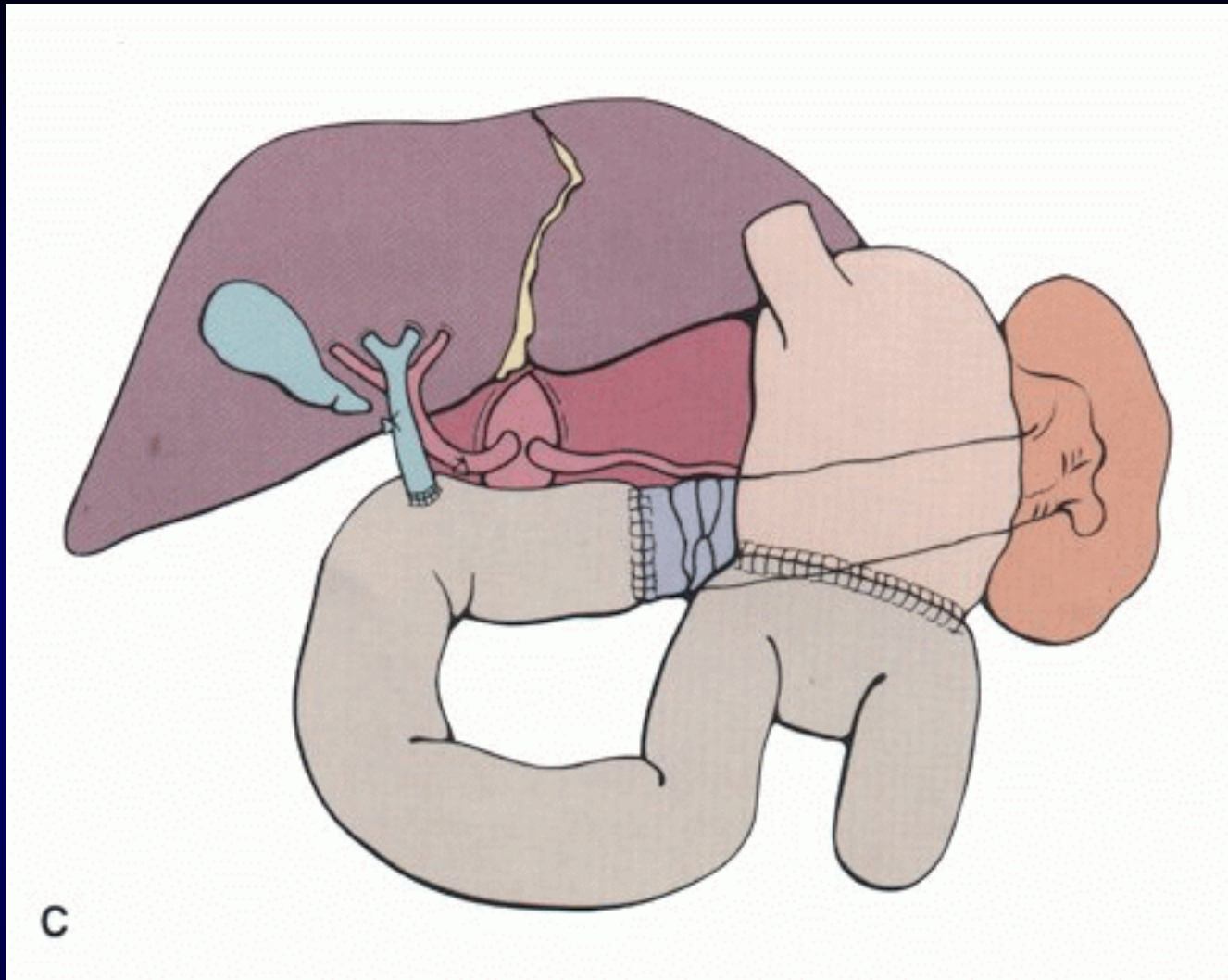
Treatment

- Standard **Whipple pancreaticoduodenectomy** thought to provide adequate tumor clearance in the case of non-pancreatic ampullary tumor, because tumor spread is localized.

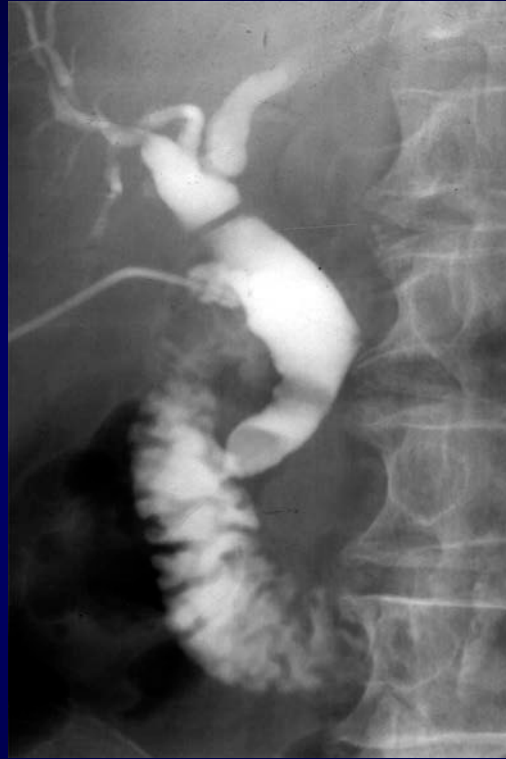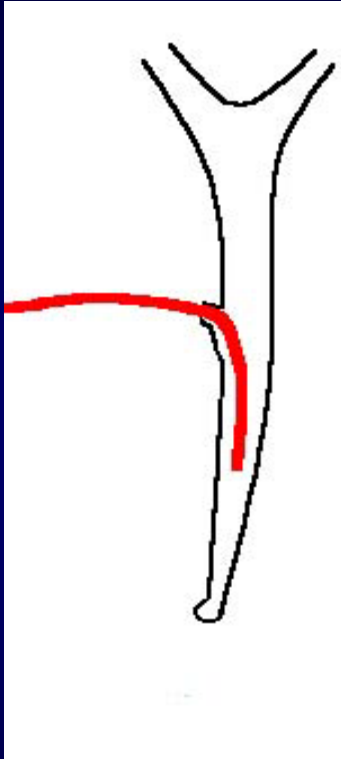
Whipple Procedure

Five basic techniques are used to resect pancreatic cancers

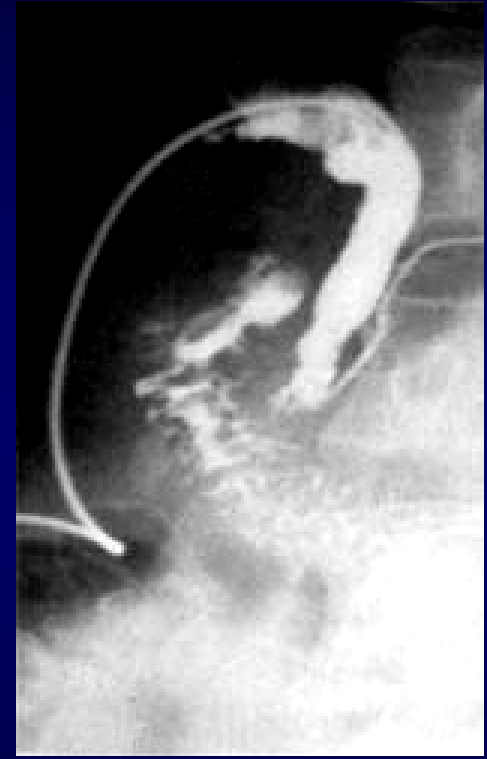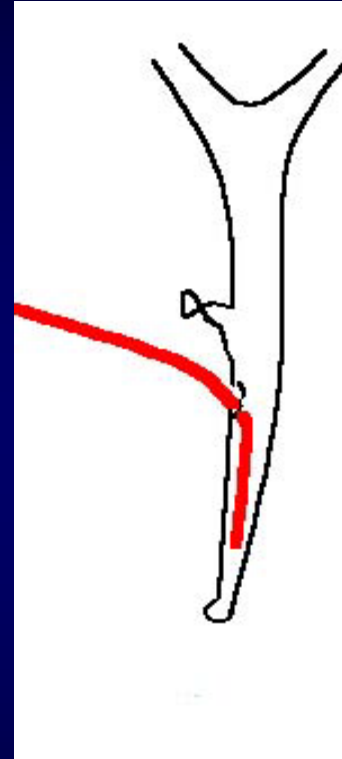
- **Standard pancreaticoduodenectomy**
- **Pylorus preserving pancreaticoduodenectomy**
- **Total pancreatectomy**
- **Regional pancreatectomy**
- **Extended resection (MD Anderson)**



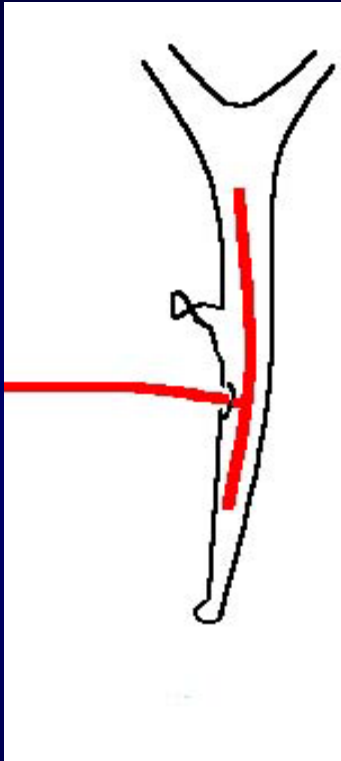
PANCREATODUODENECTOMY (WHIPPLE'S PROCEDURE)



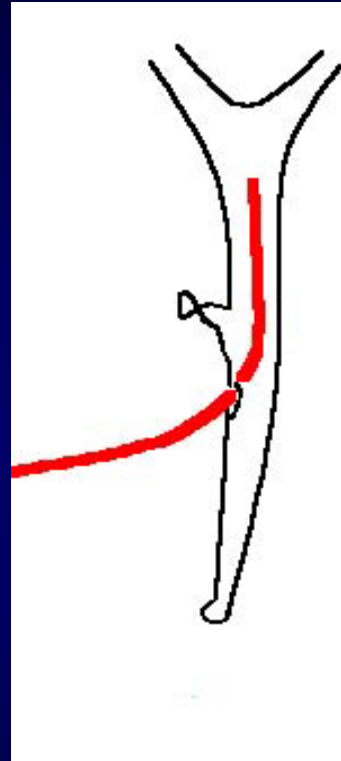
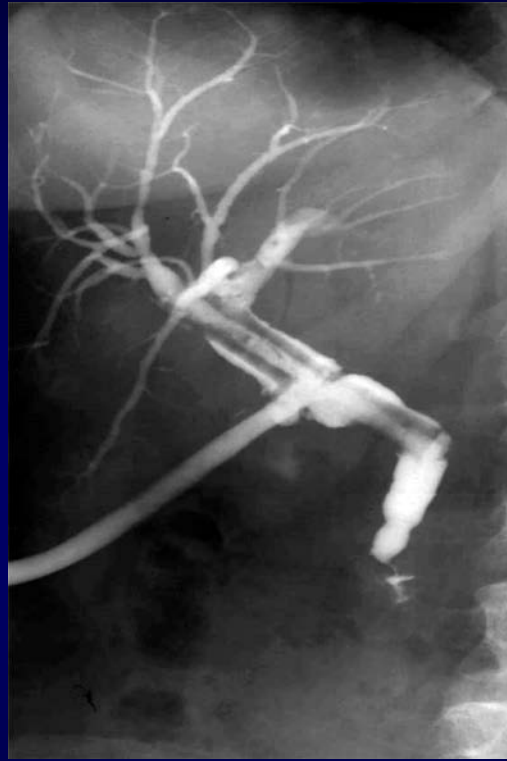HALSTEDT DRAIN



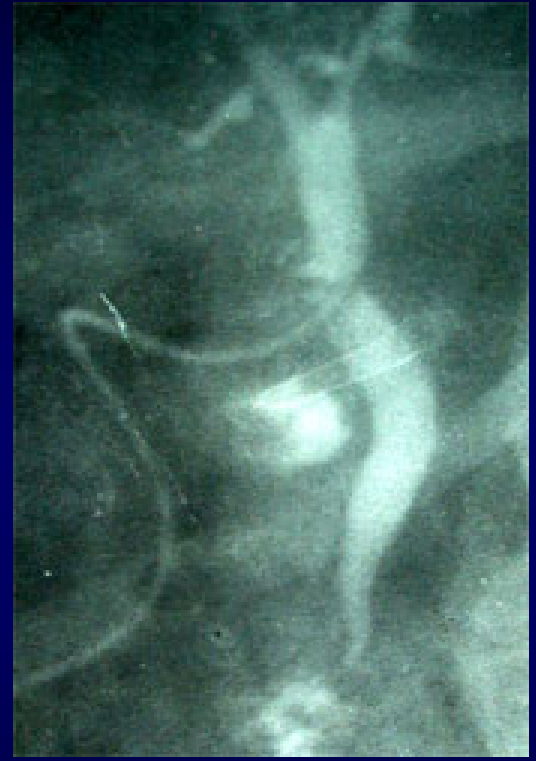LANE DRAIN

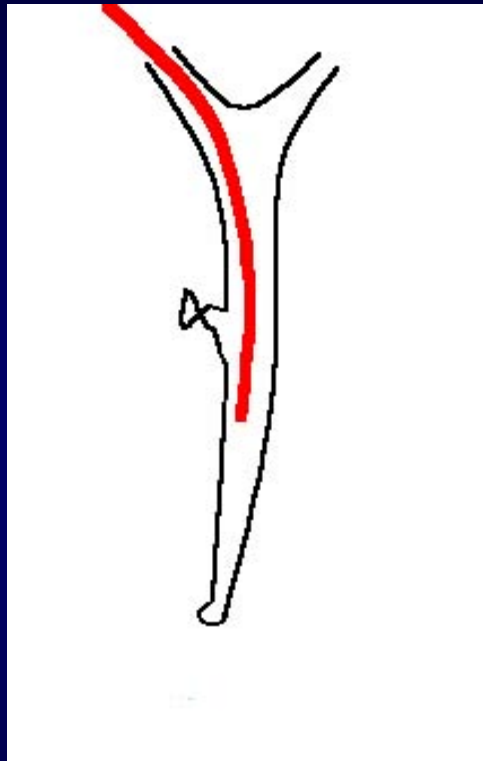


KEHR DRAIN

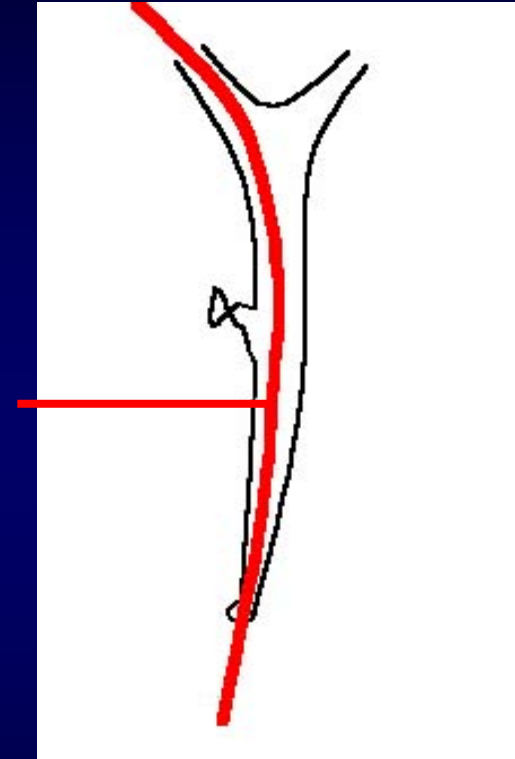
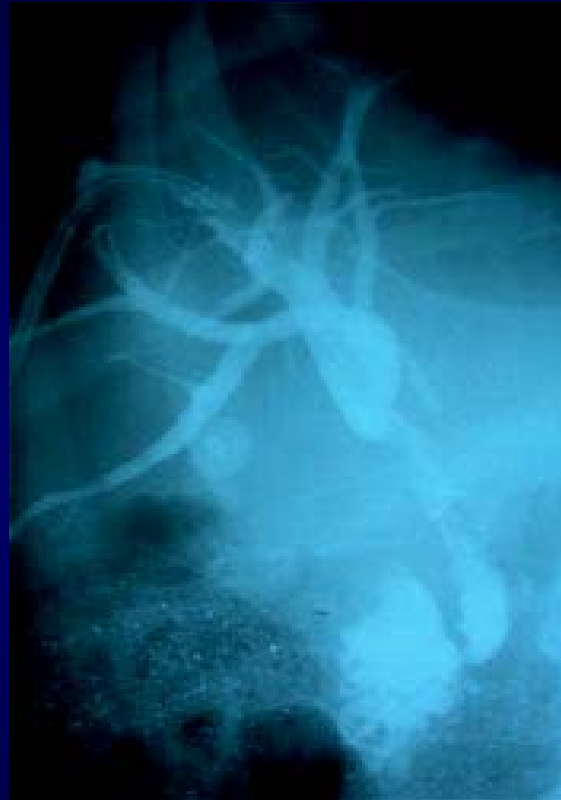

ROBSON-VISHNEVSKI DRAIN

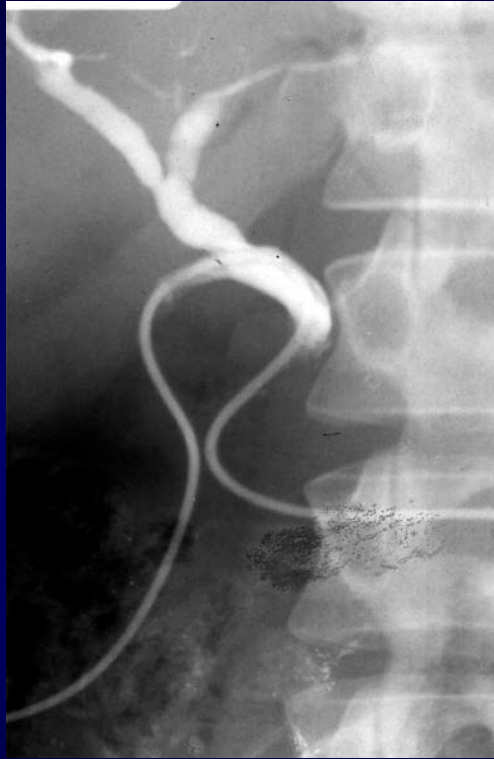
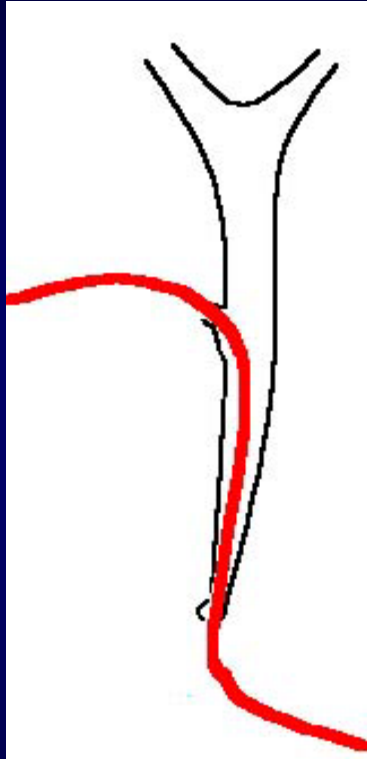




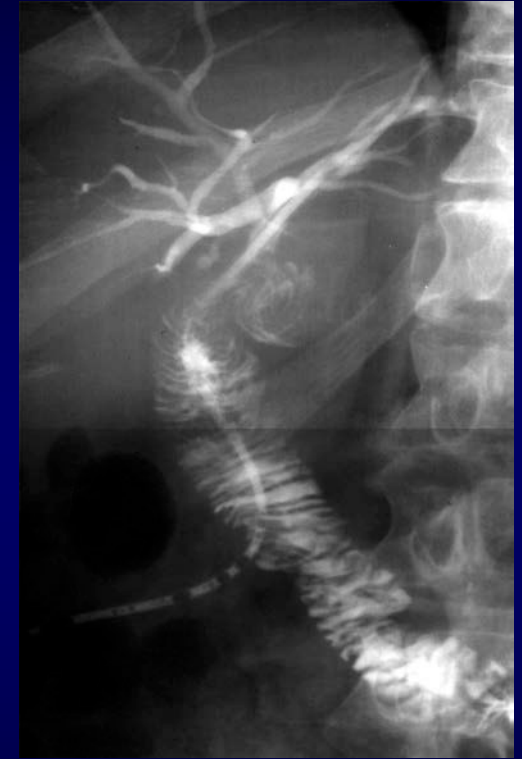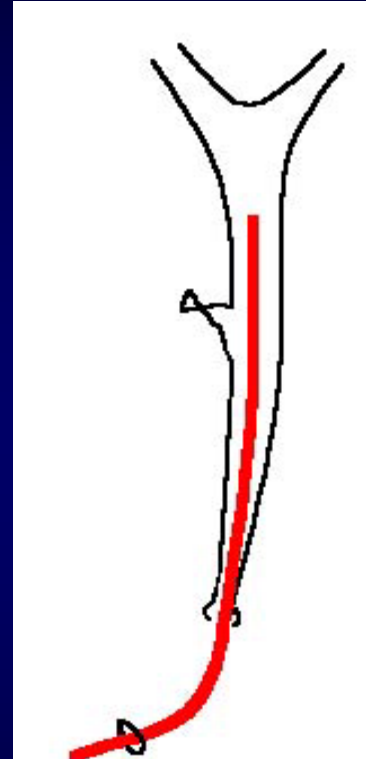
PRADERI-SMITH DRAIN



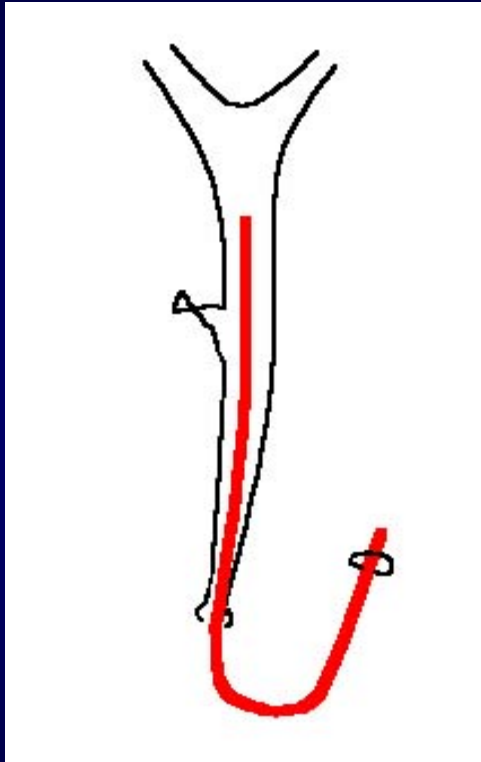
CATTELL-CHAMPAU DRAIN



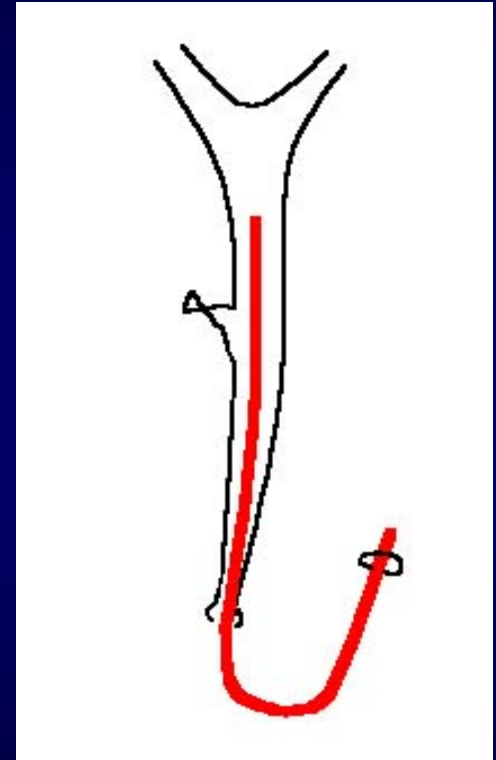
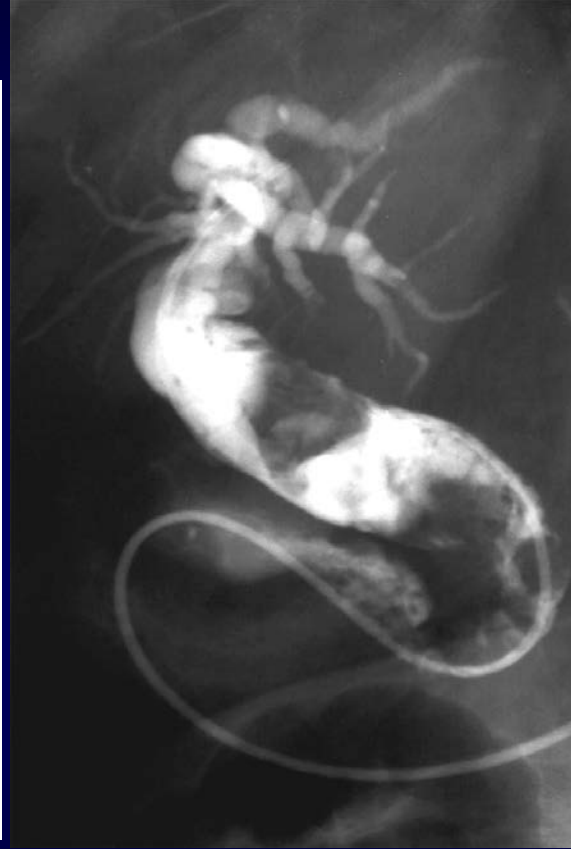DOGLIOTTI DRAIN



VOELKER DRAIN



CALMERS DRAIN



BAILLEYS DRAIN